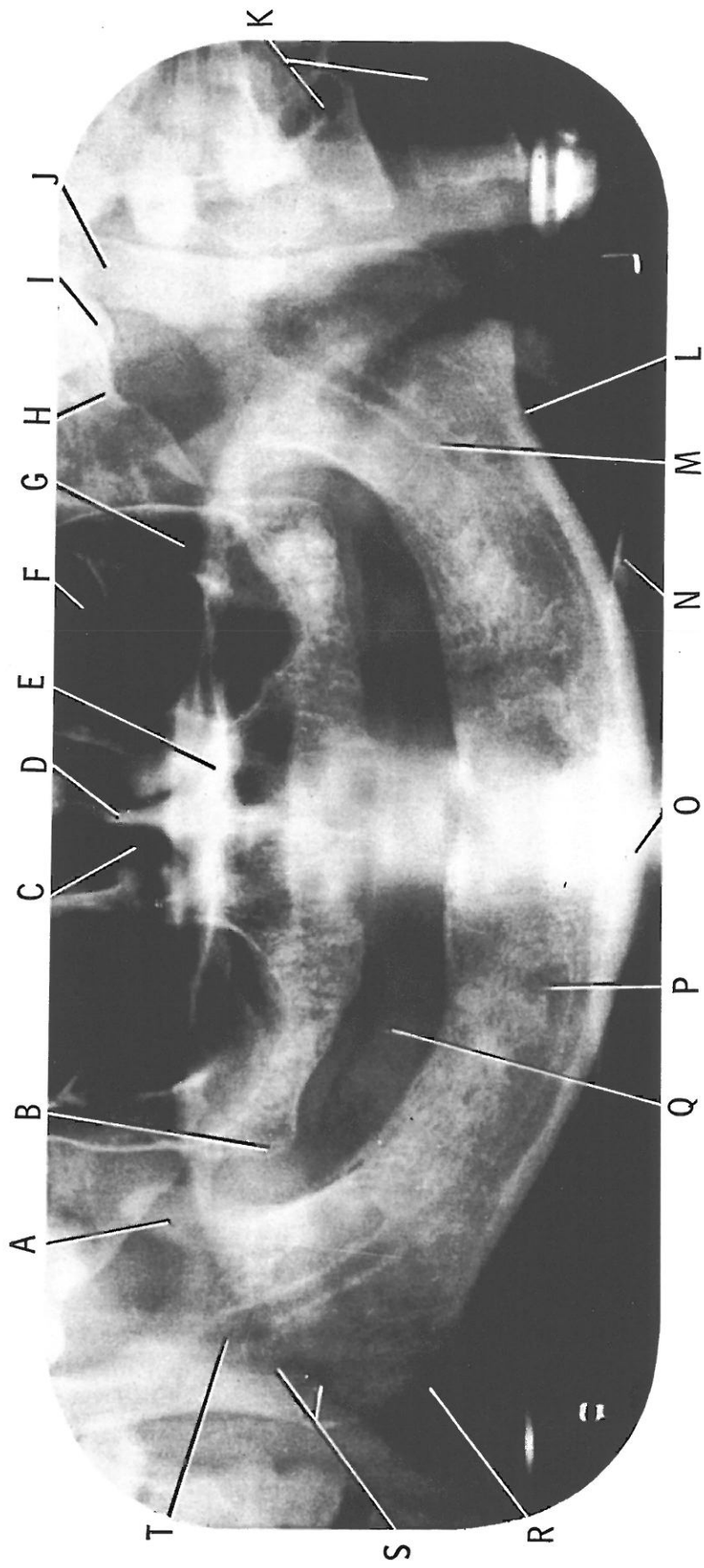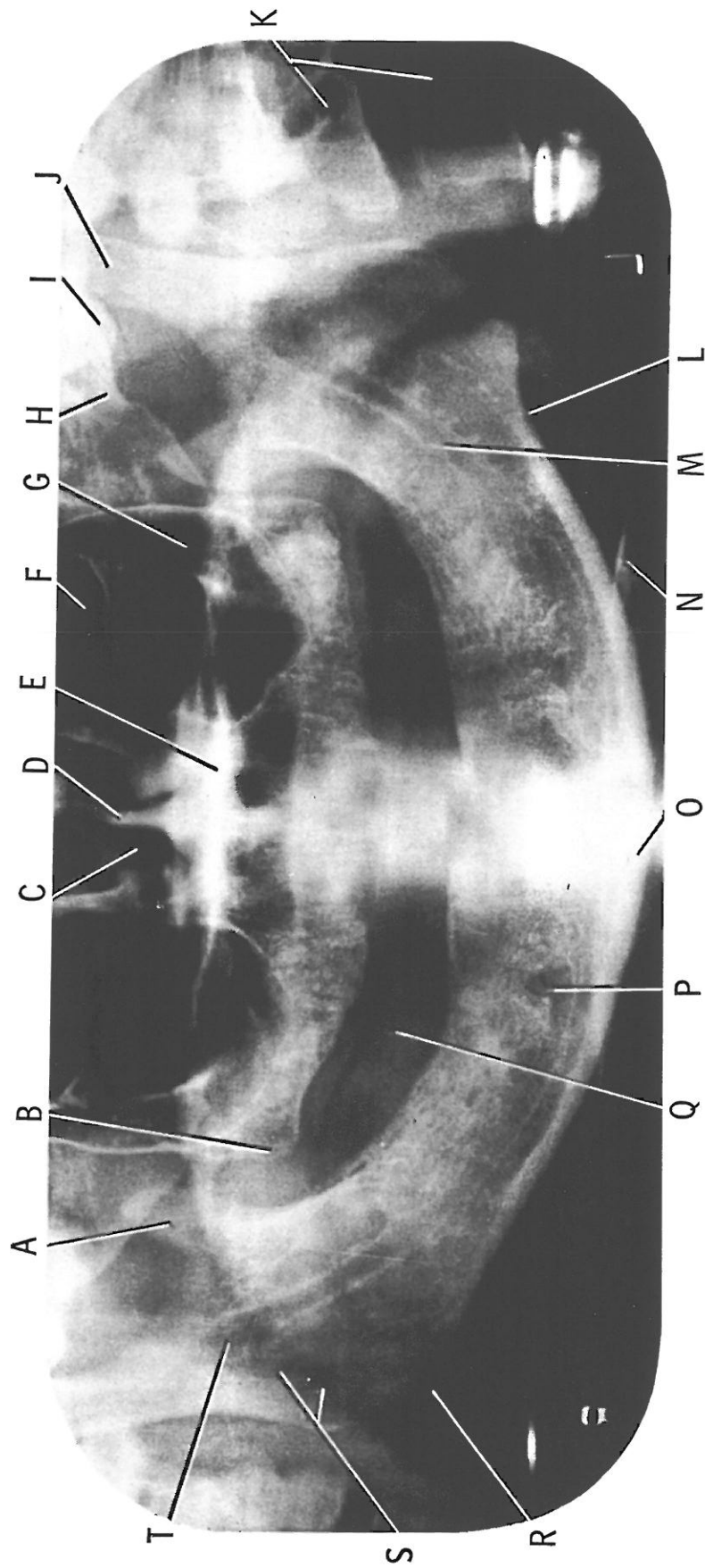


- A) Coronoid process of mandible
- B) Maxillary Tuberosity
- C) Nasal fossa
- D) Nasal Septum
- E) Hard palate
- F) Orbit
- G) Maxillary sinus

- H) Zygomatic arch
- I) Articular eminence
- J) Mandibular condyle
- K) Cervical vertebrae
- L) Facial artery notch
- M) Mandibular canal
- N) Plastic chin rest

- O) Symphysis
- P) Mental foramen
- Q) Shadow of tongue
- R) Angle of mandible
- S) Pharynx
- T) Mandibular foramen

Reprinted from: An Atlas of Dental Radiographic Anatomy, by Kaise, M. J. Third Edition, 1989.



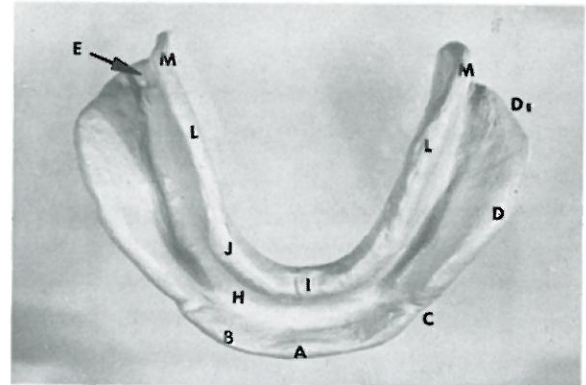
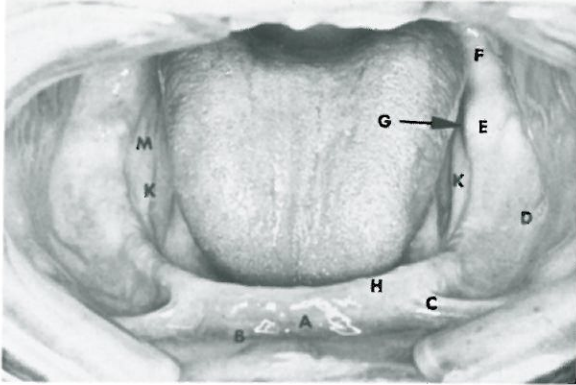
- A) Coronoid process of mandible
- B) Maxillary Tuberosity
- C) Nasal fossa
- D) Nasal Septum
- E) Hard palate
- F) Orbit
- G) Maxillary sinus

- H) Zygomatic arch
- I) Articular eminence
- J) Mandibular condyle
- K) Cervical vertebrae
- L) Facial artery notch
- M) Mandibular canal
- N) Plastic chin rest

- O) Symphysis
- P) Mental foramen
- Q) Shadow of tongue
- R) Angle of mandible
- S) Pharynx
- T) Mandibular foramen

Reprinted from: An Atlas of Dental Radiographic Anatomy, by Kalse, M. J. Third Edition, 1989.

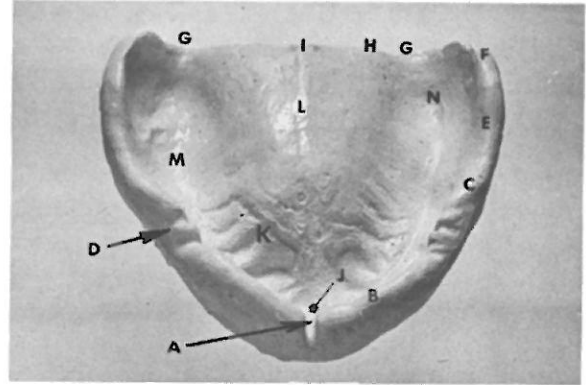
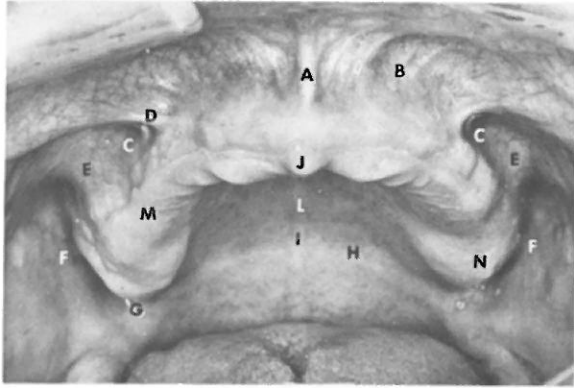
**IMPORTANT ANATOMIC STRUCTURES OF EDENTULOUS  
MANDIBULAR ARCH AND CORRESPONDING LANDMARKS  
ON FINAL IMPRESSION**



- A labial frenum
- B labial vestibule
- C buccal frenum
- D buccal vestibule  
(overlies buccal shelf)
- E retromolar pad
- F pterygomandibular raphe
- G lingual tubercle
- H residual ridge
- I lingual frenum (not shown)
- J anterior portion of alveololingual  
sulcus (not shown)
- K mylohyoid ridge
- M retromylohyoid space

- A labial notch
- B labial flange
- C buccal notch
- D buccal flange
- D1 masseter groove
- E retromolar fossa  
(not recorded on impression)
- G lingual tubercular fossa (not shown)
- H residual ridge groove
- I lingual notch
- J sublingual border
- K mylohyoid groove (not shown)
- L mylohyoid flange
- M retromylohyoid eminence

IMPORTANT ANATOMIC STRUCTURES OF EDENTULOUS  
MAXILLARY ARCH AND CORRESPONDING LANDMARKS  
ON FINAL IMPRESSION



- A labial frenum
- B labial vestibule
- C buccal vestibule (anterior segment)
- D buccal frenum
- E zygomaticoalveolar crest
- F buccal vestibule (posterior segment)  
or retrozygomatic space  
or coronoid bulge
- G hamular notch  
or pterygomaxillary notch
- H vibrating line
- I foveae palatinae
- J incisive papilla
- K palatal rugae (not shown)
- L median palatine raphe
- M residual ridge
- N maxillary tuberosity

- A labial notch
- B labial flange
- C buccal flange
- D buccal notch
- E zygomaticoalveolar border
- F distal buccal flange  
or retrozygomatic eminence  
or coronoid contour
- G hamular notch  
or pterygomaxillary notch
- H distal border of impression (denture)
- I foveae palatinae
- J incisive fossa
- K rugae grooves
- L median palatine groove
- M residual ridge groove
- N maxillary tubercular fossa