

COMPLETE DENTURE PROSTHODONTICS

A STUDY AND PROCEDURE GUIDE

COMPLETE DENTURE PROSTHODONTICS

A STUDY AND PROCEDURE GUIDE

by

Brien R. Lang, D.D.S., M.S.
Professor and Chairman
Department of Complete Denture

William C. Godwin, D.D.S., M.S.
Professor
Department of Complete Denture



We would like to acknowledge the contributions and assistance of the members of the Department of Complete Denture Prosthodontics and the Department of Educational Resources.

Department of Complete Denture:

John R. Blankenship, B.S., D.D.S., M.S.
Bruce E. Bradley, D.D.S., Ph.D.
William J. Davis, D.D.S., M.S.
Charles C. Kelsey, B.S., D.D.S., M.S.
John G. Knapp, B.S., D.D.S., M.S.
Andrew Koran III, D.D.S., M.S.
Glen C. McDowell, D.D.S., M.S.
Leroy M. Pratt, D.D.S.
Michael E. Razzoog, D.D.S., M.S.
William H. Roedema, D.D.S., M.S.
L. Keith Yohn, A.S., A.B., D.D.S., M.S.

We would like to thank Glenna J. Zukowski for typing the text.

Department of Educational Resources:

Francile C. Clevenger, B.A., M.A.

This Study and Procedure Guide is designed to be used with a series of videotapes authored by the members of the Complete Denture Department and produced in the television studios of the University of Michigan School of Dentistry.

Produced jointly by the Department of Complete Denture and the Department of Educational Resources, The University of Michigan, School of Dentistry. Supported in part by grant number DO-00-237-050 of the Department of Health, Education, and Welfare, Bureau of Health Manpower Education.

Copyright © 1976 School of Dentistry, University of Michigan.

TABLE OF CONTENTS

	<u>Page</u>
INTRODUCTION	ix
PRECLINICAL COMPLETE DENTURE PROSTHODONTICS	xv
SECTION ONE - Anatomy of the Edentulous Mouth and Impressions for Complete Dentures	1
Important Anatomic Structures of the Edentulous Maxillary Arch and Corresponding Landmarks of Final Impressions	7
Important Anatomic Structures of the Edentulous Mandibular Arch and Corresponding Landmarks of Final Impressions	8
Important Anatomic Landmarks on the Maxillary and Mandibular Master Casts	9
<u>Procedure #1</u> - Preliminary Alginate Impressions	11
Steps in Making the Preliminary Maxillary Impression	12
Steps in Making the Preliminary Mandibular Impression	15
<u>Procedure #2</u> - Fabricating Acrylic Resin Maxillary and Mandibular Final Impression Trays on the Diagnostic Cast	21
Steps in Fabricating the Maxillary Final Impression Tray	22
Steps in Fabricating the Mandibular Final Impression Tray	30
Steps in Fabricating the Mandibular Wax Occlusal Rim on the Impression Tray	38
<u>Practical Skill Examination #1</u>	46
Self Test #1 - Acrylic Resin Impression Trays and Wax Occlusal Rims	49

	<u>Page</u>
<u>Procedure #3</u> - Border Molding the Final Impression Trays and Making the Final Impressions	57
Steps in Border Molding the Maxillary Final Impression Tray	58
Steps in Border Molding the Mandibular Final Impression Tray	66
Steps in Making the Maxillary Final Impression	73
Steps in Making the Mandibular Final Impression	76
<u>Procedure #4</u> - Boxing the Final Impressions and Pouring the Master Casts	81
The Wax Boxing Method	82
The Impression Plaster-Pumice Boxing Method . .	85
Steps in Developing Arbitrary Posterior Palatal Seal	90
<u>Computer-Generated Section Test 1</u>	94
SECTION TWO - Baseplates and Their Stabilization	95
<u>Procedure #5</u> - Maxillary Shellac and Mandibular Acrylic Resin Baseplates	97
Steps for Fabrication of Shellac Baseplates . .	98
Steps for Constructing Acrylic Resin Mandibular Baseplates	105
<u>Practical Skill Examination #2</u>	110
<u>Self Test #2</u> - Baseplates	113
<u>Procedure #6</u> - Stabilizing the Baseplates	119
<u>Computer-Generated Section Test 2</u>	130
SECTION THREE - Maxillomandibular Jaw Relations	131
<u>Procedure #7</u> - The Face-Bow Transfer	137

	<u>Page</u>
Hanau Measurement Face-Bow Method	137
Hanau Ear Rod Face-Bow Method	142
Steps in Mounting Maxillary Casts	145
<u>Procedure #8</u> - Establishing, Recording and Transferring Maxillomandibular Jaw Relations	151
Occlusal Vertical Dimension	152
Centric Jaw Relation	158
Protrusive Interocclusal Registration	167
<u>Self Test #3</u> - Face-bow and Maxillomandibular Jaw Relations	173
<u>Computer-Generated Section Test 3</u>	179
SECTION FOUR - Articulation and Arranging the Teeth	181
Anterior Denture Teeth.	181
Posterior Denture Teeth	182
Theories of Occlusion	183
<u>Procedure #9</u> - Setting the Anterior Teeth	187
Steps in Mounting the Technic Master Cast	188
Modifying Vinyl Baseplates	191
Steps in Adding Mandibular and Maxillary Wax Occlusal Rims	192
Steps in Setting the Maxillary Anterior Teeth	197
Steps in Setting the Mandibular Anterior Teeth	201
<u>Procedure #10</u> - Setting the Posterior Teeth	207
Steps in Setting the Articulator.	208
Steps in Arranging the Mandibular Posterior Teeth	212

	<u>Page</u>
Steps in Arranging the Maxillary Posterior Teeth	215
<u>Procedure #11</u> - Balance the Occlusion of the Maxil- lary and Mandibular Teeth	219
Centric Occlusion	223
Lateral Movements	224
Protrusive Movement	227
<u>Self Test #4</u> - Arranging Teeth and Balancing the Occlusion	231
<u>Computer-Generated Section Test 4</u>	236
SECTION FIVE - Waxing the Dentures, Making the Occlusal Index, Flasking and Packing the Complete Dentures	237
Working Authorization Order	238
<u>Procedure #12</u> - Waxing the Complete Dentures	241
The Occlusal Index	248
<u>Procedure #13</u> - Flasking and Boil-Out	255
Steps in Flasking	258
Steps in Boil-Out	263
<u>Procedure #14</u> - Packing and Processing	267
Steps in Packing	269
Curing the Acrylic Resin	271
Steps in Deflasking	273
<u>Self Test #5</u> - Wax the Complete Dentures, Occlusal Index, Flasking, Mix and Pack	277
<u>Computer-Generated Section Test 5</u>	280

SECTION SIX - Correcting the Occlusion after Processing, Finishing, and Polishing the Dentures and Delivering the Complete Dentures	281
The Split-Cast Remount Technic	283
Patient Remount Procedures	283
Methods of Correcting the Occlusion	284
Finishing and Polishing	285
Instructions to the Patient	287
<u>Procedure #15</u> - Correcting the Occlusion after Processing	291
Steps in the Split-Cast Remount	292
Steps in Performing Selective Grinding	293
<u>Procedure #16</u> - Finishing and Polishing the Complete Dentures	305
Steps in Finishing and Polishing	305
<u>Procedure #17</u> - Delivering the Complete Dentures	313
Steps in Delivering the Complete Dentures	314
Steps in Performing the Patient Remount	320
Selective Occlusal Grinding	326
<u>Self Test #6</u> - Correcting the Occlusion after Pro- cessing, Finishing, Polishing, Delivering the Complete Denture	341
<u>Computer-Generated Section Test 6</u>	347
SECTION SEVEN - Repairing a Broken Denture, Replacing a Broken Tooth and Glossary of Prosthodontic Terms	349
<u>Procedure #18</u> - Repairing a Broken Denture, Replacing a Denture Tooth	351
Steps in Repairing the Broken Denture	352
Steps in Replacing the Broken Tooth	360

	<u>Page</u>
<u>Self Test #7 - Repairs and Tooth Replacement</u>	367
<u>Computer-Generated Section Test 7</u>	371
<u>Answer Key</u>	372

INTRODUCTION

The Glossary of Prosthodontic Terms defines Prosthodontics as that branch of dental art and science pertaining to the restoration and maintenance of oral function by the replacement of missing teeth and structures by artificial devices.¹ Treatment modalities used in denture prosthodontics include the complete denture which is used to restore the completely edentulous mouth, the removable partial denture for patients with some natural teeth remaining, and combinations of these two in which one jaw (usually the maxilla) is completely edentulous, and the mandible is partially edentulous (Figures 1, 2, and 3).

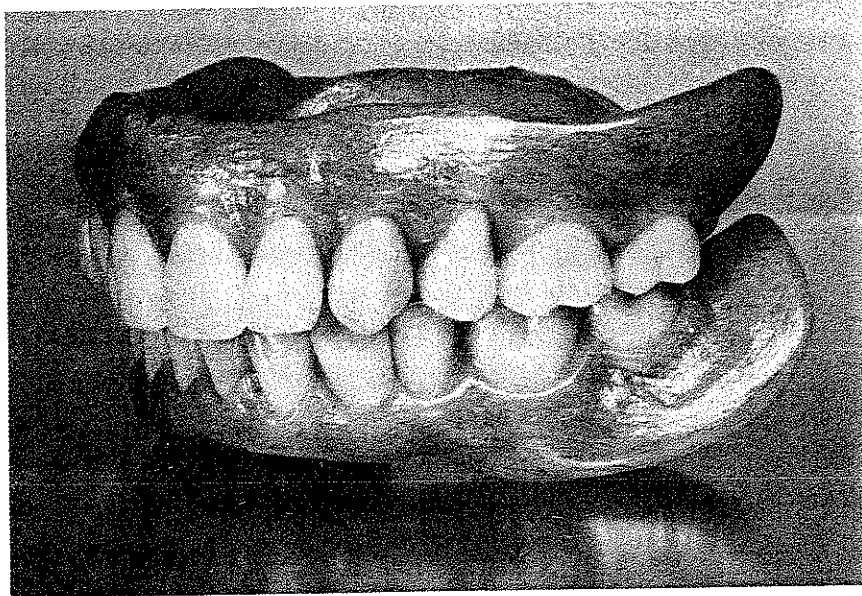


Figure 1. Maxillary and Mandibular Complete Dentures.

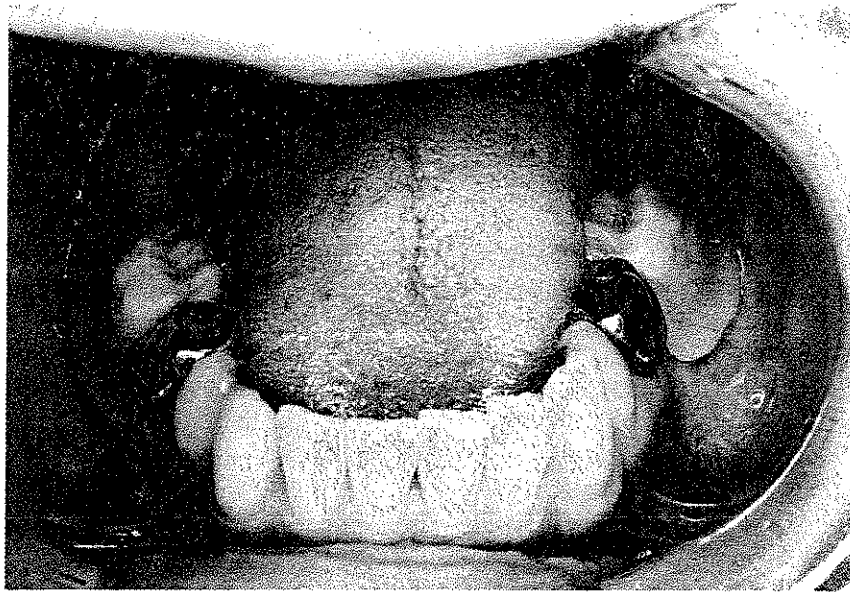


Figure 2. The Removable Partial Denture Supported Both by Natural Teeth and the Remaining Residual Ridge.

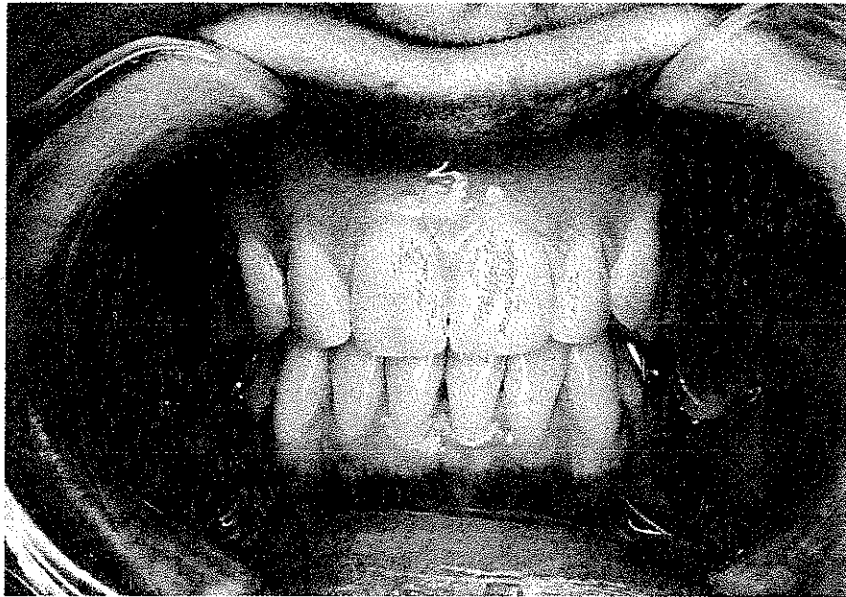


Figure 3. Some Patients Require Both the Complete Denture and the Removable Partial Denture for Comprehensive Dental Care.

The edentulous mouth and patient exhibit oral and facial features that are quite different from the dentulous patients (Figures 4 and 5). The lack of any point of reference intra-orally, and a dramatic change in the patient's facial features and expression extraorally may be confusing to the uninitiated. When one thoughtfully considers the fact that the dentate mouth has root structure and alveolar bone to aid in its support, while the edentulous mouth has neither, the problem of treatment is further compounded. Add to this the physiological fact that bone resorption and changes under dental prostheses are continuous throughout life² and the task of restoration seems insurmountable.

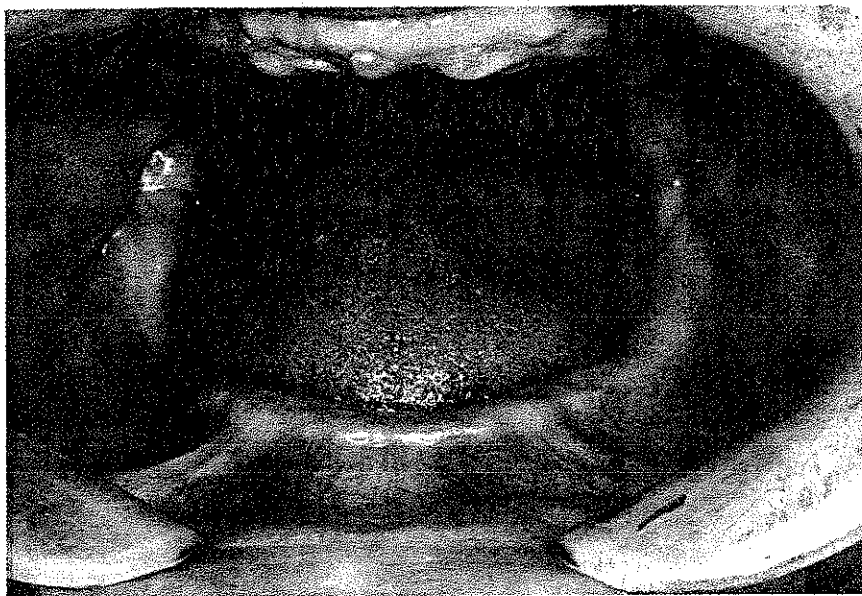


Figure 4. Anatomy of the Edentulous Mandible Showing the Residual Ridge that Supports the Complete Denture.

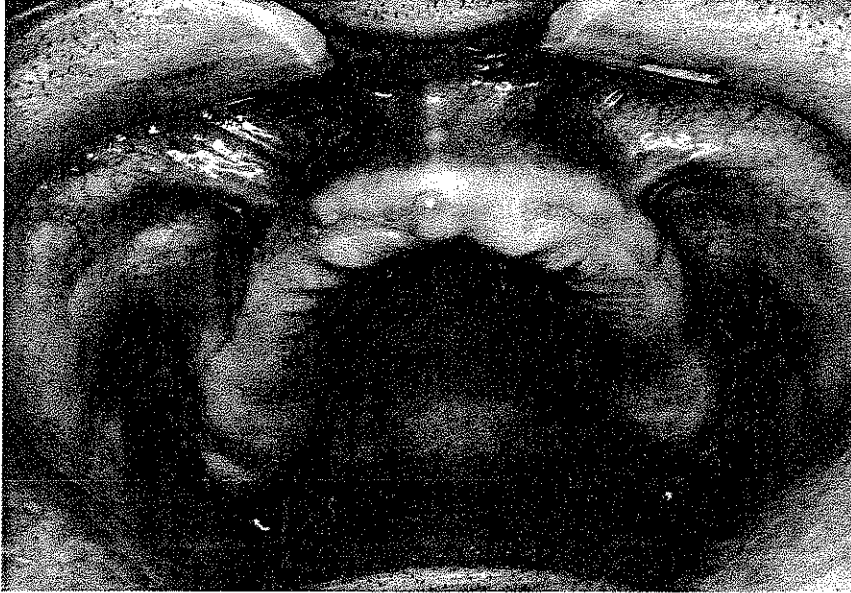


Figure 5. Anatomy of the Edentulous Maxilla Showing the Residual Ridge that Supports the Complete Denture.

The student should keep in mind that in denture prosthodontics, we fabricate prostheses and place them in the center of a complex neuromuscular system. Although there are many acceptable methods used in complete denture construction, only one method will be described in this Study and Procedure Guide. The student will begin to acquire knowledge and develop the skills needed to treat the edentulous patient during the pre-clinical course. He or she will develop further knowledge and skills in the clinical experience in the junior and senior years.

The prosthodontic treatment of the edentulous patient consists of:

- a. Examination, diagnosis, treatment planning, and statement of prognosis.
- b. Tissue management.
- c. Impression procedures.
- d. Registration and transfer of maxillomandibular jaw relations.

- e. Achievement of esthetics.
- f. Establishing an occlusion.
- g. Processing, finishing, and reestablishing the occlusion.
- h. Delivery of finished prostheses.
- i. Recall and maintenance programs.

REFERENCES AND SUGGESTED READINGS

1. Glossary of Prosthodontic Terms. J. Prosth. Dent., 20:443-480, Nov. 1968, pp. 471.
2. Lang, B.R. and Kelsey, C.C. International prosthodontic workshop, The University of Michigan, 1972. p. 337, pp. 29-47.

PRECLINICAL COMPLETE DENTURE PROSTHODONTICS

This is an individualized course in which you may progress at your own rate, but you must meet a minimum schedule.

GOAL

You will learn the terminology and theory of complete denture prosthodontics and complete all laboratory procedures for the construction of a complete denture that do not require the presence of a patient. This will prepare you for patient contact at the start of your junior year in Complete Denture.

OBJECTIVES

Knowledge. Upon completion of this course, you will be able to:

1. Identify the anatomical structures of the edentulous mouth that are associated with the support of complete dentures, the corresponding areas of the final maxillary and mandibular impressions, and the corresponding areas of the maxillary and mandibular master casts.
2. Define and identify terminology and nomenclature used in complete denture prosthodontics.
3. Identify the criteria for the various laboratory and clinical procedures, and state the underlying theory and clinical significance for those procedures.

Skill. You will, for this preclinical course, complete in the laboratory the Procedures which do not require the presence of a patient.

COURSE FORMAT

All instructional materials, including this Study and Procedure Guide, the videotapes, the Self Tests, two Practical Manipulative Skill Examinations and the seven Computer-Generated Section Tests are designed to be used by each student on an individualized basis. The system for viewing the videotapes will be described for you in a handout. You will complete the

procedures in the Study Guide independently, receiving instructor help as needed during regular laboratory hours and receiving instructor initials on your criteria sheets (checkpoints) any-time during regular laboratory hours. When you have completed a Section, you will take a Section Test on the material contained in the Section. The tests must be taken not later than the beginning of the next scheduled laboratory session. You are not limited to regularly scheduled hours for performing the Procedures; however, all checkpoints must be completed during scheduled class time. It will be of benefit to you to use for Complete Denture those laboratory hours that are scheduled for Complete Denture.

You must take each of the practical Manipulative Skill Examinations in the laboratory during scheduled laboratory hours whenever you are ready for them. The Computer-Generated Section Tests may be taken any time as long as you meet the minimum schedule.

This Study and Procedure Guide is designed in the same sequential manner as one would use in the treatment of the totally edentulous patient. Each Procedure builds upon the knowledge and skills acquired in the previous Procedure. Therefore, you will:

1. Study the written material and view the videotapes on the Procedures in sequence.
2. Complete the laboratory Procedures following the steps outlined in the Study and Procedure Guide. Evaluate your own product by checking it against the criteria sheet in the Study Guide immediately following the procedural steps and then take the criteria sheet and the product to the instructor for discussion. The instructor will mark the criteria not met on the criteria sheet and attempt to explain the reasons for your difficulty. After you have made any necessary corrections in your product, your instructor will initial and date the criteria sheet as an indication that the product is passed as acceptable. Instructors will be available in the laboratory during laboratory hours to assist and to evaluate your efforts.
3. Complete each of the seven (7) Computer-Generated Section Tests at the end of each section before proceeding to the next section.
4. Complete two Manipulative Skill (Practical) Examinations.
 - (1) Fabricate a Mandibular Acrylic Resin Final Impression Tray with Wax Occlusal Rim.
 - (2) Fabricate a Maxillary Shellac Baseplate.

These examinations will be completed in the laboratory during regular laboratory hours using the instructions within this Study and Procedure Guide, but without instructor assistance, and within the specified time limits of 1 1/2 hours for each examination. The examinations may be taken any time after you have completed the Laboratory Procedure, but must be taken no later than the date listed in the Minimum Laboratory Procedures Schedule.

COMPUTER-GENERATED SECTION TESTS

Listed below are the Section Tests and their subject matter content.

<u>Test #</u>	<u>Content</u>
1	Anatomy of the Edentulous Mouth and Corresponding Landmarks on the Final Impressions and on the Master Casts. Preliminary Impressions, Final Impression Trays, Final Impressions, Boxing the Final Impressions and Pouring the Master Casts, Functional and Mechanical Posterior Palatal Seals.
2	Baseplates, Stabilizing the Baseplates.
3	Face-Bow Transfer, Maxillomandibular Jaw Relations.
4	Setting Anterior Teeth, Setting Posterior Teeth, Balancing Posterior Teeth.
5	Waxing the Complete Dentures, Making the Occlusal Index, Flasking the Complete Dentures, Mixing Acrylic Resin and Packing the Complete Dentures.
6	Correcting the Occlusion of the Complete Dentures After Processing, Finishing and Polishing the Complete Dentures, Delivering the Complete Dentures to the Patient.
7	Repairing a Broken Denture, Replacing a Denture Tooth, Glossary.

These Tests are selected for you from a computer bank of questions so that every student's test is different from, but equivalent to, every other student's test. When you have completed the laboratory Procedures which the Section Test covers, and are ready to take that Section Test, go to the Caident Center. All Section Tests are on the computer. The proctor in

the Caident Center will instruct you on how to take the test. As you take the test, the computer will inform you of your incorrect answers and tell you the correct answer. As soon as you have completed the test, the computer will display your score. You will fill out a computer card, which will be sent to Central Records to record your progress and grade and the proctor in the Caident Center will stamp the Section Test criteria sheet in your manual.

MINIMUM LABORATORY PROCEDURES SCHEDULE

To complete this course by the end of the term and in order for the Dental School Laboratory to be able to process your dentures on time, you must complete the laboratory Procedures as outlined in the Schedule. You may complete any or all Procedures, Examinations, and Tests ahead of schedule and may complete the course ahead of the schedule if you so desire.

STUDENT EVALUATION

Evaluation will be on the basis of:

Performance	Proportion of Final Grade
1. Sum of scores on Seven Computer-Generated Section Tests.	One Third
2. Practical Manipulative Skill Examination #1.	One Third
3. Practical Manipulative Skill Examination #2.	One Third
4. Completion of a maxillary and a mandibular complete denture in the laboratory.	Pass - Fail

CRITERIA SHEETS

Criteria sheets, which list all the criteria for an acceptable product, are found after the step-by-step instructions for each Procedure. The criteria sheets perform the following functions:


1. Inform the student of the specifications for his product before he starts making it in the laboratory.
2. Serve as a reference during the fabrication of his product.

3. Serve as a checklist against which the student will check his product before seeking an evaluation with his instructor.
4. Serve the instructor as a reminder of criteria and as a focus for discussion with the student about his product. The instructor will mark any criteria not met.
5. Serve as a mechanism to determine how well the student is able to evaluate his own work.

The criteria sheets are included in the Study and Procedure Guide for the purpose of training you to fabricate products according to specifications and to know when your product meets those specifications. Therefore, you are encouraged to proceed independently and assure that your product meets the criteria before seeking an evaluation with your instructor. However, your instructor is there to help you any time you have a problem and you are encouraged to seek assistance any time you need it.

SELF TESTS

There are Self Tests throughout the Study and Procedure Guide. These Self Tests are to assist you in evaluating your understanding of the didactic and laboratory aspects of the Procedures. Take these tests on an independent basis and score yourself using the ANSWER KEYS found in the back of the Study and Procedure Guide.



ANATOMY OF THE EDENTULOUS MOUTH
AND IMPRESSIONS FOR COMPLETE DENTURES

SECTION



OBJECTIVES

Knowledge. Upon completion of this Section, you will be able to:

1. Identify the anatomical structures of the edentulous mouth that are associated with the support of complete dentures, using a list and illustrations.
2. Identify the areas of edentulous maxillary and mandibular final impressions that correspond to the anatomical structures associated with the support of complete dentures, using a list and illustrations.
3. Identify the areas of edentulous maxillary and mandibular master casts that correspond to the anatomical structures associated with the support of complete dentures, using a list and illustrations.
4. Name and define: a) complete denture impression, b) preliminary impression, c) final impression, d) impression tray, e) diagnostic cast, f) master cast.
5. State, for the products named in objective 4, a) the criteria for clinically acceptable products, b) the reasons for making the products, c) the materials from which they are made, and d) their relationship to the mouth and to each other.
6. List the steps in making preliminary impressions.
7. Give reasons for precautions taken during certain steps in the making of preliminary impressions.
8. List the steps in making final impressions.
9. Give reasons for precautions taken during certain steps in making of final impressions.
10. Identify good and poor impressions.
11. List the steps and requirements in preparing diagnostic and master casts.

Skill. You will develop the skills necessary to complete Procedure #2 and a portion of Procedure #4.

ANATOMICAL FEATURES OF THE EDENTULOUS MOUTH

The dentist must know the anatomical features of the edentulous mouth that form the supporting structures for complete dentures. He must also be able to recognize the structures and various landmarks and whether they are properly recorded in the final impressions. In addition, he must be able to identify these landmarks and anatomical features as reproduced in the master casts.

The important anatomic structures of the edentulous maxillary and mandibular arches and the corresponding landmarks on the final impressions and master casts are shown on the pages that follow.

References are cited and must be studied in detail to better understand the anatomy of the edentulous mouth, impression making, recognition of supporting structures, landmarks in the impression and on both the diagnostic and master casts.

IMPRESSIONS FOR COMPLETE DENTURES

Making preliminary and final impressions are the first clinical steps in complete denture construction following the recording of the patient's history, oral examination, diagnosis, and planning of the patient's treatment. It must be emphasized that impression making is performed only after the correction of any muscular, temporomandibular joint, and mucosal disturbances.

DEFINITIONS

Complete Denture Impression. An impression of an edentulous arch made for the purpose of constructing a complete denture.¹

Preliminary Impression. An impression made for the purpose of diagnosis, or for the construction of a tray.¹

Impression Tray. 1) A receptacle into which a suitable material is placed to make an impression.¹ 2) A device which is used to carry, confine, and control an impression material for making an impression.¹

Final Impression. An impression which is used for making the master cast.¹

Master Cast. A replica of the prepared tooth surface, residual ridge area, and/or other parts of the dental arch as reproduced from an impression.¹

Diagnostic Cast. A positive likeness of dental structures for the purpose of study and treatment planning.¹

To aid in retention and stability, complete denture bases must be constructed so that they provide maximum coverage of the basal seat areas. The borders of impressions must be molded to the oral tissues so that the dentures will not be dislodged during function. The dentist must know the anatomic features of the edentulous mouth and recognize the landmarks recorded in the impression in order to recognize when the border has been correctly molded.

The dentist:

1. Makes diagnostic casts, using the preliminary alginate impressions.
2. Constructs custom acrylic resin impression trays on the diagnostic casts.
3. Border molds the custom acrylic impression trays.
4. Makes final impressions by placing the customized, border molded acrylic resin impression tray containing a thin wash of impression material in the patient's mouth.

Dental materials used for making impressions of edentulous mouths are: 1) zinc oxide-eugenol paste, 2) Mercaptan polysulfide (rubber base), and 3) silicone elastomers (silicone rubber).

The acrylic resin impression tray is used to carry the impression material to the ridge supporting areas, so that these tissues may be recorded accurately without distorting or displacing the tissues. The outline form of the tray is established on the diagnostic cast and later checked in the patient's mouth. The impression tray is provided with a relief space during its construction so that the tissues over the residual ridge will not be displaced when making the final impression. In addition, holes are placed in strategic areas of the tray to reduce the potential for pressure, which can be created by the impression material confined within the tray as it is delivered over the ridge area.

RETENTION

Retention is the means by which dentures are held in position in the mouth. Saliva is considered a major factor in the physical forces that contribute to denture retention. The physical forces in which saliva is involved are: a) adhesion, b) cohesion, and c) capillarity. These forces are defined:

Adhesion. Adhesion is the binding force exerted by molecules of unlike substances in contact.

Cohesion. Cohesion is that force by which molecules of the same kind or the same body are held together.

Capillarity. Capillarity is a form of surface tension between molecules of a liquid and those of a solid.

Patients do not have a problem with denture retention if their saliva is watery and thus has a high surface tension, and all other retention factors are acceptable.

Another factor involved in retention is the partial vacuum that is created between the denture and the tissues of the mouth allowing atmospheric pressure to become an influencing force. This partial vacuum depends on the peripheral seal of the borders of the denture. To insure this seal, denture borders should extend to movable tissue, but not to the extent that damage is done to the tissue.

Border molding the maxillary final impression tray with compound provides the operator with the opportunity to develop a peripheral seal for the labial and buccal flanges. The peripheral seal across the posterior border of the denture is determined in a different manner.

The posterior border of the maxillary denture must extend at least to the vibrating line. The vibrating line is an imaginary line drawn across the palate which marks the beginning of motion in the palate when the patient says "ah". It is a line extending from one pterygomaxillary notch to the other. It usually covers the foveae palatinae. The vibrating line is not to be confused with the junction of the hard and soft palates, and it is usually not a well-defined line. To aid in the retention of the maxillary denture, a posterior palatal seal is added to the denture base.

POSTERIOR PALATAL SEAL - DEFINITIONS

Posterior Palatal Seal Area. The soft tissues along the junction of the hard and soft palates on which pressures within the physiologic limits of the tissues can be applied by a denture to aid in the retention of the denture.¹

Posterior Palatal Seal (Post-Dam). The seal at the posterior border of a denture.¹

TYPES OF POSTERIOR PALATAL SEALS

There are two different types of posterior palatal seals used in developing the posterior area of the maxillary denture.

1. Functional - soft wax is added to the posterior areas of the final impression in a specific manner and the final impression returned to the mouth so that the tissues may determine the final configuration of the wax.
2. Mechanical - the master cast is altered in the posterior region mechanically by the operator using burs and scraping away some of the stone prior to processing the denture base.

PREPARING THE MASTER CAST

The master cast is a replica of the denture supporting area of the edentulous mouth as reproduced from a final impression and is used for the fabrication of the complete denture. The master cast must not be altered in any way except to develop an arbitrary posterior palatal seal.

There are two generally accepted methods used to produce satisfactory master casts from final impressions.

1. "Wax-Boxed" impressions.
2. Imbed the final impression in a 3:1 mixture of plaster and filler, (i.e., pumice or sawdust), wall, pour, and trim it to the configuration of a satisfactory master cast.

The "Wax-Boxed" impression method is used for producing the maxillary master cast. The mandibular master cast is produced by the 3:1 mixture of impression plaster and filler. Regardless of the method used, the final characteristics of master casts are the same.

POURING THE FINAL IMPRESSION

The dental stone and water used in making master casts should be measured in order to achieve the most desirable working consistency and to create a master cast that is accurate and hard. The proper proportions are a water/powder ratio of 30 cc./100 gms. A mix of 45 cc./150 gms. is the amount needed for making the average size master cast. Do not use plaster or improved dental stone for making master casts, because plaster is too soft and easily broken and improved dental stone is very difficult to remove from the finished denture.

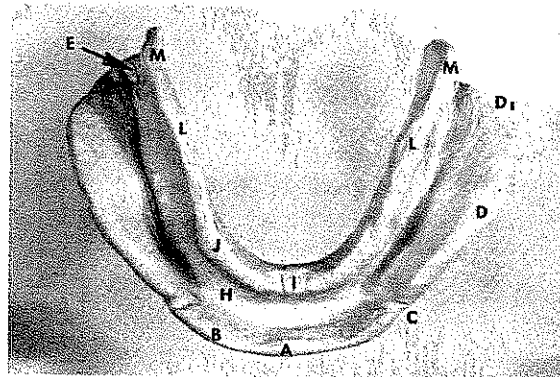
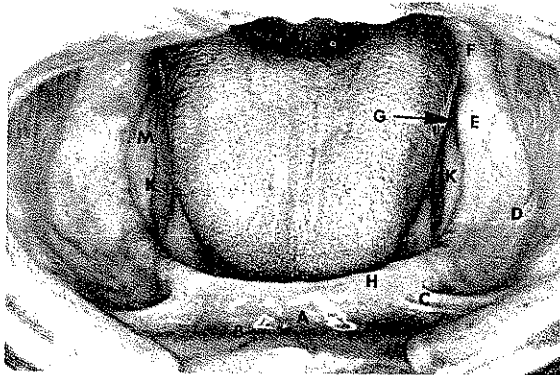
The base of a master cast must be about 1/2 inch thick. It must not be too thin or too thick because:

- (1.) If the base is too thick - the master cast cannot be mounted on an articulator or placed in a processing flask.
- (2.) If the base is too thin - the master cast will not have sufficient strength, and may break during the compression of the acrylic resin in the processing procedure of making the dentures.

REFERENCES AND SUGGESTED READINGS

1. Glossary of Prosthodontic Terms. 3rd ed. J. Prosthet. Dent., 20:443-80, 1968.
2. Kolb, H.R.: Variable denture-limiting structures of the edentulous mouth. Part I, maxillary border areas. J. Prosthet. Dent., 16:194-201, Mar.-Apr. 1966.
3. Kolb, H.R.: Variable denture-limiting structures of the edentulous mouth. Part II, mandibular border areas. J. Prosthet. Dent., 16:202-212, Mar.-Apr. 1966.
4. Sharry, J.J.: Complete Denture Prosthodontics. 3rd ed. New York, McGraw-Hill, 1974, xvi + 378 p. (pp. 191-210).
5. Frank, R.P.: Controlling pressure during complete denture impressions. Dent. Clinic. N. Am., 14:453-70, July, 1970.

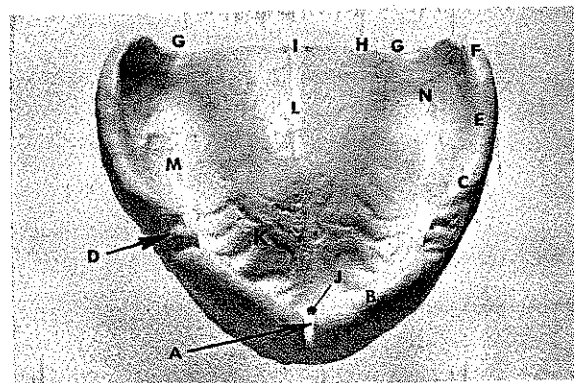
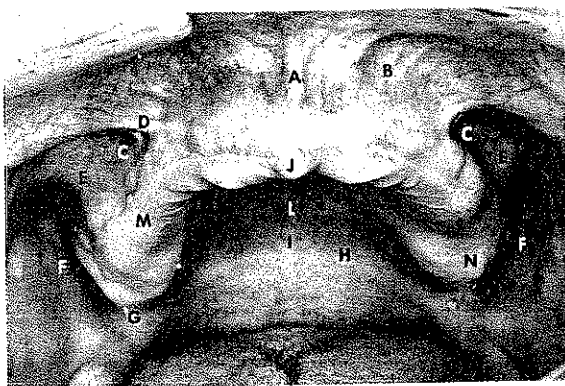
IMPORTANT ANATOMIC STRUCTURES OF EDENTULOUS MANDIBULAR ARCH
AND CORRESPONDING LANDMARKS OF FINAL IMPRESSION



- A. labial frenum
- B. labial vestibule
- C. buccal frenum
- D. buccal vestibule
(overlies buccal shelf)
- E. retromolar pad
- F. pterygomandibular raphe
- G. lingual tubercle
- H. residual alveolar ridge
- I. lingual frenum (not shown)
- J. anterior portion of
alveololingual sulcus
(not shown)
- K. mylohyoid ridge
- M. retromylohyoid space

- A. labial notch
- B. labial flange
- C. buccal notch
- D. buccal flange
- D¹ masseter groove
- E. retromolar fossa
- F. (Not recorded on
impression)
- G. lingual tubercular
fossa (not shown)
- H. alveolar groove
- I. lingual notch
- J. sublingual border
- K. mylohyoid groove
(not shown)
- L. mylohyoid flange
- M. retromylohyoid
eminence

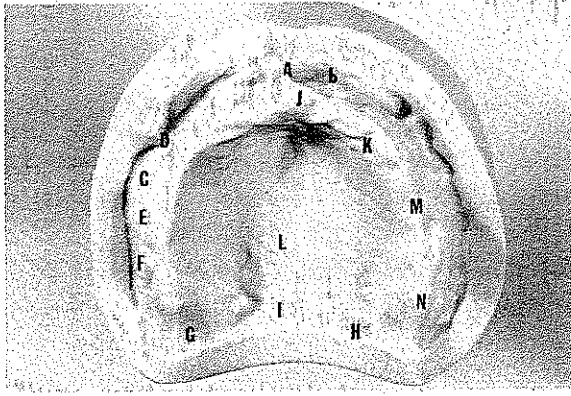
IMPORTANT ANATOMIC STRUCTURES OF EDENTULOUS MAXILLARY ARCH AND CORRESPONDING LANDMARKS OF FINAL IMPRESSION



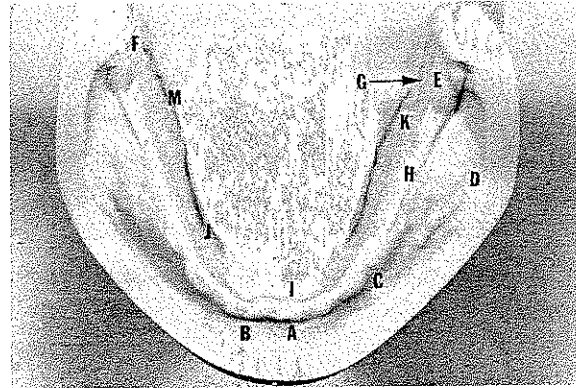
- A. labial frenum
- B. labial vestibule
- C. buccal vestibule (anterior segment)
- D. buccal frenum
- E. zygomaticoalveolar crest
- F. buccal vestibule (posterior segment) or retrozygomatic space or coronoid bulge
- G. hamular notch or pterygomaxillary notch
- H. vibrating line
- I. foveae palatinae
- J. incisive papilla
- K. palatal rugae (not shown)
- L. median palatine raphe
- M. residual alveolar ridge
- N. maxillary tuberosity

- A. labial notch
- B. labial flange
- C. buccal flange
- D. buccal notch
- E. zygomaticoalveolar border
- F. distal buccal flange or retrozygomatic eminence or coronoid contour
- G. hamular notch or pterygomaxillary notch
- H. distal border of impression (denture)
- I. foveae palatinae
- J. incisive fossa
- K. rugae grooves
- L. median palatine grooves
- M. alveolar groove
- N. maxillary tubercular fossa

IMPORTANT ANATOMIC LANDMARKS
ON THE MAXILLARY AND MANDIBULAR MASTER CASTS



- A. labial frenum
- B. labial vestibule
- C. buccal vestibule
(anterior segment)
- D. buccal frenum
- E. zygomaticoalveolar crest
- F. buccal vestibule
(posterior segment)
or retrozygomatic space
or coronoid bulge
- G. hamular notch
or pterygomaxillary notch
- H. vibrating line
- I. foveae palatinae
- J. incisive papilla
- K. palatal rugae
- L. median palatine raphe
- M. residual alveolar ridge
- N. maxillary tuberosity



- A. labial frenum
- B. labial vestibule
- C. buccal frenum
- D. buccal vestibule
(overlies buccal shelf)
- E. retromolar pad
- F. pterygomandibular raphe
- G. lingual tubercle
- H. residual alveolar ridge
- I. lingual frenum
- J. anterior portion of
alveololingual sulcus
- K. mylohyoid ridge
- M. retromylohyoid space

OBJECTIVES

Knowledge. You will view the videotapes and study the written material within this Study and Procedure Guide and upon completion of this Procedure be able to:

1. List the steps in making maxillary and mandibular preliminary impressions with alginate in Winkler-McGowen edentulous trays for a patient requiring a complete denture.
2. List the steps in making diagnostic casts from these preliminary impressions, using a mix of half and half impression plaster and dental stone.
3. Describe the precautions to take at certain procedural steps in order to avoid potential difficulties.
4. Name the criteria for a clinically acceptable product.

Skill. Although you will not perform these procedures in the preclinical course, you should know how they are done in order to better understand their significance in the overall management of the complete denture patient.

VIDEOTAPES

1. Making and Pouring Preliminary Impressions (Alginate).
2. Trimming the Edentulous Preliminary Model.

MATERIALS NEEDED FOR PROCEDURE #1

1. Winkler-McGowen edentulous trays (Figure 1:1).
2. Rubber bowl.
3. Stainless steel Kerr Laboratory spatula (for mixing alginate).
4. Alginate and water measurer.
5. Maxillary and mandibular rubber base formers.
6. Red handled knife and #25 blade.




Figure 1:1. Winkler-McGowen Edentulous Trays.

STEPS IN MAKING A PRELIMINARY MAXILLARY IMPRESSION WITH ALGINATE AND IN MAKING A DIAGNOSTIC CAST FROM THE IMPRESSION

1. Position the patient upright in the dental chair in order to control the impression material.
2. Check the fit of the Winkler-McGowen edentulous maxillary tray to the maxillary arch. These trays are available in several sizes for making preliminary alginate impressions. The tray must cover the available supporting tissues, and must be slightly oversized with 3-5 mms. of space existing between the tray and the soft tissues. Small changes can be made by bending the tray or by adding red boxing wax in appropriate areas.
3. Mix the alginate (1 pkg. of powder or 3 scoops) with a little more than 2-1/2 units of room temperature (70°F.) water in a rubber bowl with a laboratory spatula.
4. Place the alginate within the impression tray to the level of the tray flanges. Avoid overfilling the tray. Smooth the impression material with a water-moistened finger.
5. With your index finger, place a small amount of alginate on either side of the patient's labial frenum and position the impression tray in the patient's mouth, seating the posterior section first. This will control the flow of alginate from the posterior border of the tray.

When the alginate appears to roll at the peripheries, hold the tray in position until the alginate has set. Do not leave your patient.!

6. Remove the maxillary impression and rinse thoroughly in cold water (Figure 1:2).

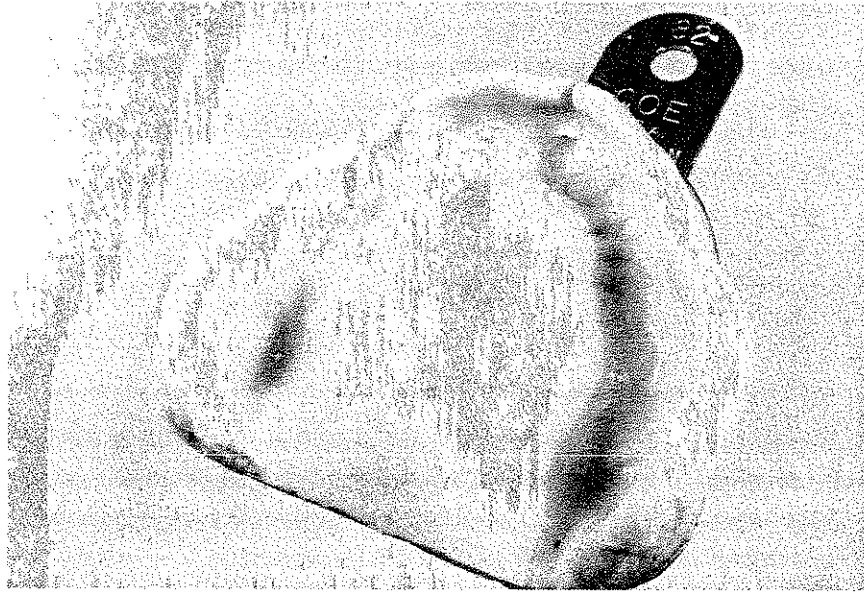


Figure 1:2. Maxillary Preliminary Alginate Impressions Recording the Available Supporting Tissues for the Complete Denture.

Patient Concerns! Immediately upon removal of the impression from the mouth you should assist your patient in rinsing and cleansing any and all of the impression material that may have been left behind. The patient is your responsibility and you should show an earnest concern for his or her comfort. Also remove any impression material that may adhere to the patient's cheeks and other areas about the face.

7. Pour the preliminary maxillary impression with a mixture of impression plaster and dental stone (yellow) to make a diagnostic cast of the maxillary ridge. The amount of plaster-stone mixture required for each impression and base former is 2 cups of impression.

plaster plus 2 cups of dental stone (yellow) and the necessary amount of water to prepare a workable mix. When the impression has been filled with the plaster-stone mix, the remaining plaster and stone should be placed in the rubber base former and the impression inverted and positioned in its center.

8. After the plaster-stone mix has set, remove the impression tray and alginate and recover the diagnostic cast (Figure 1:3). Adjust the peripheries of the diagnostic cast, using the model trimmer, in preparation for the construction of the custom impression tray in Procedure #2. You must adjust the peripheries well in advance of constructing the impression tray in order to allow time for the diagnostic cast to dry (Figure 1:4).

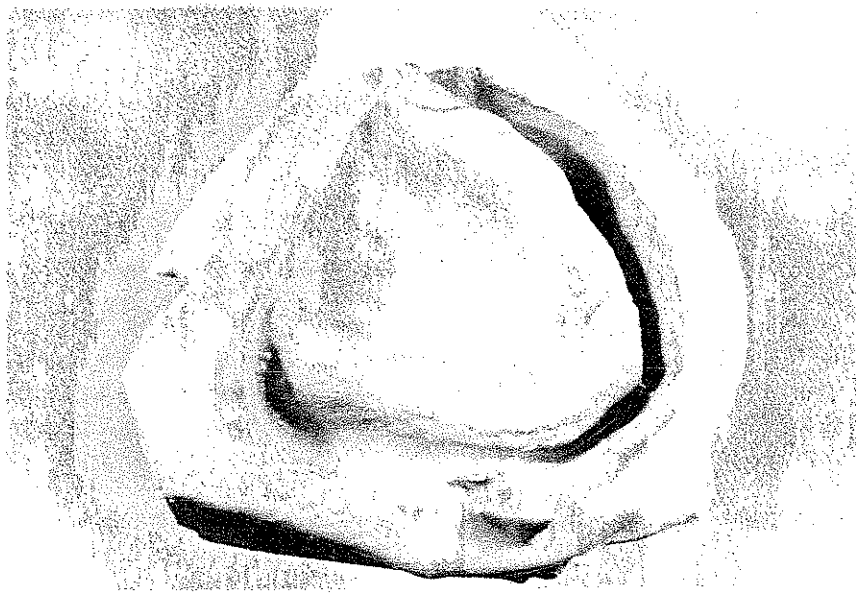

Figure 1:3. Maxillary Diagnostic Cast after Removal of the Impression Tray and Alginate.

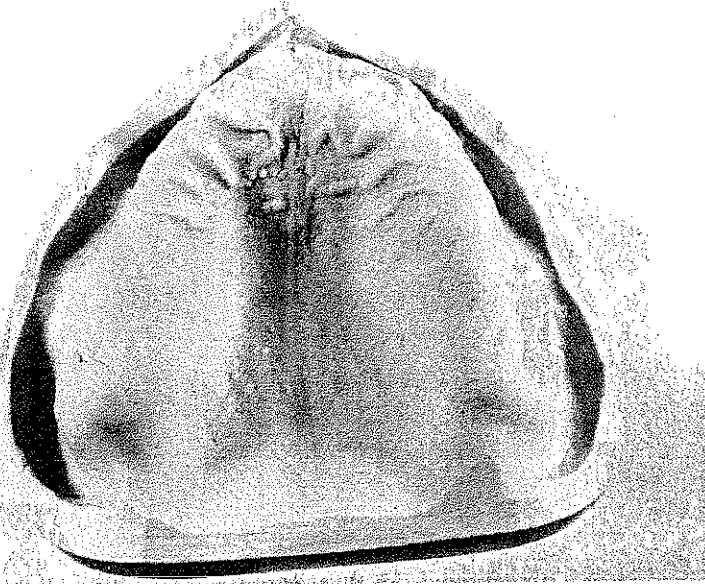


Figure 1:4. Maxillary Diagnostic Cast after Adjustment on the Model Trimmer.

STEPS IN MAKING A PRELIMINARY ALGINATE IMPRESSION OF AN EDENTU-
LOUS MANDIBULAR ARCH AND IN MAKING A DIAGNOSTIC CAST FROM THE
IMPRESSION

1. Check the fit of the Winkler-McGowen mandibular edentulous tray to the mandibular ridge. Small changes may be made by bending the tray or by adding red boxing wax in appropriate areas.
2. Mix alginate (1 pkg. of powder or 3 scoops) with a little more than 2-1/2 units of room temperature (70°F.) water in the rubber bowl with the laboratory spatula.
3. Place the alginate into the impression tray to the level of the flanges. Avoid overfilling the tray. Smooth the impression material with a moistened finger.
4. Deliver the impression tray over the mandibular ridge area and gently seat it until the impression material rolls at the peripheries. Ask the patient to lift his tongue, so that the tongue is not trapped beneath

the tray flanges. If you fail to do this, you will not obtain an impression of the retromylohyoid space (Figure 1:5) and the lingual flange area cannot be developed in alginate. Hold in position until the material is set.

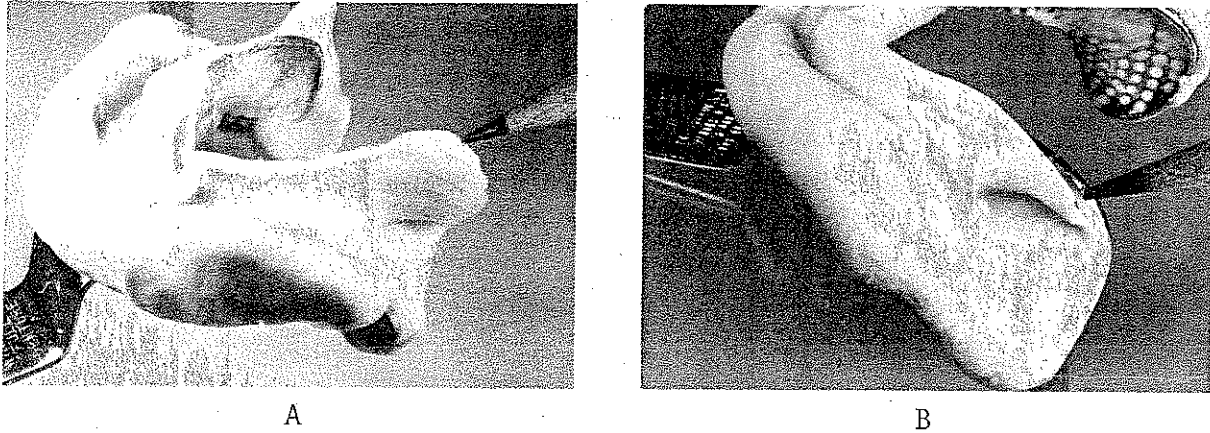


Figure 1:5. Mandibular Preliminary Alginate Impression Showing, A) Correct Impression of Retromylohyoid Space, and B) Incorrect Impression of Retromylohyoid Space.

5. Remove the impression tray and rinse thoroughly in cold water (Figure 1:6). Remember to be concerned about the patient's comfort and well being.
6. Pour the preliminary mandibular impression with a mixture of impression plaster and dental stone (yellow) to make a diagnostic cast of the mandibular ridge. BE SURE TO CLEAR THE TONGUE SPACE TO THE LINGUAL BORDERS OF THE ALGINATE IMPRESSION BEFORE THE PLASTER-STONE MIXTURE SETS. After the plaster-stone mixture has set remove the impression tray and alginate and recover the diagnostic cast (Figure 1:7). Adjust the peripheries with the model trimmer in preparation for construction of the custom impression tray. Allow sufficient time for the diagnostic cast to dry thoroughly before constructing the custom impression tray (Figure 1:8).

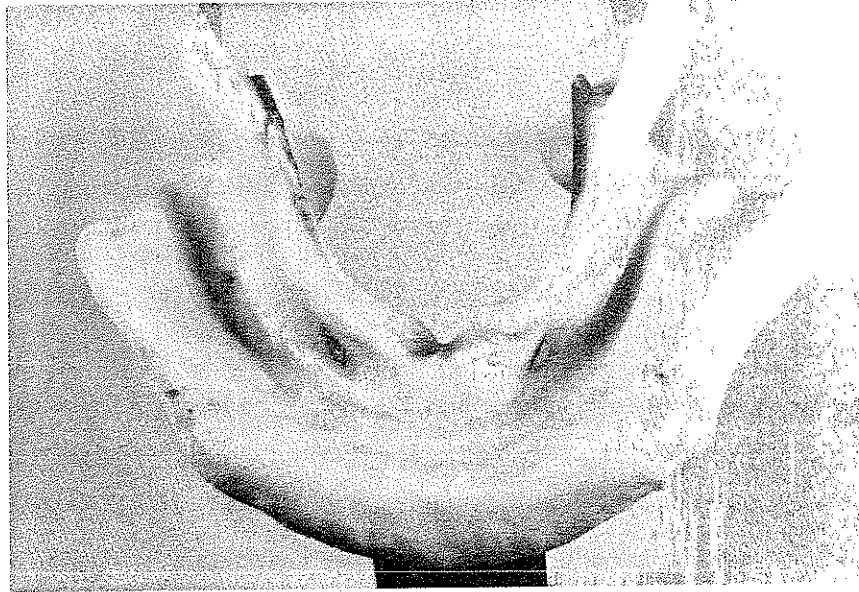
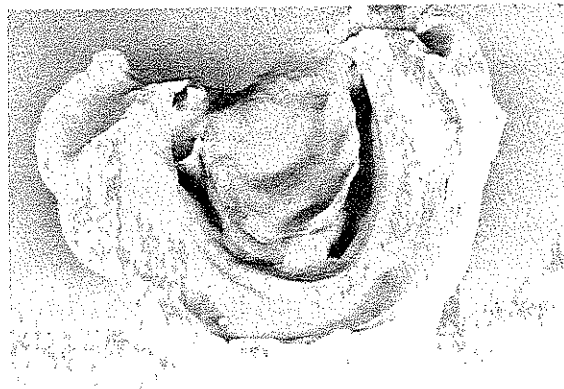


Figure 1:6. A Preliminary Alginate Impression of the Edentulous Mandibular Arch that Meets the Criteria.



A



B

Figure 1:7. Mandibular Diagnostic Cast After Removal of the Impression Tray and Alginate. A) Incorrect, Tongue Space Not Cleared During Pouring. B) Correct, Tongue Space Cleared.

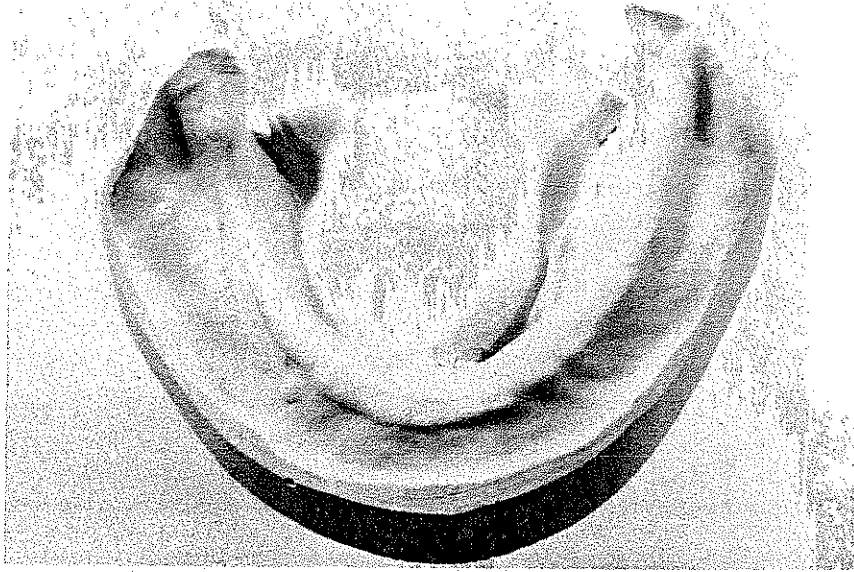


Figure 1:8. Mandibular Diagnostic Cast After Adjustment on the Model Trimmer.

CRITERIA - PRELIMINARY ALGINATE IMPRESSIONS

			<u>Meets</u> <u>Criteria</u>	<u>Does not</u> <u>meet Criteria</u>	<u>Comments</u>
1.	The impression material is evenly distributed within the trays.				
	Maxillary		<input type="checkbox"/>	<input type="checkbox"/>	
	Mandibular		<input type="checkbox"/>	<input type="checkbox"/>	
2.	The impression material was properly mixed.				
	Maxillary		<input type="checkbox"/>	<input type="checkbox"/>	
	Mandibular		<input type="checkbox"/>	<input type="checkbox"/>	
3.	The peripheries are well defined.				
	Maxillary	Labial	Right	<input type="checkbox"/>	<input type="checkbox"/>
			Left	<input type="checkbox"/>	<input type="checkbox"/>
	Maxillary	Buccal	Right	<input type="checkbox"/>	<input type="checkbox"/>
			Left	<input type="checkbox"/>	<input type="checkbox"/>
	Mandibular	Labial	Right	<input type="checkbox"/>	<input type="checkbox"/>
			Left	<input type="checkbox"/>	<input type="checkbox"/>
	Mandibular	Buccal	Right	<input type="checkbox"/>	<input type="checkbox"/>
			Left	<input type="checkbox"/>	<input type="checkbox"/>
		Lingual	Right	<input type="checkbox"/>	<input type="checkbox"/>
			Left	<input type="checkbox"/>	<input type="checkbox"/>
4.	There are a minimum of voids.				
	Maxillary			<input type="checkbox"/>	<input type="checkbox"/>
	Mandibular			<input type="checkbox"/>	<input type="checkbox"/>

- 5. There are minimal areas in which the trays have contacted the tissues.

Maxillary

Mandibular

- 6. The posterior border of the maxillary impression accurately records the area in which the posterior palatal seal is to be established.

- 7. The impressions record the available supporting tissues.

Maxillary

Mandibular

OBJECTIVES

Knowledge. Upon completion of this Procedure, you will be able to:

1. State, for the maxillary final impression tray, the mandibular final impression tray, and the wax occlusal rim:
 - a. in sequential order, the steps in fabrication.
 - b. precautions to take at certain procedural steps in order to avoid potential difficulties.
 - c. the criteria for a clinically acceptable product.
2. From photographs of prepared products, identify criteria not met.
3. State the functions served by the wax occlusal rim on the mandibular final impression tray.

Skill. Upon completion of this Procedure you will be able to construct the following, meeting criteria specified on the criteria sheets:

1. An acrylic resin maxillary final impression tray.
2. An acrylic resin mandibular final impression tray.
3. A wax occlusal rim on the mandibular final impression tray.

Review. Impression making requires that the operator understand the relationship between the patient's oral anatomy, the structures available to support complete dentures and the outline form of a complete denture. It is extremely important to be able to read the diagnostic cast and see the anatomical structures and landmarks that will be supporting or covered by the complete denture bases. A review of the article by Kolb on the denture limiting structures is appropriate.

VIDEOTAPE

1. Custom Acrylic Resin Tray Construction.

MATERIALS NEEDED FOR PROCEDURE #2

Working casts of the maxillary and mandibular arches will be provided.

1. Bunsen burner.
2. Hanau torch.
3. #7 spatula.
4. 28 gauge pink relief wax.
5. Liquid foil substitute (Alu-cote, or Coe-sep).
6. Autopolymerizing acrylic resin.
7. Buffalo laboratory knife.
8. Arbor bands and chuck.
9. Kerr electro-torque handpiece.
10. Flame-shaped vulcanite bur.
11. Straight handpiece dentate revelation burs #701 SS White.
12. #4 straight handpiece round bur.
13. Pink baseplate wax.
14. Kerr acrylic resin roller and board.
15. Wax Hot Plate (Red Devil Spatula).

STEPS FOR FABRICATING AN ACRYLIC RESIN MAXILLARY FINAL IMPRESSION TRAY ON THE DIAGNOSTIC CAST

1. Because the preliminary impression was in alginate, which usually overextends the peripheries, you will need to draw a denture base outline for the final impression tray on the diagnostic cast, to provide maximum coverage of the basal seat area. The denture base outline is drawn just short of the sulcus depth as recorded on the diagnostic cast in both the labial and buccal areas bilaterally. Give careful attention to the frenula to provide adequate relief while maintaining the required denture base outline (Figures 1:9 and 1:10). Because the drawn outline on the diagnostic cast is an arbitrary determination of flange extensions and frenula reliefs, the impression tray will usually require some adjustment after a careful evaluation in the patient's mouth.
2. Draw a second line as a guide for the area of wax relief approximately 2-3 mms. short of the denture base outline you have established (Figures 1:11 and 1:12).

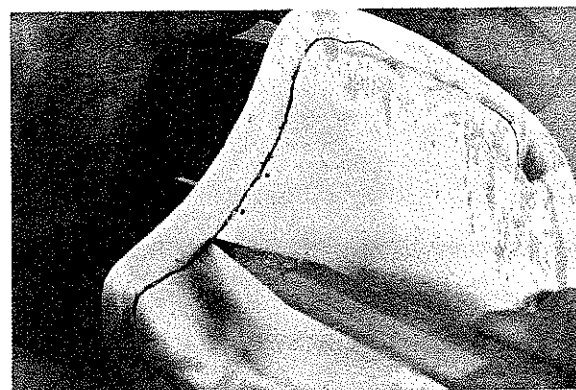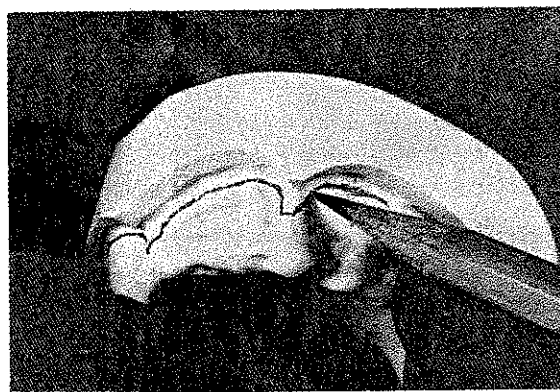
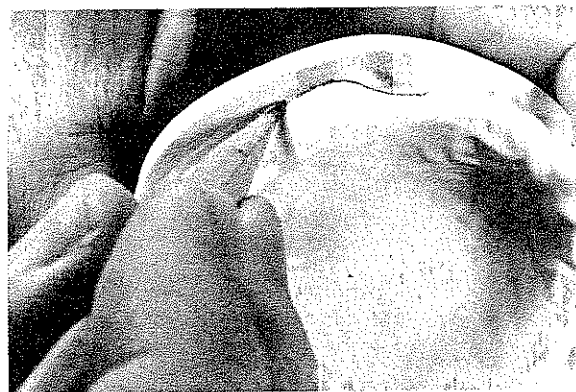
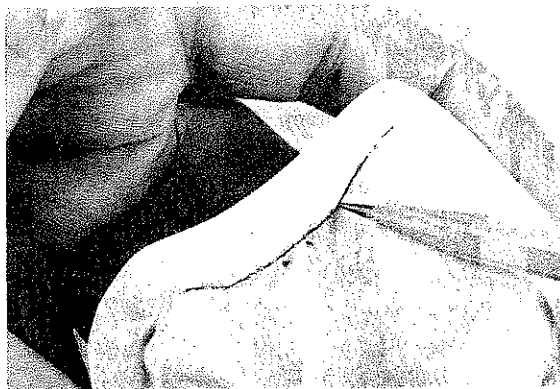


Figure 1:9. The Denture Base Outline for the Final Maxillary Impression Tray is Drawn on the Diagnostic Cast. Note the position of the line drawn for the labial and buccal frenula.

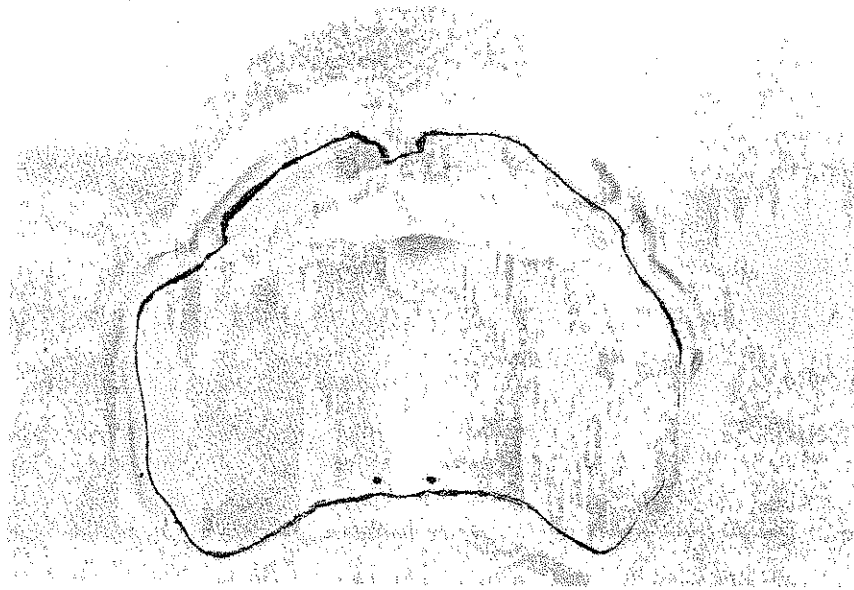

Figure 1:10. The Arbitrary Determination of the Flange Extensions Drawn on the Diagnostic Casts.

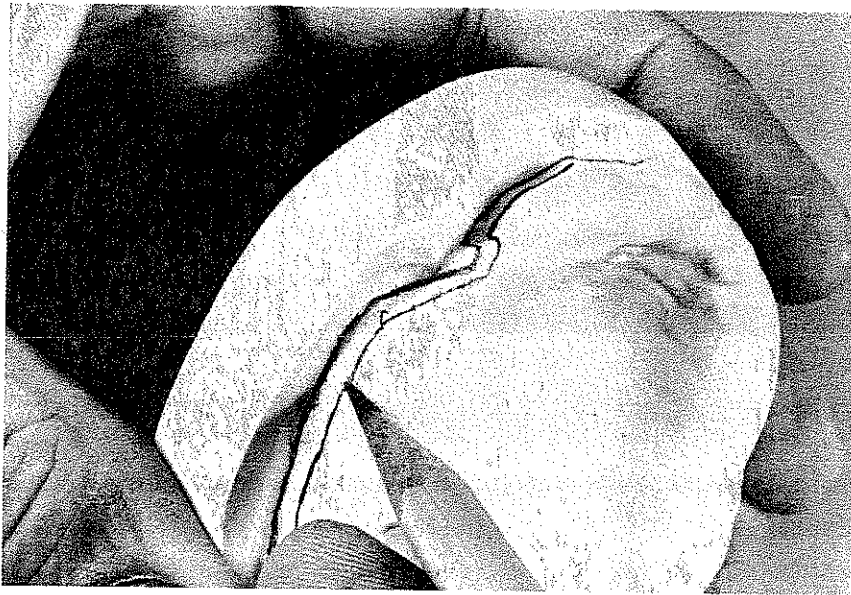


Figure 1:11. A Second Line is Drawn 2-3 mms. Short of the Denture Base Outline of the Maxillary Impression Tray Defining the Area of Wax Relief.

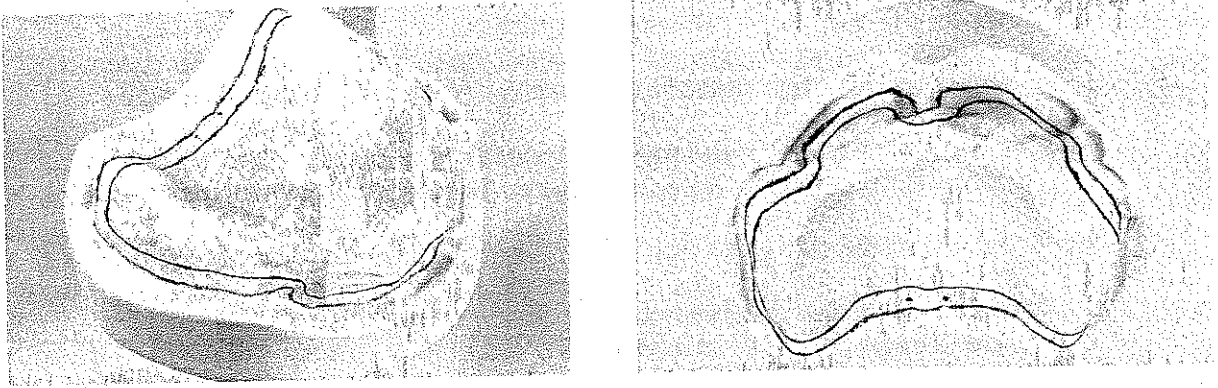


Figure 1:12. Note: The Area of the Wax Relief and Also the Relationship of the Drawn Line to the Foveae Palatinae.

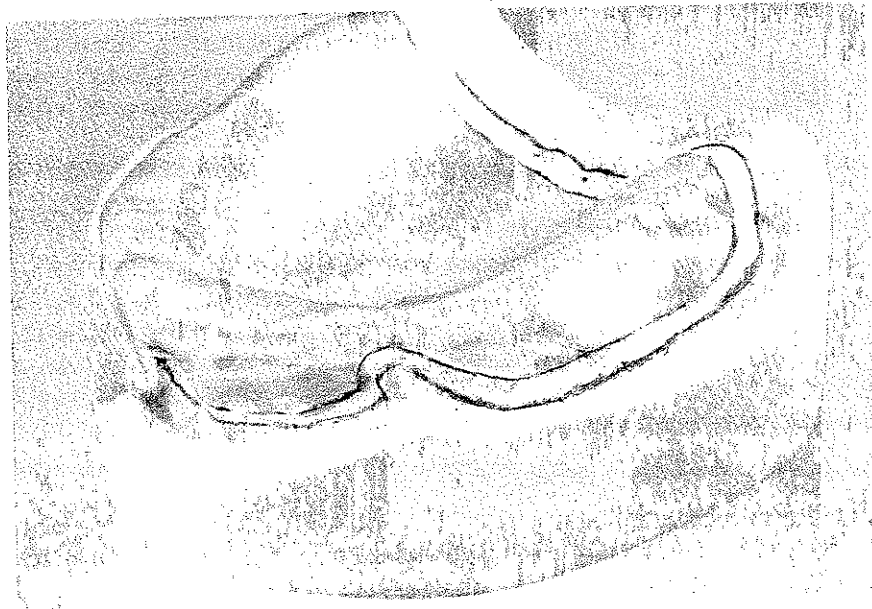


Figure 1:13. The Maxillary Diagnostic Cast with the 28 Gauge Pink Wax Relief in Place.

3. Warm one thickness of 28 gauge pink wax and adapt it over the denture base supporting area of the diagnostic cast. The model must be dry for easy adaptation. Minor wrinkles in the wax often cannot be avoided and when present are considered acceptable.
4. Trim the relief wax to the outline established as the area of relief (Figure 1:13).
5. Prepare a mixture of autopolymerizing acrylic resin, following the manufacturer's instructions for the liquid to powder ratio. Place the monomer (liquid) in a suitable mixing container and add the polymer (powder). Stir the mixture to wet the powder particles and allow it to sit.
6. Paint the diagnostic cast with the liquid foil substitute. Apply this separating medium to the surface of the stone model only, not to the surface of the wax. The liquid foil substitute enables easy separation of the impression tray from the diagnostic cast. The relief wax should be attached to the impression tray when you remove it from the cast. Should your relief wax separate from the impression tray and remain attached to the diagnostic cast, do not worry because the wax is to be removed during the final impression making procedures.
7. Lubricate the thick side of the roller board and the wooden roller with Vaseline.
8. Lubricate your fingers with Vaseline prior to handling the acrylic resin.
9. When the acrylic resin becomes doughy enough to handle, remove it from the mixing container, knead it and place it on the thick side of the roller board.
10. Roll the acrylic resin to a thickness of approximately 3 mms.
11. Carefully adapt the acrylic resin over the denture base outline on the diagnostic cast (Figure 1:14). Two very common errors are usually encountered at this stage in the fabrication of the impression tray. First, the acrylic resin is placed on the roller board before it has reached the proper consistency for manipulation, and second, the acrylic resin is rolled out too thin. Also, heavy finger pressure used during adaptation creates even thinner areas in the impression tray. This occurs most commonly in the areas of the labial and buccal flanges.
12. Trim the excess acrylic resin carefully, while it is still in the softened state. After trimming, readapt the flanges to the diagnostic cast.

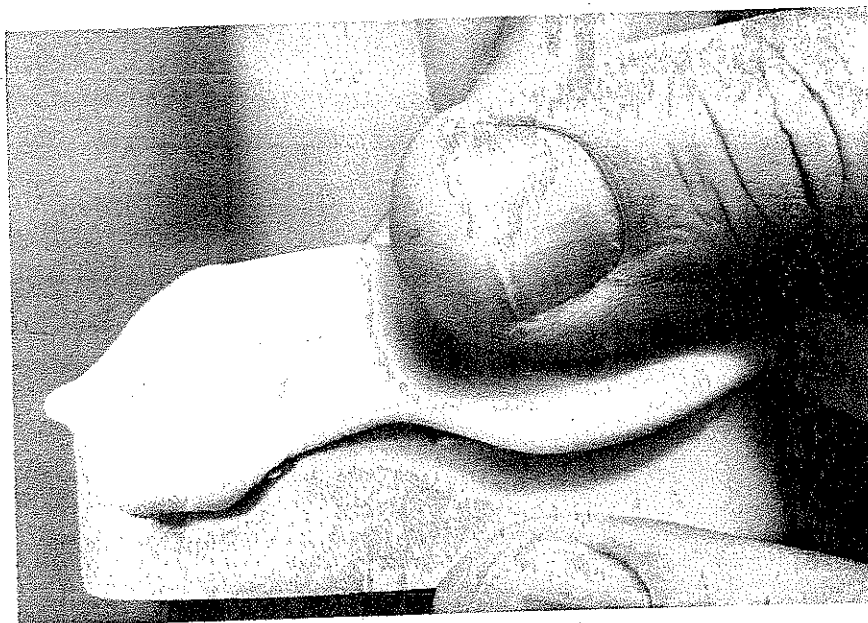


Figure 1:14. Adapting the Acrylic to the Maxillary Diagnostic Cast with Light Finger Pressure.

13. At this point you may set the maxillary tray aside and begin construction of the mandibular tray. Then you will return to step 14 in the maxillary tray construction while the mandibular tray is polymerizing. Complete polymerization of the maxillary impression tray usually is indicated when the tray is completely cool.
14. Remove the cured tray from the diagnostic cast and reduce any excess material or thickness with the arbor band on the dental lathe (Figure 1:15). Do not be concerned if the relief wax remains attached to the diagnostic cast. The borders of the tray should be rounded and smooth and follow the denture base outlined on the diagnostic cast. You may use vulcanite and fissure burs to trim and adjust the trays (Figure 1:16). Be sure to relieve the notch areas on the tray to accommodate the frenula.

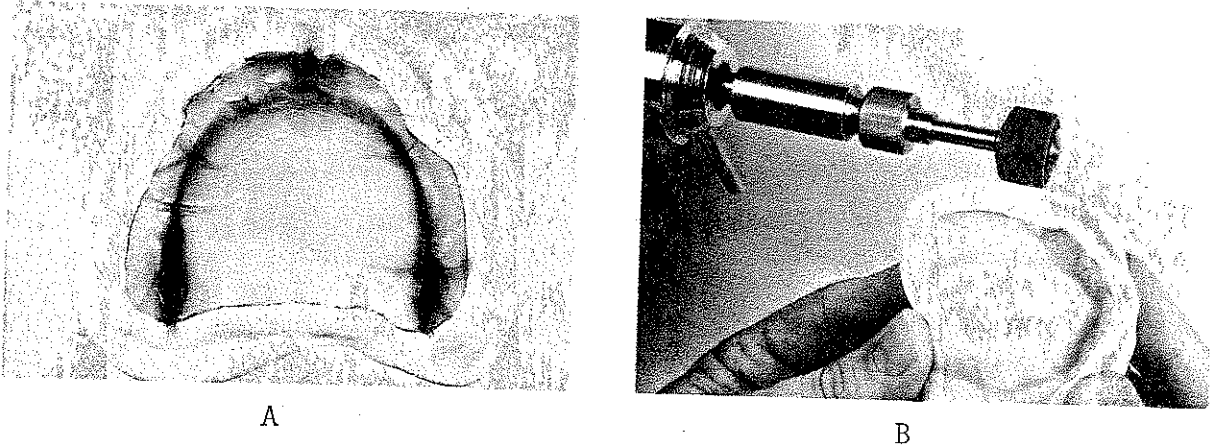


Figure 1:15. The Final Maxillary Impression Tray is A) Removed from the Diagnostic Cast, and B) Trimmed with an Arbor Band.

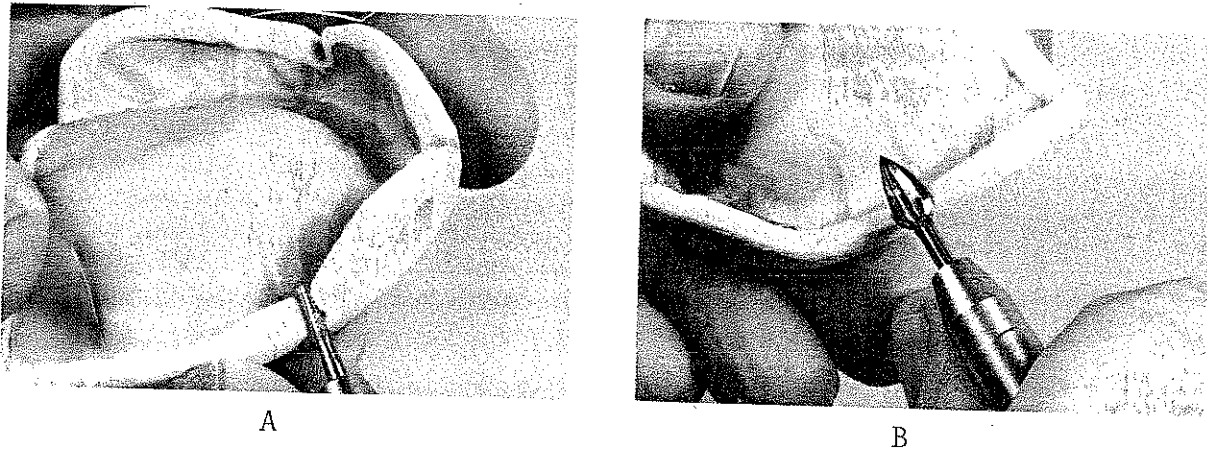


Figure 1:16. The Final Maxillary Impression Tray is Finished with A) Fissure Burs, and B) Vulcanite Burs.

15. Place evenly spaced holes made with a #4 straight handpiece round bur over the entire impression tray, particularly the flanges and palatal areas. Avoid placing the holes directly on the residual ridge crest areas. The purpose of the holes is to relieve pressure and to avoid distortion of the tissues by allowing for expression of the excess impression material when making the final impression (Figure 1:17).

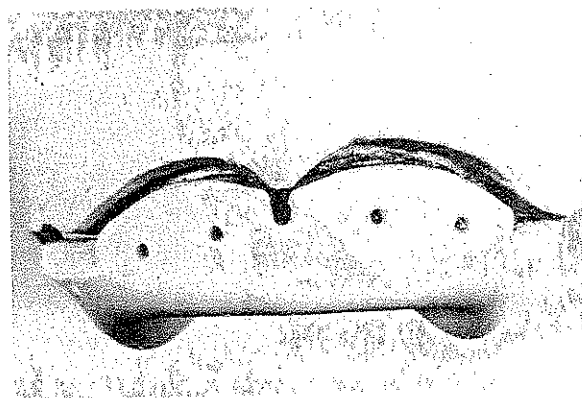
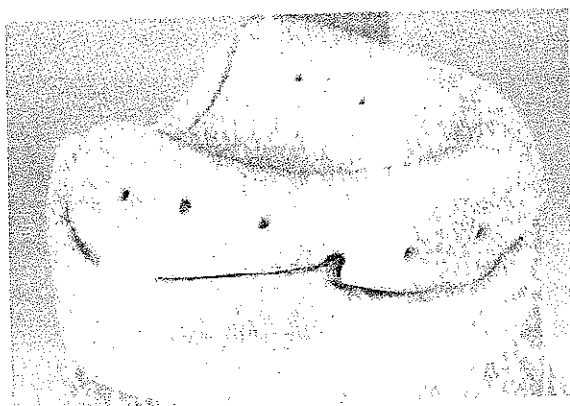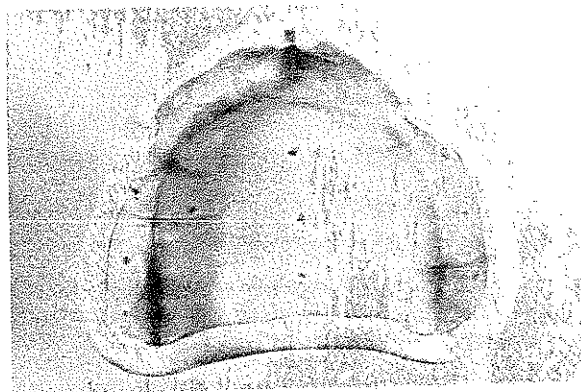
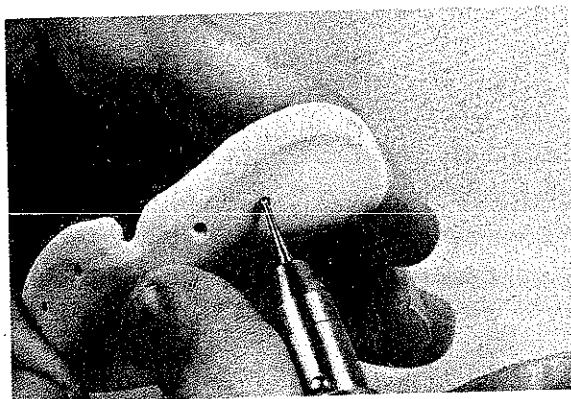


Figure 1:17. The Finished Final Maxillary Impression Tray. A #4 Straight Handpiece Bur is Used to Place Holes. Note: There are no Holes Directly on the Residual Ridge Crest.

STEPS FOR FABRICATING AN ACRYLIC RESIN MANDIBULAR FINAL IMPRESSION TRAY ON THE DIAGNOSTIC CAST

1. Draw the denture base outline for the final impression tray on the diagnostic cast as illustrated to provide maximum coverage of the basal seat area (Figure 1:18). Often it is difficult to read the diagnostic cast for the presence of the labial and buccal frenula. Therefore, it is appropriate arbitrarily to provide relief for them when constructing the impression tray. The impression tray notches may be further adjusted during evaluation in the patient's mouth by grinding or by addition of border molding compound.


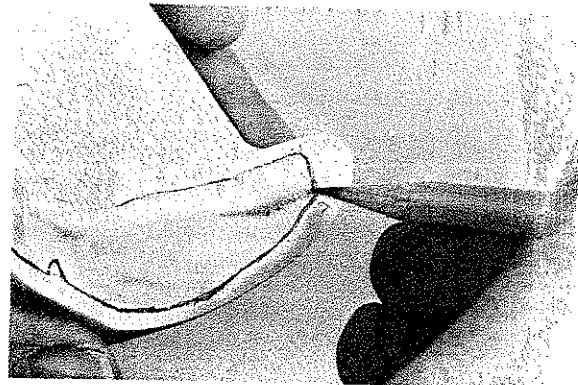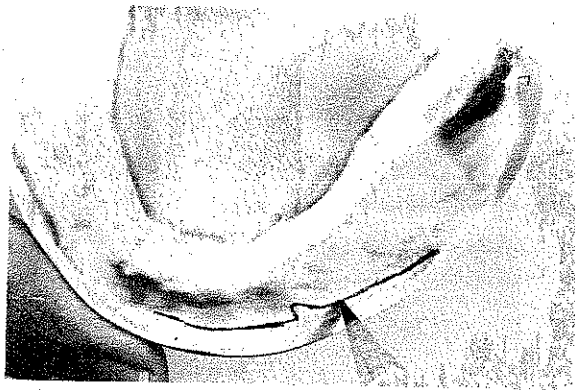


Figure 1:18. The Denture Base Outline for the Final Mandibular Impression Tray is Drawn on the Diagnostic Cast. Note the Position of the Buccal Notches on the Denture Base Outline Drawn for the Final Mandibular Impression Tray.

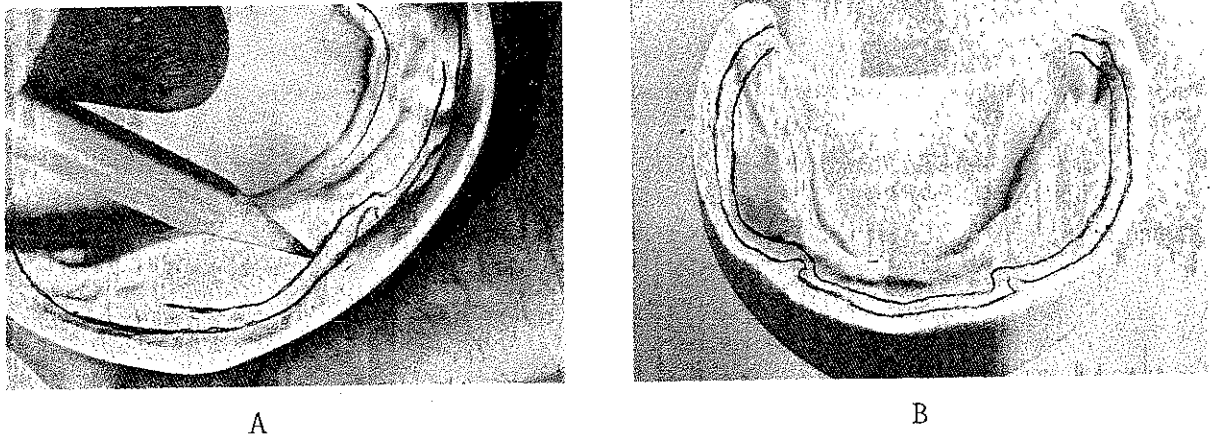


Figure 1:19. A) Second Line is Drawn 2-3 mm. Short of the Denture Base Outline of the Mandibular Impression Tray Defining, B) The Area of Wax Relief.

2. Draw a second line approximately 2-3 mms. short of the denture base outline as a guide for the area of wax relief (Figure 1:19).
3. Warm one thickness of 28 gauge pink wax and adapt it over the denture base outlined on the diagnostic cast.
4. Trim the relief wax to the outline established as the area of relief. If you make a slit in the relief wax in the middle of the tongue area it will help in adaptation. Minor folds in the relief wax are acceptable (Figure 1:20).
5. Prepare a mixture of the autopolymerizing acrylic resin following the manufacturer's instructions for the liquid to powder ratio. Place the monomer (liquid) in a mixing container and add the polymer (powder). Stir the mixture to wet the powder particles and allow it to sit.
6. Paint the diagnostic cast with the liquid foil substitute. Apply this separating medium to the surface of the stone model only, not to the surface of the relief wax.

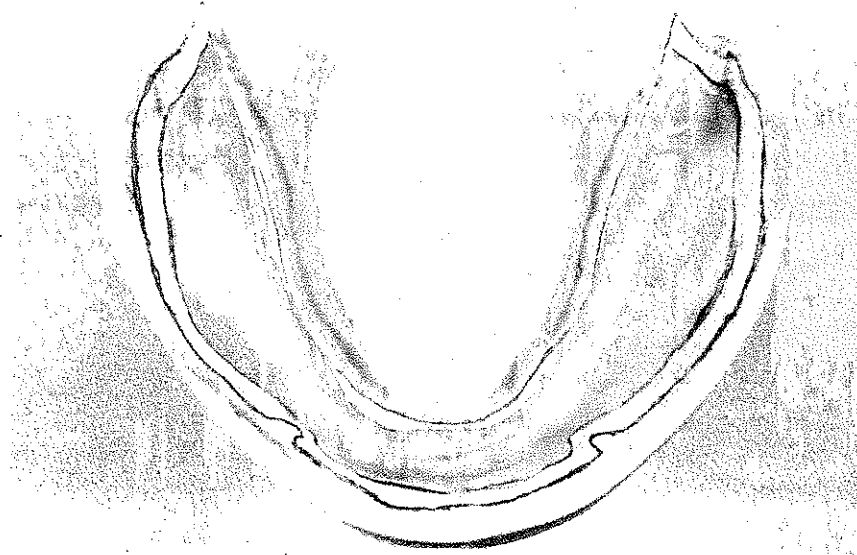

Figure 1:20. The Mandibular Diagnostic Cast with the 28 Gauge Pink Wax in Place.

7. Lubricate the thick side of the roller board and the wooden roller with Vaseline.
8. Lubricate your fingers with Vaseline prior to handling the acrylic resin. Remember to wait until the acrylic resin is of the proper consistency for rolling and adaptation. Do not apply too much pressure in adaptation, which would create thin areas.
9. When the acrylic resin becomes doughy enough to handle, remove the acrylic resin from the mixing container, knead it and place it on the thick side of the roller board.
10. Roll the acrylic resin to a thickness of approximately 3 mms.
11. Carefully adapt the acrylic resin over the denture base outline on the diagnostic cast (Figure 1:21). A minimal amount of handling will help to retain a uniform thickness.

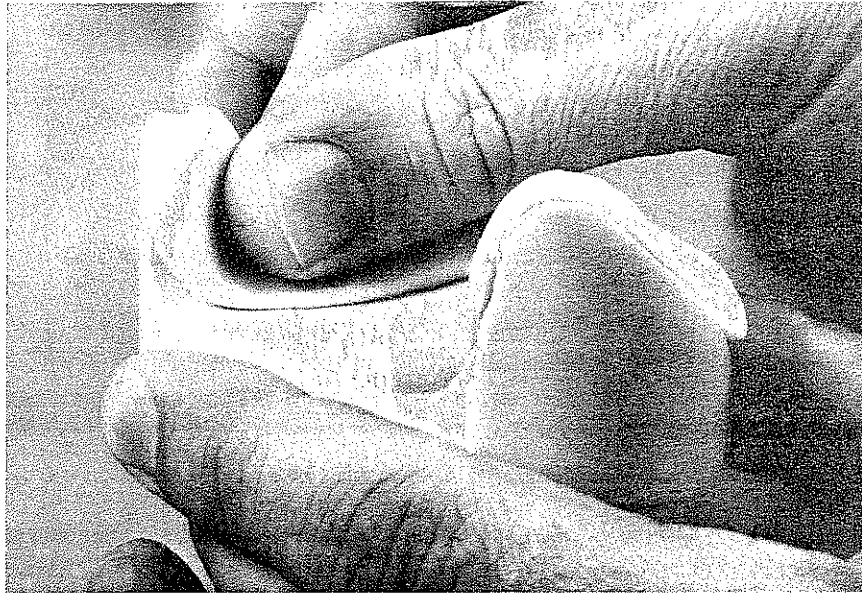
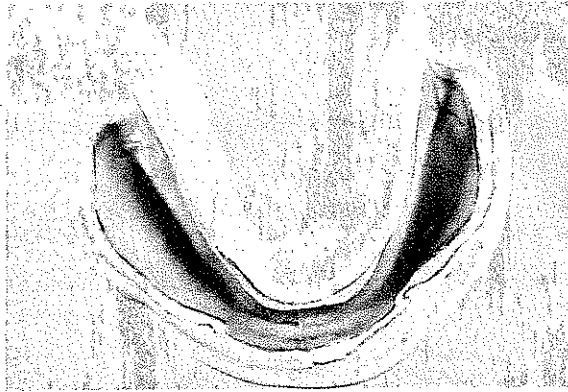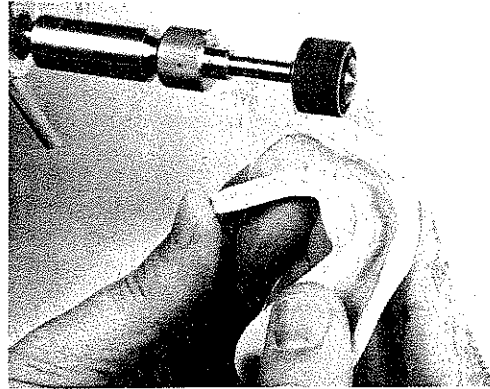


Figure 1:21. Adapting the Acrylic Resin to the Mandibular Diagnostic Cast with Light Finger Pressure.

12. Trim the excess acrylic resin carefully, while it is still in the softened state. Remember to readapt the flanges with light finger pressure.
13. Allow the impression tray to set until polymerization is complete, which is usually indicated when the tray is completely cool. (Return to Step 14 in the construction of the maxillary impression tray.)
14. Remove the cured tray and reduce any excess material or thickness with the arbor band on the dental lathe. The borders of the tray should be rounded and smooth and follow the denture base outline on the diagnostic cast (Figure 1:22). You may use the vulcanite and fissure burs to trim and adjust the tray. Be sure to relieve the notches on the tray. Again, you should take care to adjust the tray notches so that they are not too wide (Figure 1:23). Note: The relief holes are placed after the wax occlusal rim has been added to the mandibular tray.




A

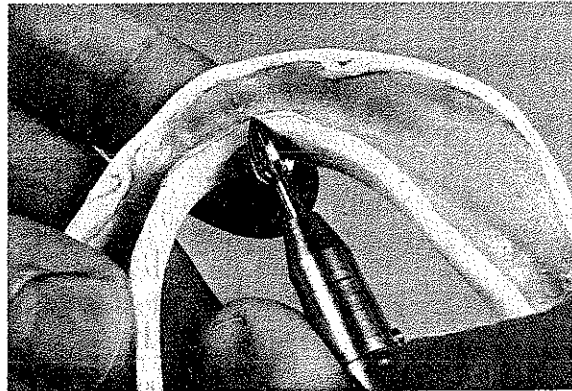


B

Figure 1:22. The Final Mandibular Impression Tray is A) Removed from the Diagnostic Cast, and B) Trimmed with an Arbor Band. Note: That the penciled lines have been transferred to the impression tray from the model.



A



B

Figure 1:23. The Final Mandibular Impression Tray is Finished with A) Fissure Burs, and B) Vulcanite Burs.

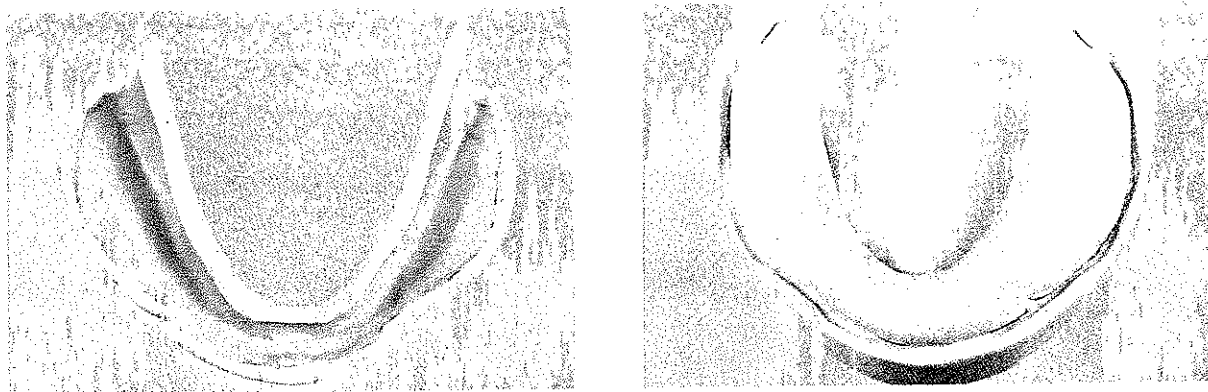


Figure 1:24. The Finished Final Mandibular Impression Tray Before the Wax Rim is Made.

WAX OCCLUSAL RIM ON THE MANDIBULAR IMPRESSION TRAY

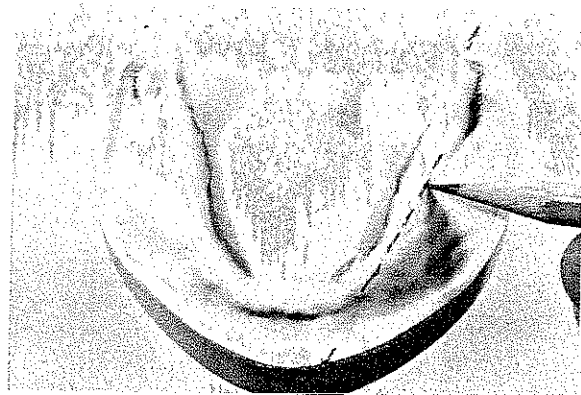The wax occlusal rim on the mandibular impression tray guides the patient's tongue to the "normal tongue position" during the making of the final impression. The rim also acts as a handle for the placement and removal of the tray in the patient's mouth.

Specific criteria must be met in order for the wax occlusal rim to be acceptable. These criteria relate to position, dimension, and finish of the wax occlusal rim. The most difficult of the criteria to satisfy is position. The following are some guidelines for you to follow in forming the mandibular wax occlusal rim and establishing its acceptable position on the impression tray.

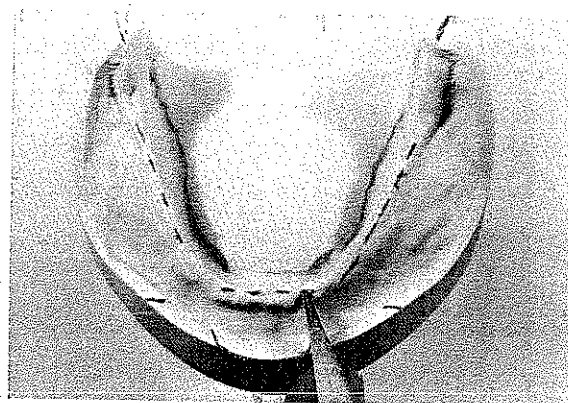
Place a line along the length of the mandibular residual ridge crest and extend this line onto the crest landing areas posterior to the top of the retromolar pad and anterior to the labial vestibule (Figure 1:25).

Place another line along the ridge crest in the anterior region extending onto the cast landing areas laterally. With the tray in position, these reference lines will help in centering the wax rim buccal-lingually on the residual ridge area of the impression tray (Figure 1:25).

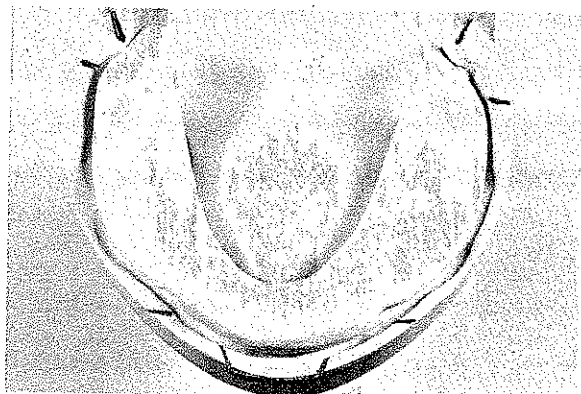Mark the top of the retromolar pad, drop down 1-2 mms. from this reference point, and extend another line laterally onto the cast landing areas (Figure 1:26).



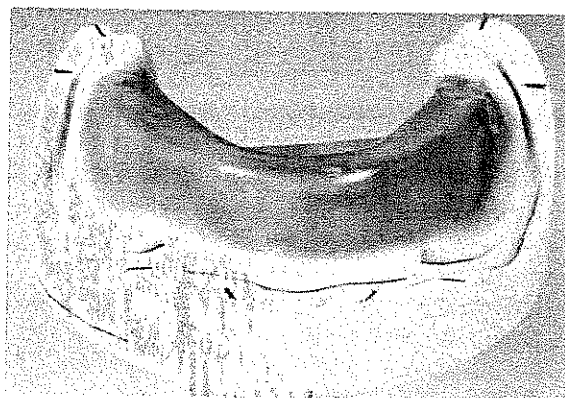A



B



C



D

Figure 1:25. A) A Line Drawn Lengthwise Along the Crest of the Residual Ridge and Extending to the Landing Areas of the Diagnostic Cast. B) A Line Drawn Along the Anterior Ridge Crest and Extended to the Landing Areas of the Diagnostic Cast. C) Impression Tray on Diagnostic Cast Showing Cast Reference Lines. D) Finished Wax Occlusal Rim on Diagnostic Cast Showing Reference Lines.

Mark yet another line on the base of the diagnostic cast that is parallel to the mean of the residual ridge (Figure 1:27). The line on the cast base and the line representing a point 1-2 mms. below the top of the retromolar pad will provide references to help position the wax occlusal rim parallel to the residual ridge when the impression tray is in position on the diagnostic cast.




Figure 1:26. A Line is Drawn 1-2 mms. Below the Top of the Retromolar Pad and Extended Onto the Landing Area.

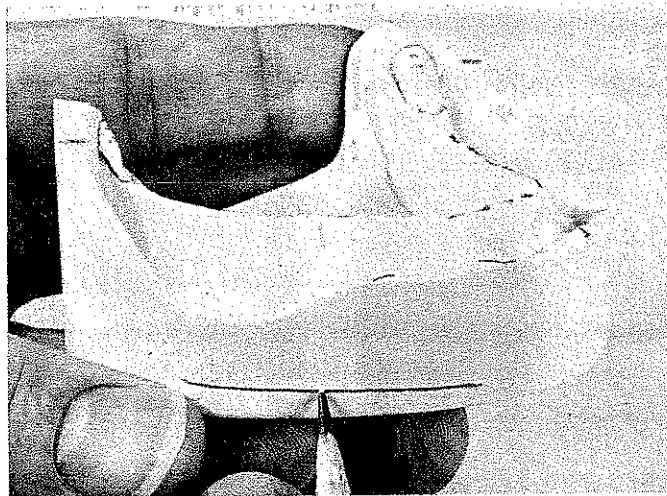


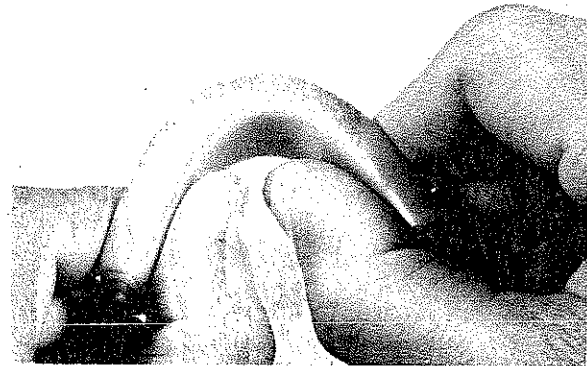
Figure 1:27. A Line is Drawn on the Base of the Diagnostic Cast Parallel to the Mean of the Residual Ridge.

STEPS FOR FABRICATING A WAX OCCLUSAL RIM ON THE MANDIBULAR IMPRESSION TRAY

1. Heat one sheet of baseplate wax and roll it to form the wax occlusal rim. The roll should simulate somewhat the final shape of the occlusal rim (Figure 1:28).
2. Apply sticky wax in several places along the crest of the ridge areas of the mandibular final impression tray and form and adapt the wax occlusal rim to the tray with your fingers in accordance with the previously presented guidelines (Figure 1:29).

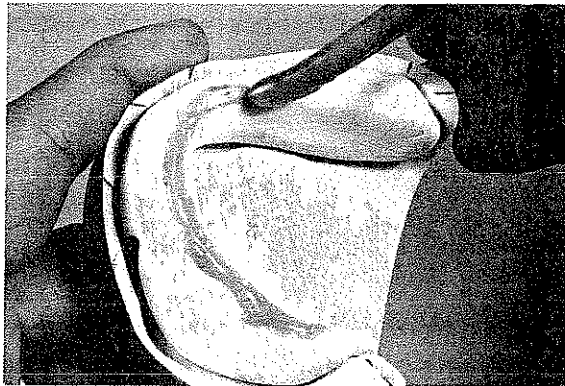


A

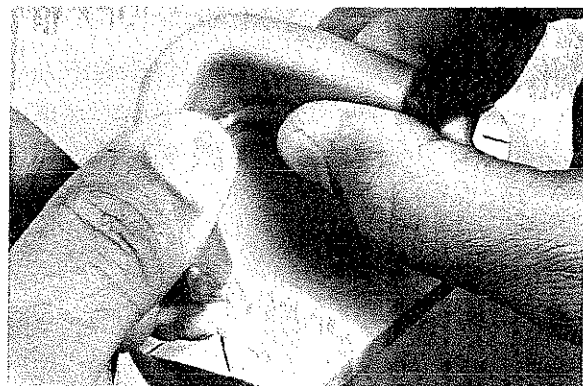


B

Figure 1:28. A Sheet of Baseplate Wax is A) Rolled on Itself, and B) Molded Into the Arch Form.



A



B

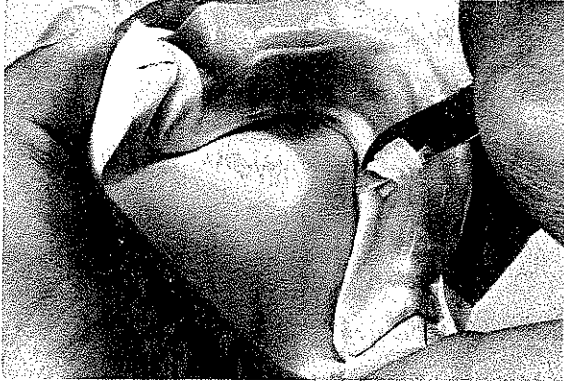Figure 1:29. A) Sticky Wax is Applied Along the Top of The Impression Tray and, B) The Occlusal Rim is Adapted.

3. Seal the wax rim to the impression tray with the hot end of a #7 spatula (Figure 1:30).
4. Modify the shape and finish of the wax occlusal rim to meet the criteria listed by carving with a laboratory knife and smoothing the surface with a hot #7 spatula.
5. The wax occlusal rim is centered buccal-lingually over the line drawn along the length of the residual ridge.



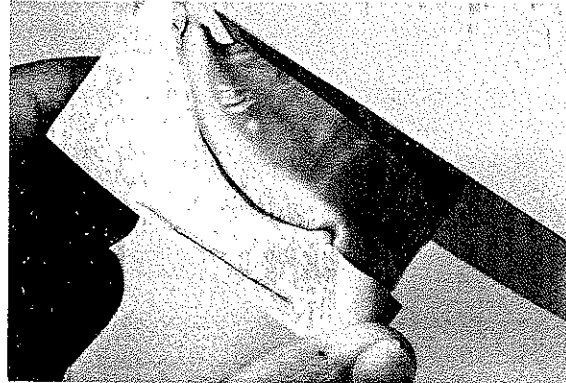


Figure 1:30. A Number Seven Spatula is Used to Seal the Occlusal Rim to the Mandibular Final Impression Tray.

6. Adjust the height of the wax occlusal rim until it is 1-2 mms. below the top of the retromolar pad and parallel to the mean of the mandibular residual ridge. This is done by melting away any excess wax with the red devil spatula. Heat the spatula and use it to make the occlusal surface smooth and flat by melting off some of the wax (Figure 1:31). Be sure to position the impression tray over a paper towel so that the wax will drip away.
7. Manipulate the wax rim to meet the following dimensions and shapes: The width in the posterior region is 10 mms. The width in the anterior region is slightly less, 7-10 mms. The occlusal surface of the wax rim is flat. The wax rim in the anterior region is labially oriented (Figure 1:32).



A



B

Figure 1:31. A) A Laboratory Knife is Used to Modify the Occlusal Rim on the Mandibular Final Impression Tray. B) Adjust Height of Occlusal Rim Until it is 1-2 mms. Below the Top of the Retromolar Pad Using the Warm Red Devil Spatula.

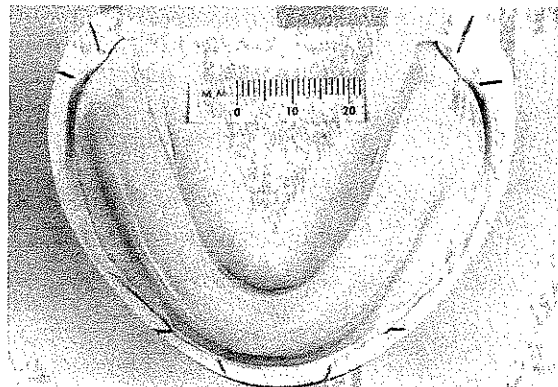
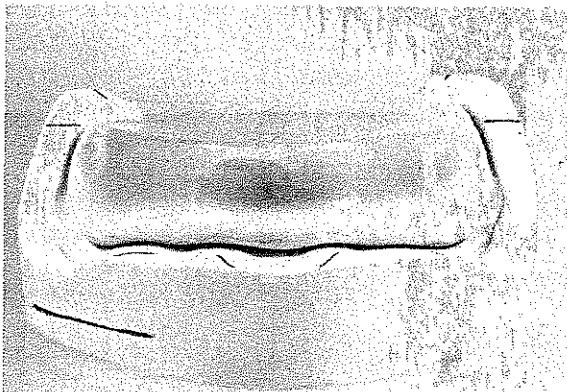


Figure 1:32. The Wax Rim is Manipulated to Fulfill the Established Criteria.

8. The final smooth finish of the wax rim can be accomplished by flaming the wax with the Hanau alcohol torch. Be sure to adjust the torch so that the flame is a brush flame and not a sharp point. When the tip of the torch flame is a point, the wax will melt rapidly and destroy what you have accomplished. The brush flame warms the wax and permits you to polish the wax with wet cotton (Figure 1:33).

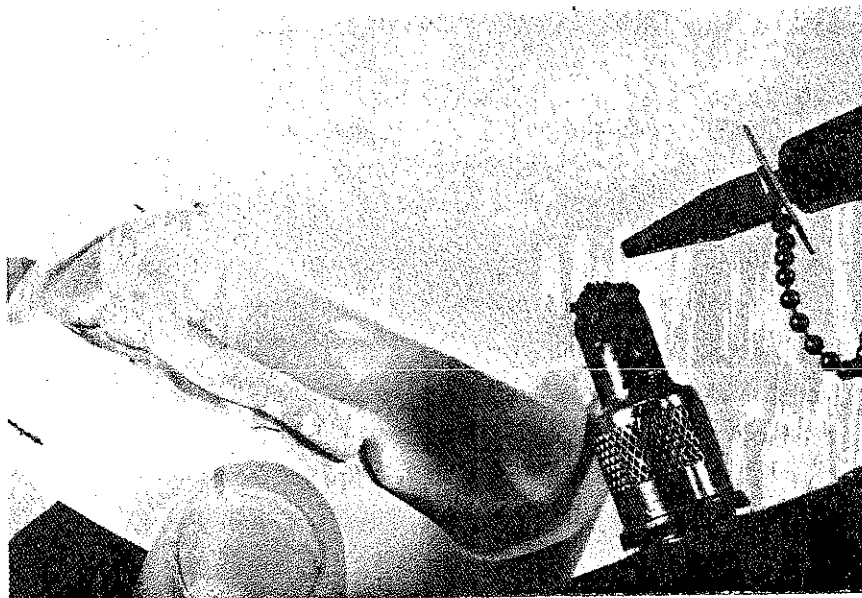


Figure 1:33. The Final Smooth Finish of the Wax is Accomplished Using the Hanau Alcohol Torch with the Flame Tip Adjusted to a Brush Flame, Not a Sharp Point.

9. Place approximately twelve holes throughout the acrylic resin tray with the #4 straight handpiece round bur. Space the holes evenly and place them so that they do not interfere with the wax occlusal rim (Figure 1:34).

Evaluate your product using the criteria sheet and then
CHECK WITH AN INSTRUCTOR.

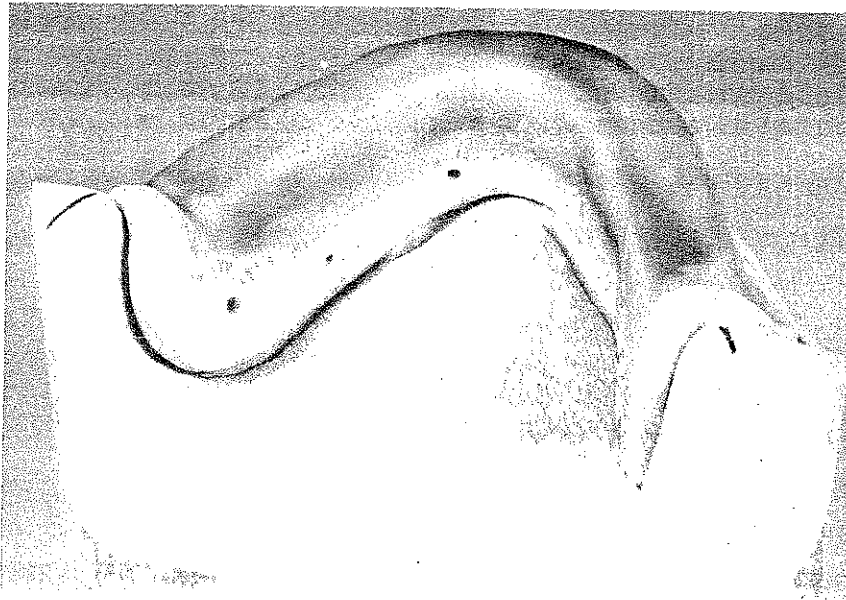
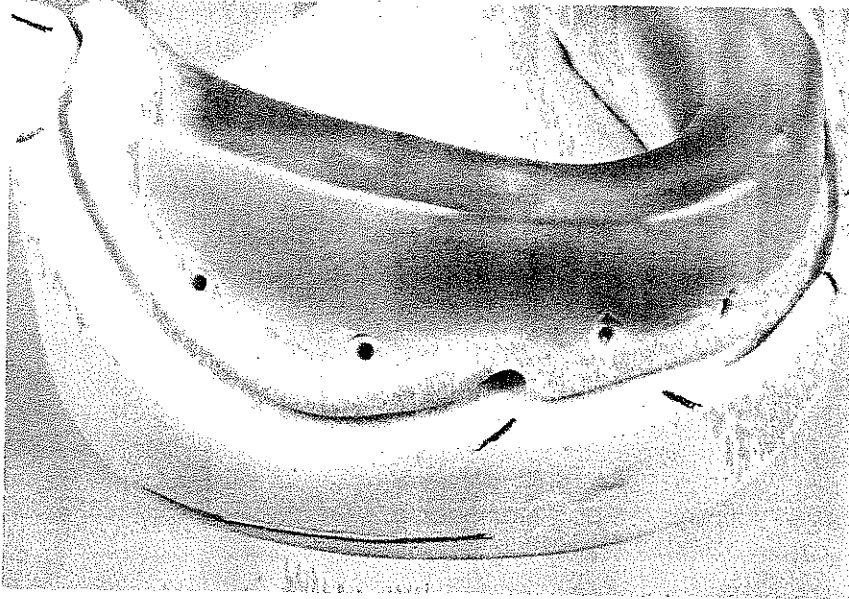


Figure 1:34. Holes are Spaced Evenly Throughout the Acrylic Resin Tray with a #4 Straight Handpiece Round Bur.

CRITERIA - ACRYLIC RESIN MAXILLARY IMPRESSION TRAY

Evaluate your product using the criteria listed and check the appropriate boxes. After filling in the boxes, take your product and this Study Guide to an instructor for evaluation.

<u>Maxillary Impression Trays</u>	<u>Meets Criteria</u>	<u>Does not meet Criteria</u>	<u>Comments</u>
1. The acrylic resin tray extends to the denture base outline on the diagnostic cast.	<input type="checkbox"/>	<input type="checkbox"/>	
2. The acrylic resin impression tray is uniformly about 3 mms. in thickness.	<input type="checkbox"/>	<input type="checkbox"/>	
3. The relief wax extends to 2-3 mms. inside the denture base outline.	<input type="checkbox"/>	<input type="checkbox"/>	
4. The borders of the tray are rounded.	<input type="checkbox"/>	<input type="checkbox"/>	
5. Holes are evenly spaced.	<input type="checkbox"/>	<input type="checkbox"/>	
6. The notches are <u>not</u> excessively relieved.			
Labial	<input type="checkbox"/>	<input type="checkbox"/>	
Buccal Right	<input type="checkbox"/>	<input type="checkbox"/>	
Left	<input type="checkbox"/>	<input type="checkbox"/>	

CRITERIA - ACRYLIC RESIN MANDIBULAR IMPRESSION
TRAY AND WAX OCCLUSAL RIM

Evaluate your product using the criteria listed and check the appropriate boxes. After filling in the boxes, take your product and this Study Guide to an instructor for evaluation.

<u>Mandibular Impression Tray</u>	<u>Meets Criteria</u>	<u>Does not meet Criteria</u>	<u>Comments</u>
1. Acrylic resin tray extends to the denture base outline on the diagnostic cast.	<input type="checkbox"/>	<input type="checkbox"/>	
2. Acrylic resin impression tray is uniformly about 3 mms. in thickness.	<input type="checkbox"/>	<input type="checkbox"/>	
3. Relief wax extends to 2-3 mms. inside the denture base outline on the diagnostic cast.	<input type="checkbox"/>	<input type="checkbox"/>	
4. The borders of the tray are rounded.	<input type="checkbox"/>	<input type="checkbox"/>	
5. Approximately 12 holes, evenly spaced around the lingual and buccal peripheries and not covered by the wax occlusal rim.	<input type="checkbox"/>	<input type="checkbox"/>	
<u>Mandibular Wax Occlusal Rim</u>			
<u>Position</u>			
1. Centered buccal-lingually over the line drawn along the length of the residual ridge.	<input type="checkbox"/>	<input type="checkbox"/>	
2. 1-2 mms. below the top of the retromolar pad.	<input type="checkbox"/>	<input type="checkbox"/>	
3. Parallel to the mean of the residual ridge.	<input type="checkbox"/>	<input type="checkbox"/>	
4. Labially oriented.	<input type="checkbox"/>	<input type="checkbox"/>	

<u>Dimension</u>	<u>Meets Criteria</u>	<u>Does not meet Criteria</u>	<u>Comments</u>
1. Width of rim in posterior region approximately 10 mms.	<input type="checkbox"/>	<input type="checkbox"/>	
2. Width in anterior region 7-10 mms. (slightly less than in posterior region).	<input type="checkbox"/>	<input type="checkbox"/>	
3. Flat occlusal surface.	<input type="checkbox"/>	<input type="checkbox"/>	
<u>Finish</u>			
1. Wax is sealed to the tray.	<input type="checkbox"/>	<input type="checkbox"/>	
2. No voids in the wax.	<input type="checkbox"/>	<input type="checkbox"/>	
3. The wax surface is smooth.	<input type="checkbox"/>	<input type="checkbox"/>	

PRACTICAL SKILL EXAMINATION #1

OBJECTIVES

To determine if each student is able:

1. To construct an acrylic resin mandibular final impression tray for an edentulous arch.
2. Add a wax occlusal rim to the mandibular final impression tray.
3. Time limit 1 1/2 hours.

STEPS IN THE EXAMINATION

1. You will construct a mandibular acrylic resin impression tray on a diagnostic cast. You will add a wax occlusal rim on the tray.
2. When you have completed the examination, place your honor code number and the date on the base of the diagnostic cast and the impression tray. Turn in the impression tray and cast at the designated area.
3. The impression tray will be evaluated using the criteria listed.

CRITERIA FOR EXAMINATION AND EVALUATION

Mandibular Impression Tray. Each of the criteria listed can receive one point for a total of five points.

1. The acrylic resin tray extends to the denture base outline on the diagnostic cast.
2. The acrylic resin impression tray is uniformly about 3 mms. in thickness.
3. Relief wax extends 2-3 mms. inside the outline of the denture base.
4. The borders of the tray are rounded.
5. Approximately twelve holes made by a #4 straight hand-piece round bur are evenly spaced around the lingual and buccal peripheries and are not covered by the wax occlusal rim.

Mandibular Wax Occlusal Rim. Each of the criteria listed can receive one point for a total of 10 points:

Position

1. Centered buccal-lingually over the line drawn along the length of the residual ridge.
2. 1-2 mms. below the top of the retromolar pad.

3. Parallel to the mean of the residual ridge.
4. Labially oriented.

Dimension

1. Width of the rim in the posterior region is 10 mms..
2. Width in the anterior region is 7-10 mms., slightly less than in the posterior region.
3. The occlusal surface is flat.

Finish

1. The wax is sealed to the impression tray.
2. No voids are present in the wax.
3. The wax surface is smooth.

SELF TEST 1
ACRYLIC RESIN FINAL IMPRESSION TRAYS AND WAX OCCLUSAL RIMS

(Circle correct response(s) or write brief answers. For correct answers, consult the Answer Key.)

1. Acrylic resin is set sufficiently for rolling when it is:
 - a. Sticky.
 - b. Doughy.
 - c. Sandy.
 - d. Stiff.

2. The major flaw(s) in the acrylic resin maxillary impression tray that is illustrated in Figure T1:1 is (are):
 - a. Flange thickness is insufficient.
 - b. Lacks sufficient holes.
 - c. Borders are sharp.
 - d. Lacks adequate relief for labial frenum.

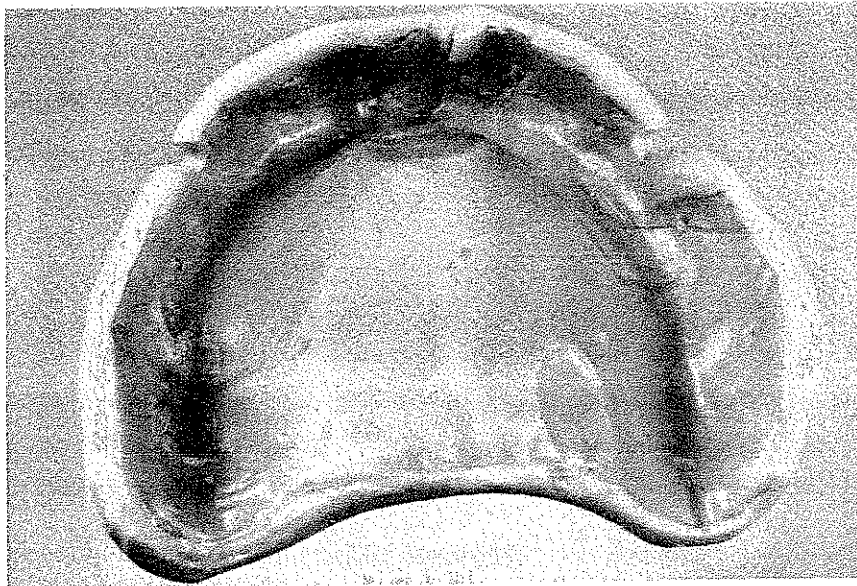


Figure T1:1

3. The proper extension of the acrylic resin final impression tray is: (Circle all that apply)
 - a. To the peripheral limits of the diagnostic cast in order to capture all of the available anatomy in the final impression.
 - b. Arbitrarily short of the peripheral limits of the diagnostic cast to allow for border molding.
 - c. To the junction of the movable and immovable oral mucosa.
 - d. To and including some of the landing area to assure proper thickness and roll to the final impression.

4. The major flaw(s) in the acrylic resin maxillary impression tray that is illustrated in Figure T1:2 is (are):
 - a. Flange thickness is insufficient.
 - b. Flanges are overextended and include the landing area.
 - c. Lacks adequate relief for frenula.
 - d. Buccal notch is excessively relieved.

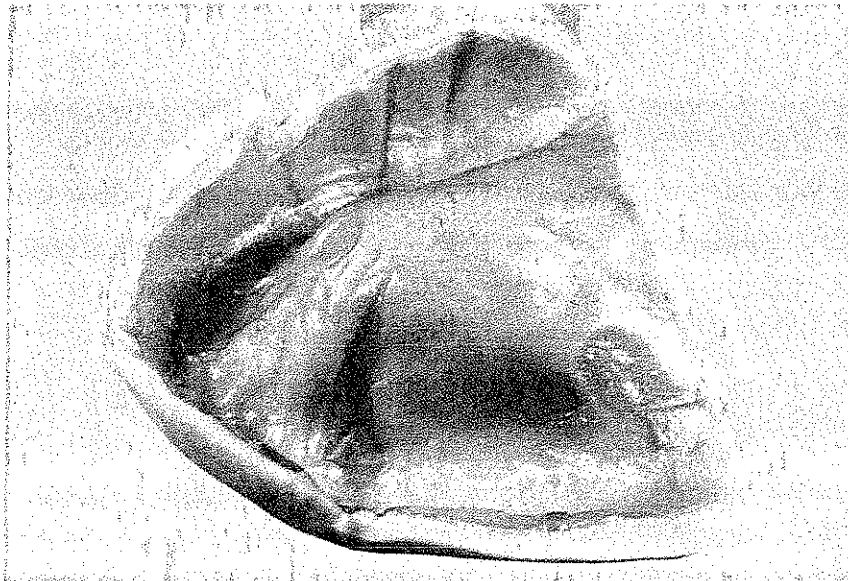


Figure T1:2

5. Removal of the impression tray from the diagnostic cast is facilitated by: (Circle all that apply)
- a. The use of a liquid foil substitute on the diagnostic cast.
 - b. The acrylic resin handle.
 - c. The relief wax extending to the peripheral limits of the diagnostic cast.
 - d. The several strategically placed pressure relief holes.
6. The major flaw(s) in the acrylic resin maxillary impression tray that is illustrated in Figure T1:3 is (are):
- a. Flange thickness is insufficient.
 - b. Flanges are overextended and include the landing area.
 - c. Lacks adequate relief for frenula.
 - d. Buccal notch is excessively relieved.

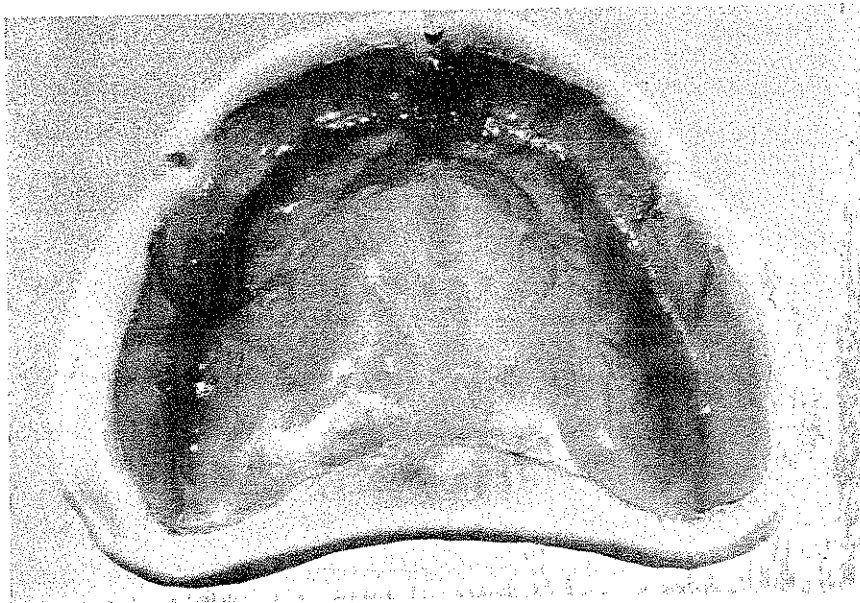


Figure T1:3

7. The function(s) of the wax occlusal rim on the mandibular acrylic resin impression tray is (are): (Circle all that apply)
- a. Acts as a handle for placement and removal of the impression tray.
 - b. Maintains the patient's vertical dimension.
 - c. Keeps the patient's tongue in the normal tongue position during the making of the final impression.
 - d. Maintains occlusion for the final impression.
8. The major flaw(s) in the acrylic resin mandibular impression tray that is illustrated in Figure T1:4 is (are):
- a. Is overextended.
 - b. Is underextended.
 - c. Lacks sufficient holes.
 - d. Flanges too thin.

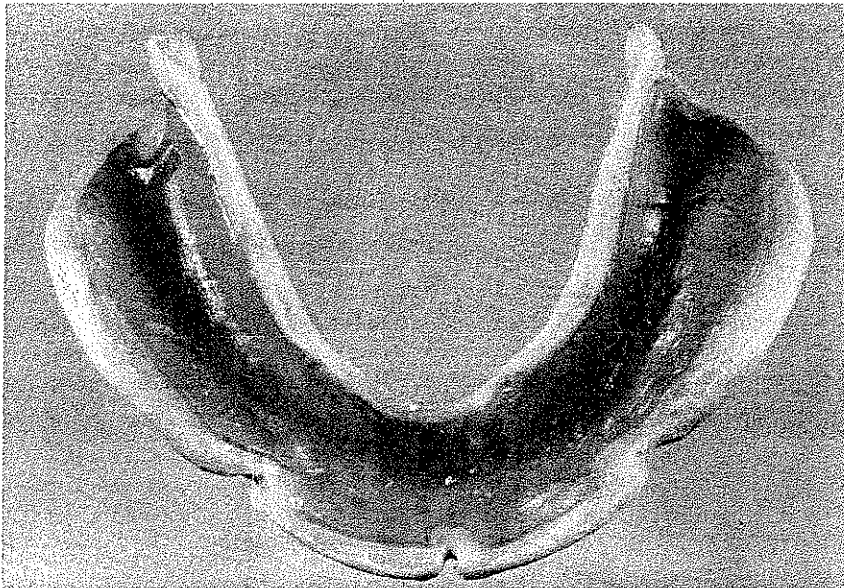


Figure T1:4

9. The criteria for the dimensions of the wax occlusal rim on the mandibular final impression tray are: (Circle all that apply)
- a. Width in posterior region 10 mms.
 - b. Width in anterior region 7-10 mms.
 - c. Flat occlusal surface.
 - d. Tapered for ease in grasping.
10. The major flaw(s) in the acrylic resin mandibular impression tray that is illustrated in Figure T1:5 is (are):
- a. Is overextended.
 - b. Is underextended.
 - c. Lacks sufficient holes.
 - d. Relief wax is absent.

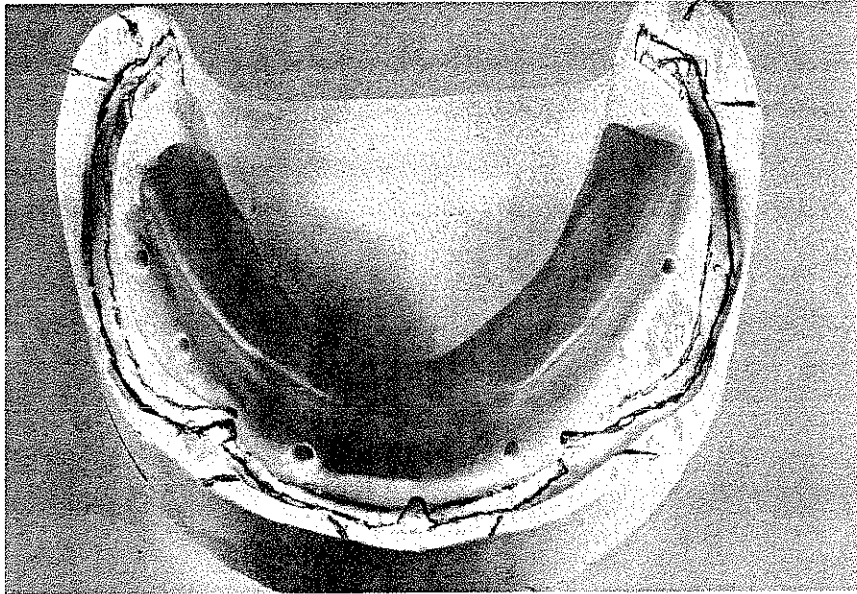


Figure T1:5

11. Excess acrylic resin: (Circle all that apply)
- a. May be trimmed while still soft.
 - b. May be trimmed after polymerization is complete, with an acrylic bur.
 - c. May be reduced after polymerization by the arbor band on the dental lathe.
 - d. May be trimmed with the Craytex wheel.
12. The major flaw(s) in the mandibular impression tray and wax occlusal rim illustrated in Figure T1:6 is (are):
- a. Is not labially oriented.
 - b. Is too high in relation to the retromolar pad.
 - c. Has void(s).
 - d. Inadequate frenum relief.




Figure T1:6

13. The major flaw(s) in the wax occlusal rim on the tray shown in Figure T1:7 is (are):
- Is not centered buccal-lingually over the line drawn along the length of the residual ridge.
 - Is not the correct width in the anterior portion.
 - Is not the correct width in the posterior portion.
 - The finish is inadequate.

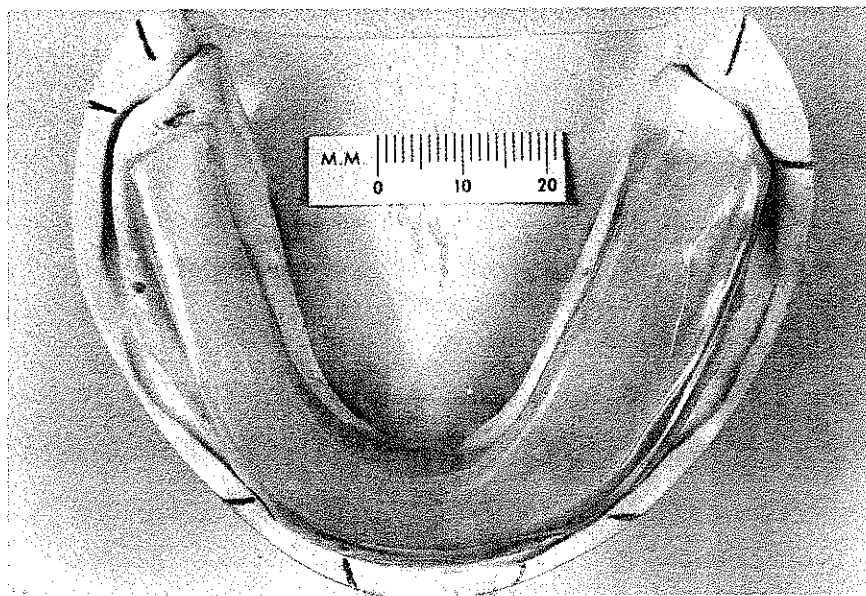


Figure T1:7

14. The major flaw(s) in the wax occlusal rim on the tray shown in Figure T1:8 is (are):
- a. Is too high in relation to the retromolar pad.
 - b. Is too low in the anterior region.
 - c. Has void(s).
 - d. The wax finish and contour at the junction with the tray is inadequate.

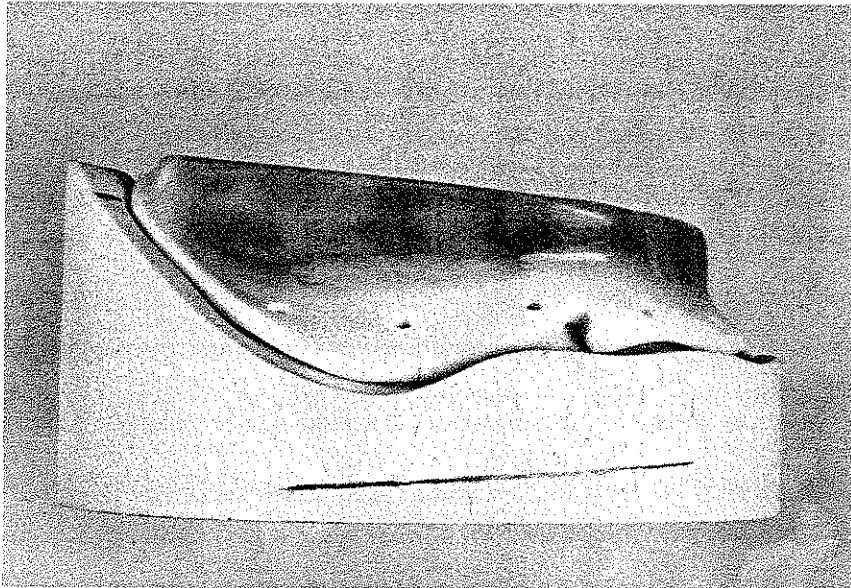


Figure T1:8

OBJECTIVES

Knowledge. Upon completion of this Procedure, you will be able to:

1. Describe border molding and its clinical significance.
2. State, for the maxillary final impression and for the mandibular final impression:
 - a. In sequential order, the steps in fabrication.
 - b. The precautions to take at certain procedural steps in order to avoid potential difficulties.
 - c. The criteria for a clinically acceptable product.

Skill. Although you will not perform these procedures in the Preclinical course, you should know how they are done in order to better understand their significance in the overall management of the complete denture patient.

VIDEOTAPES

1. Final Maxillary Impression.
2. Final Mandibular Impression.

MATERIALS NEEDED FOR PROCEDURE #3

1. Acrylic resin maxillary and mandibular final impression trays with wax occlusal rims.
2. Rubber base adhesive (Kerr Manufacturing Co.).
3. Rubber base impression material (Kerr Manufacturing Co.), or zinc oxide eugenol impression paste (Coe-Mfg. Co.).
4. Mixing pad and spatula.
5. Kerr dental compound (sticks).
6. Bunsen burner.
7. Hanau torch and alcohol (methanol).
8. #7 spatula.
9. Compound heater.
10. Thermometer for compound heater.
11. Red handled knife and #25 blade.
12. Kerr mouth mirror #5.
13. Gauze.
14. Oil of orange or other suitable solvent.

STEPS IN BORDER MOLDING THE ACRYLIC RESIN MAXILLARY FINAL
IMPRESSION TRAY

1. Seat the patient in an upright position to gain maximum control of the impression materials.
2. Fit the maxillary final impression tray over the residual ridge area and check the flange extensions (Figure 1:35). If the flanges are underextended, you will extend them with dental compound by using the border molding method. If the flanges are overextended, you must shorten them. In general, it is better to shorten the flanges even though they may appear to be at the appropriate length. The operator can reestablish the length and also the width of the peripheral roll of the flanges using border molding procedures with dental compound.

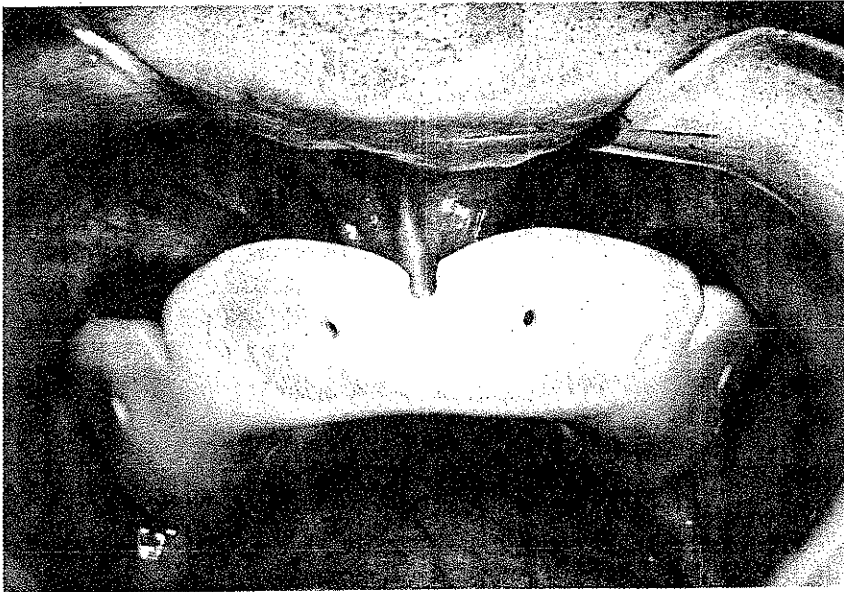


Figure 1:35. The Maxillary Final Impression Tray is Positioned in the Patient's Mouth and Evaluated.

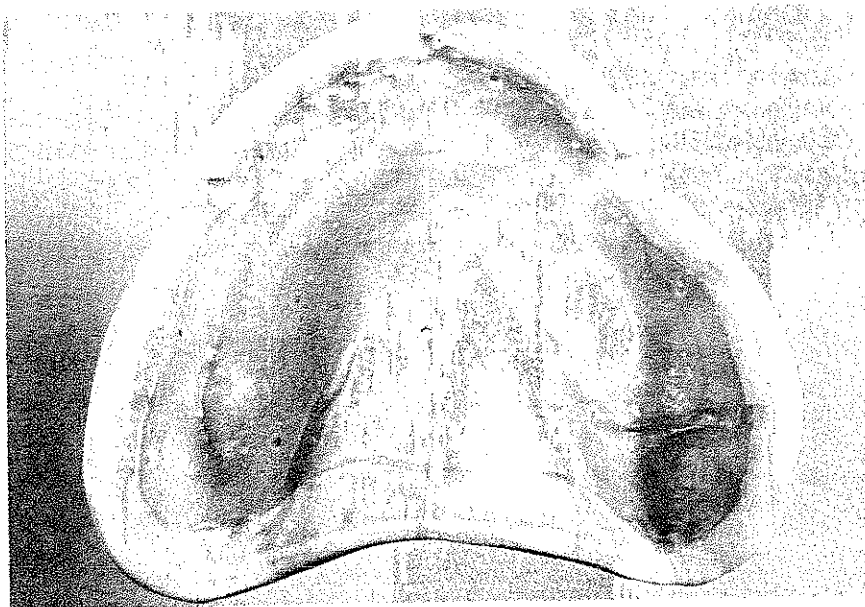

Figure 1:36. Some of the Relief Wax is Removed from the Tray Border to Facilitate Attachment of the Dental Compound.

Before applying the compound, remove some of the relief wax so that the dental compound can be applied to the acrylic resin flange edges without the heated compound and wax joining together (Figure 1:36).

3. Soften a small segment of the end of the stick compound in the bunsen burner. With a twisting motion, apply the softened compound in a stretched-out strip along the outer edge of the flange. Apply it in small segments, to one quadrant at a time, using a small amount of compound. Do not overheat the compound. Seal the compound to the acrylic resin flange with a hot #7 spatula.
4. Adjust the Hanau torch to produce a brush flame, not a point. To create this brush flame, open the air valve wide and then close it one turn. Depress the plunger 2 or 3 times to check the flame and adjust it further if needed.

Caution: Hot compound burns dry fingers, and will also burn the patient's oral tissues if not handled properly. After the compound is added to the impression tray and heated, it is ALWAYS TEMPERED by placing the impression tray into a water bath at 135°F. a few moments before inserting it into the patient's mouth.

5. Gently heat the compound addition with the brush flame of the alcohol torch, temper it, and form the flange extension with fingers moistened in water. Re-flame lightly, temper, and then gently seat the tray over the tissues in the patient's mouth. Hold in place a short length of time until the compound cools.
6. Remove and inspect the flanges. Trim the excess compound to the acceptable flange length using a sharp red-handled knife. Re-flame, temper, and again gently seat the tray over the tissues. Remove the tray and inspect the compound addition (Figure 1:37).

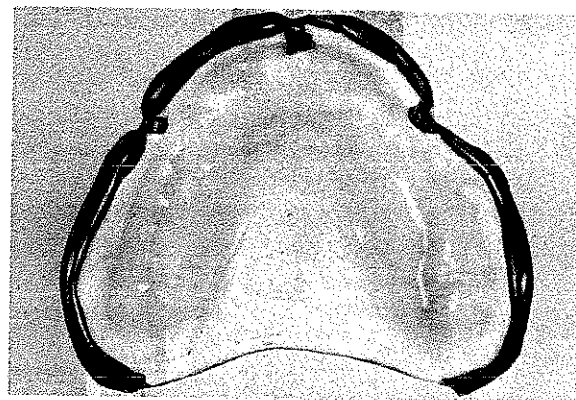
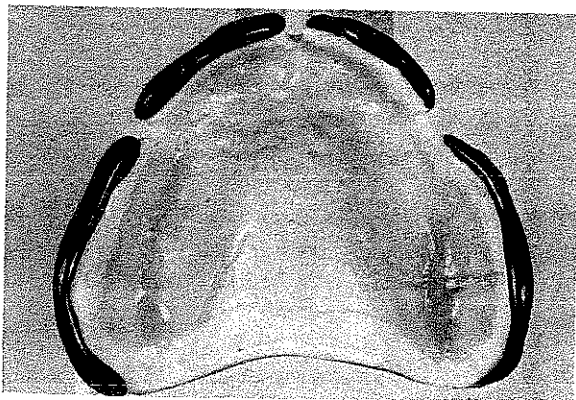
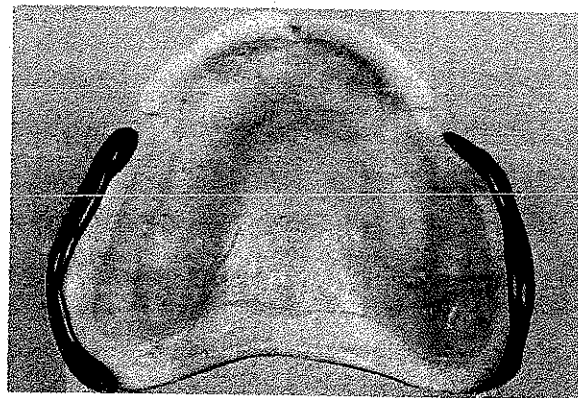
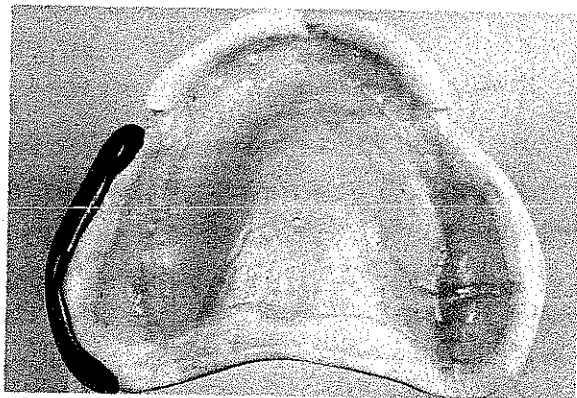


Figure 1:37. The Maxillary Final Impression Tray is Border Molded in Segments with Dental Compound.

7. When the flanges have been restored to an acceptable length and width, the notches should be formed with compound (Figure 1:37). All compound additives are then carefully inspected in the patient's mouth for form and adaptation (Figure 1:38).

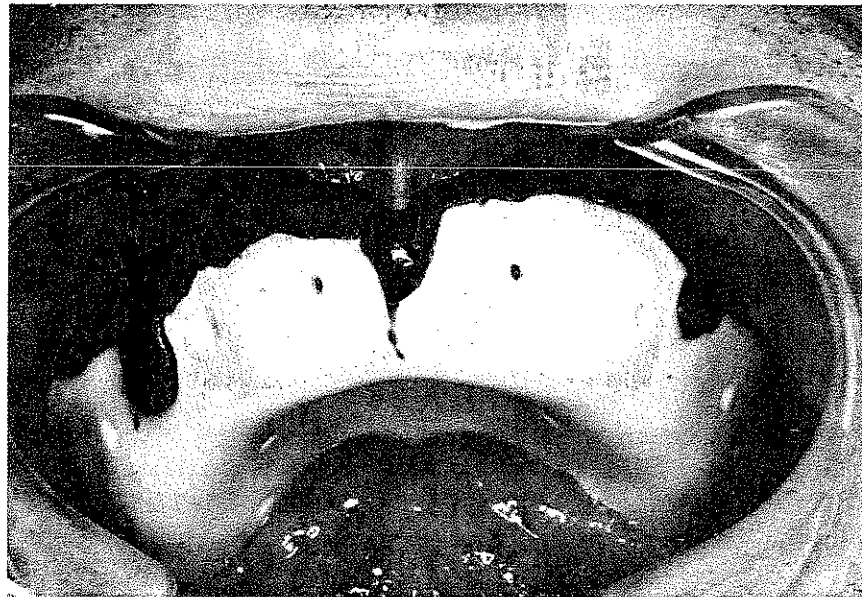


Figure 1:38. The Flanges and Notch are Evaluated Intra-orally After the Impression Tray is Border Molded with Dental Compound.

8. After completing the labial and buccal flanges, apply compound to the posterior border of the impression tray, flame the compound, temper it, and set the tray over the tissues in the patient's mouth. Allow compound to cool.
9. Remove and inspect the tray. The pterygomaxillary notches bilaterally and the fovea palatinae must be recorded. Excess compound may be trimmed as illustrated (Figure 1:39).

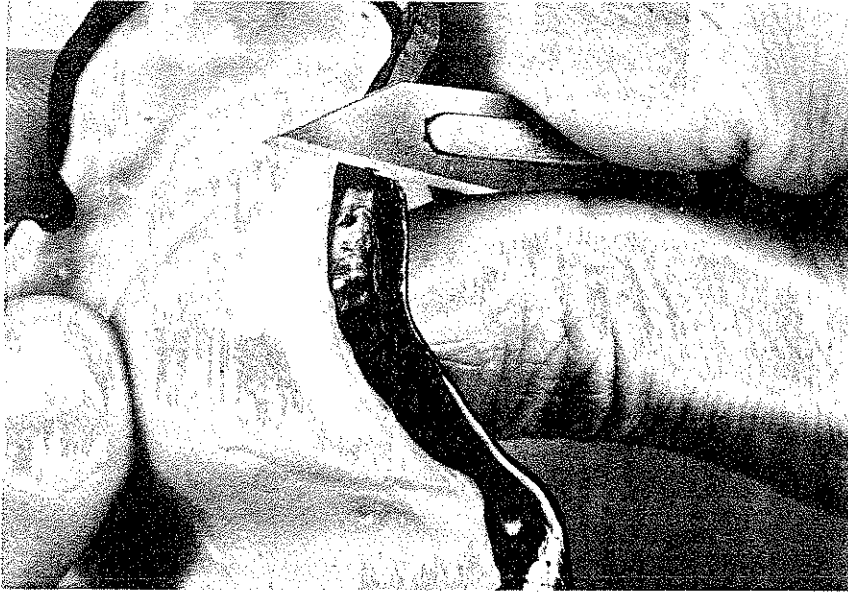


Figure 1:39. The Excess Compound is Trimmed from the Posterior Border of the Impression Tray According to the Available Anatomic Guides.

10. Dry the posterior border of the impression tray with gauze. Moisten the tip of the indelible pencil and apply the dye to the trimmed posterior border of the impression tray (Figure 1:40). Wipe dry with gauze the posterior palatal seal area of the oral tissue and seat the impression tray in the patient's mouth. The indelible line thus transferred to the palatal tissues provides a visual indication of the posterior extension of the impression tray (Figure 1:41).
11. Remove the tray and ask the patient to pronounce an "ah". Observe the relationship of the indelible line to the junction of the movable and immovable tissues.
12. Trim the posterior compound extension using the sharp red-handled knife. Again evaluate the tray using the indelible marking method and phonetics until it is of the proper length. Be sure the pressure relief holes have been placed. Now evaluate the tray to see that it satisfies the criteria.

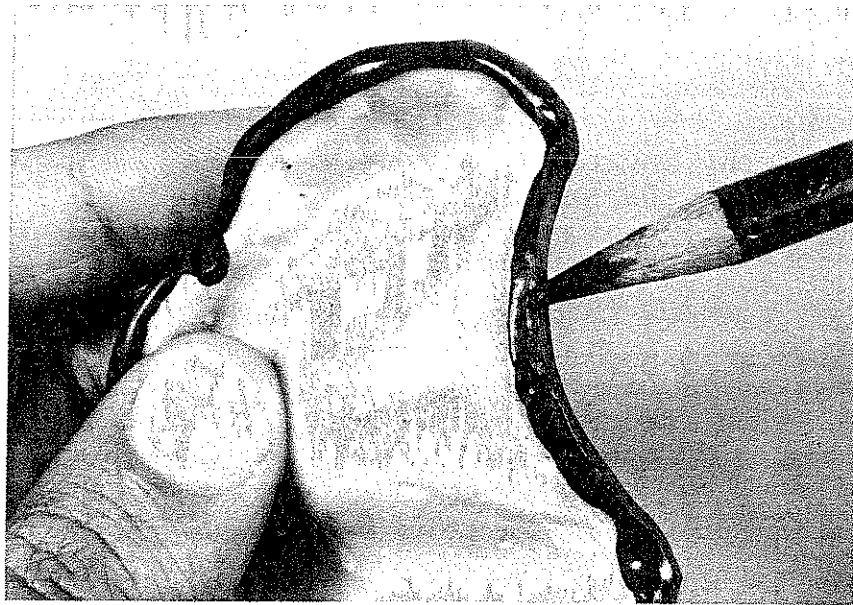


Figure 1:40. The Dye from the Indelible Pencil is Applied to the Compound Along the Posterior Border of the Impression Tray.

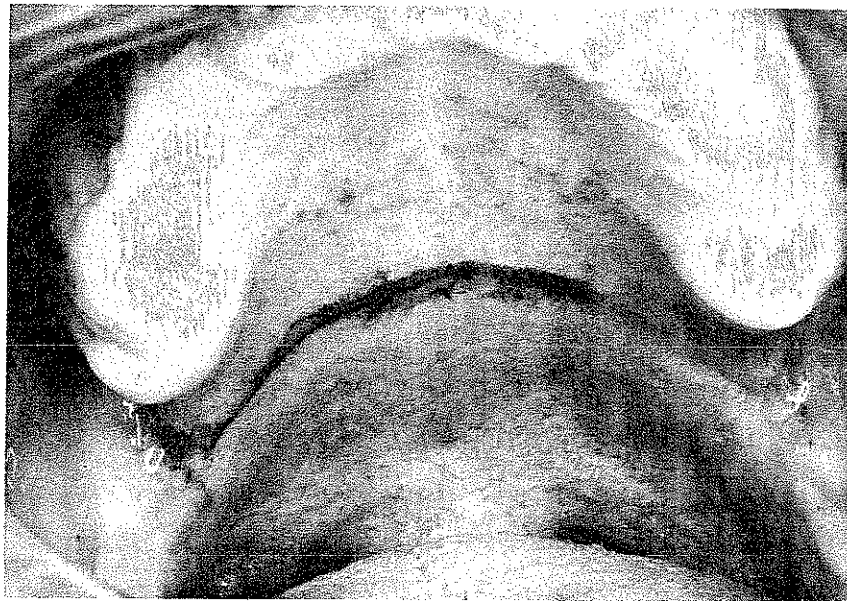


Figure 1:41. The Indelible Dye is Transferred to the Posterior Palatal Tissues and Provides a Visual Indication of the Posterior Extension of the Impression Tray.

CRITERIA - BORDER MOLDED MAXILLARY IMPRESSION TRAY

		<u>Meets</u> <u>Criteria</u>	<u>Does not</u> <u>meet Criteria</u>	<u>Comments</u>
1.	The hamular notches are included in the posterior borders.			
	Right	<input type="checkbox"/>	<input type="checkbox"/>	
	Left	<input type="checkbox"/>	<input type="checkbox"/>	
2.	The posterior border does not extend onto movable tissue. [Evaluation of the posterior border is made by drying the impression tray and posterior palate and using the indelible pencil on the posterior border of the tray to transfer the tray's length to the tissues.]	<input type="checkbox"/>	<input type="checkbox"/>	
3.	The buccal flanges cover the buccal sulci without impinging on moving tissues.			
	Right	<input type="checkbox"/>	<input type="checkbox"/>	
	Left	<input type="checkbox"/>	<input type="checkbox"/>	
4.	The posterior borders of the buccal flanges extend into the retrozygomatic spaces.			
	Right	<input type="checkbox"/>	<input type="checkbox"/>	
	Left	<input type="checkbox"/>	<input type="checkbox"/>	
5.	The labial flange extends into the sulcus without impinging on moving tissues.			
	Right	<input type="checkbox"/>	<input type="checkbox"/>	
	Left	<input type="checkbox"/>	<input type="checkbox"/>	

		<u>Meets</u> <u>Criteria</u>	<u>Does not</u> <u>meet Criteria</u>	<u>Comments</u>
6.	All flanges are rolled and not sharp.			
	Labial Right	<input type="checkbox"/>	<input type="checkbox"/>	
	Labial Left	<input type="checkbox"/>	<input type="checkbox"/>	
7.	The tray does not impinge on the frenula.			
	Labial	<input type="checkbox"/>	<input type="checkbox"/>	
	Buccal Right	<input type="checkbox"/>	<input type="checkbox"/>	
	Buccal Left	<input type="checkbox"/>	<input type="checkbox"/>	
8.	The notches are not excessively relieved.			
	Labial	<input type="checkbox"/>	<input type="checkbox"/>	
	Buccal Right	<input type="checkbox"/>	<input type="checkbox"/>	
	Buccal Left	<input type="checkbox"/>	<input type="checkbox"/>	
9.	The flanges are symmetrical.			
	Labial	<input type="checkbox"/>	<input type="checkbox"/>	
	Buccal	<input type="checkbox"/>	<input type="checkbox"/>	

STEPS IN BORDER MOLDING THE ACRYLIC RESIN MANDIBULAR FINAL IMPRESSION TRAY

1. Seat the patient in an upright position to gain maximum control of the impression materials.
2. Fit the mandibular final impression tray over the residual ridge area and check the flange extensions (Figure 1:42).

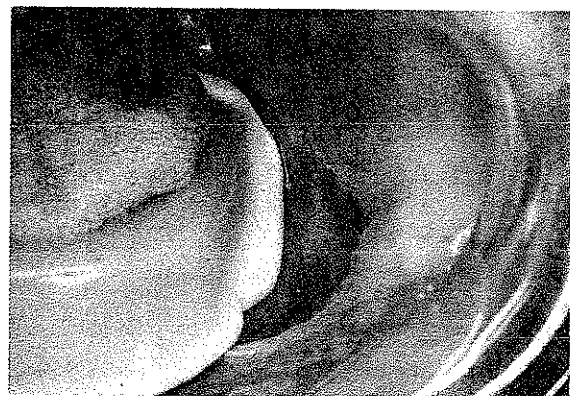
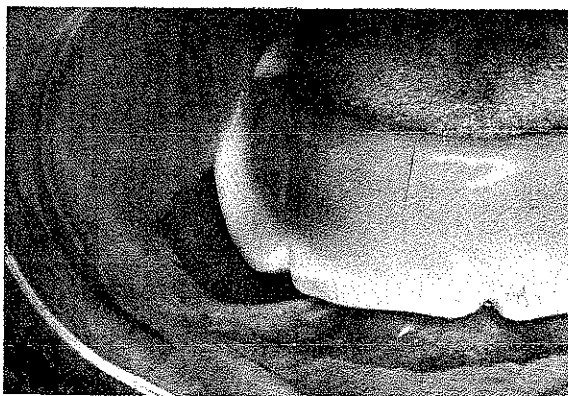
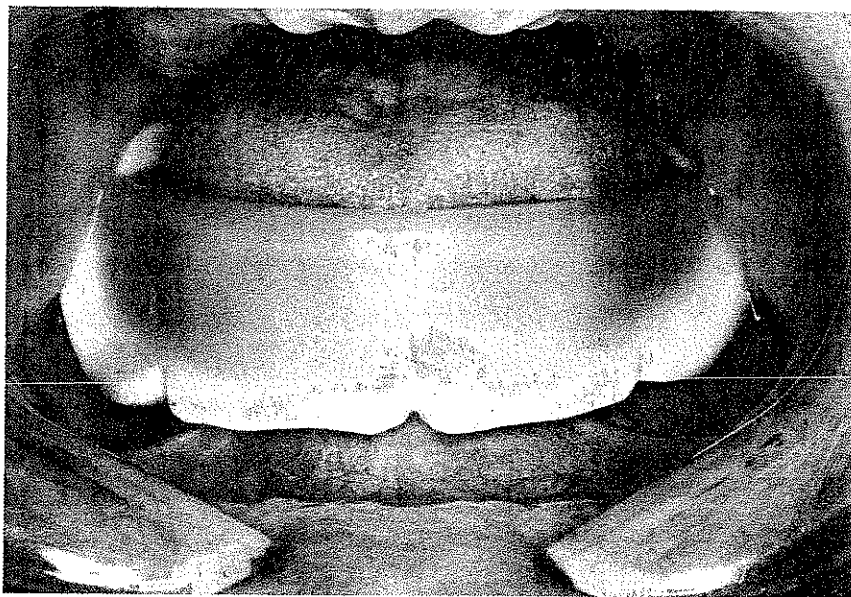


Figure 1:42. The Flanges are Shortened, and then Extended With Dental Compound by Using the Border Molding Method.

3. After assuring that the flanges of the impression tray are underextended, partially remove the relieve wax to provide adequate bonding of the compound additives to the tray (Figure 1:43).

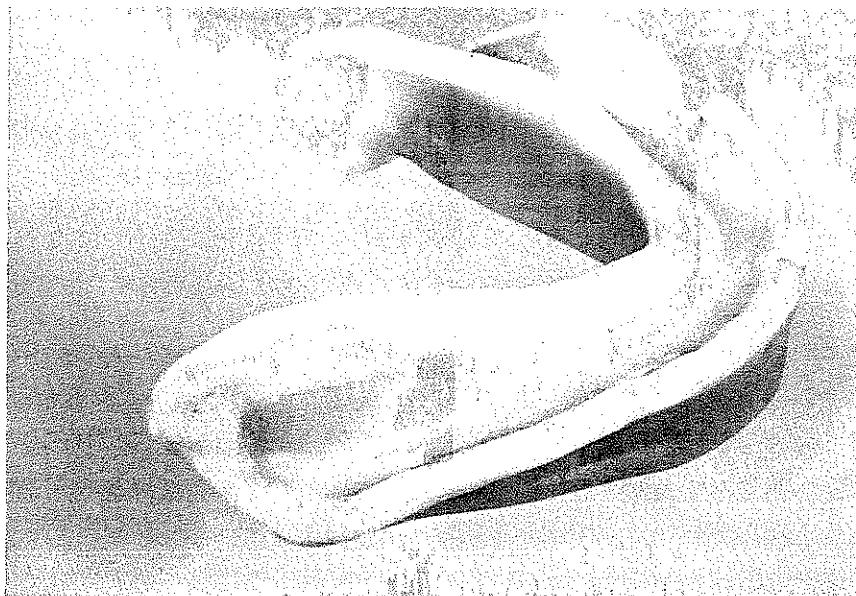


Figure 1:43. The Wax Relief is Partially Removed from the Tray.

4. Soften a small segment of the end of the stick compound in the bunsen burner. With a twisting motion, apply the softened compound in a stretched-out strip along the outer edge of the flange. Apply it in small segments to one quadrant at a time, using a small amount of compound. Seal the compound to the acrylic resin flange with a hot #7 spatula.
5. Adjust the Hanau torch to produce a brush flame, not a point, and gently heat the compound addition with the flame, temper it, and form the flange extension with fingers moistened in water. Re-flame lightly, temper, and then gently seat the tray over the tissues in the patient's mouth (Figure 1:44).

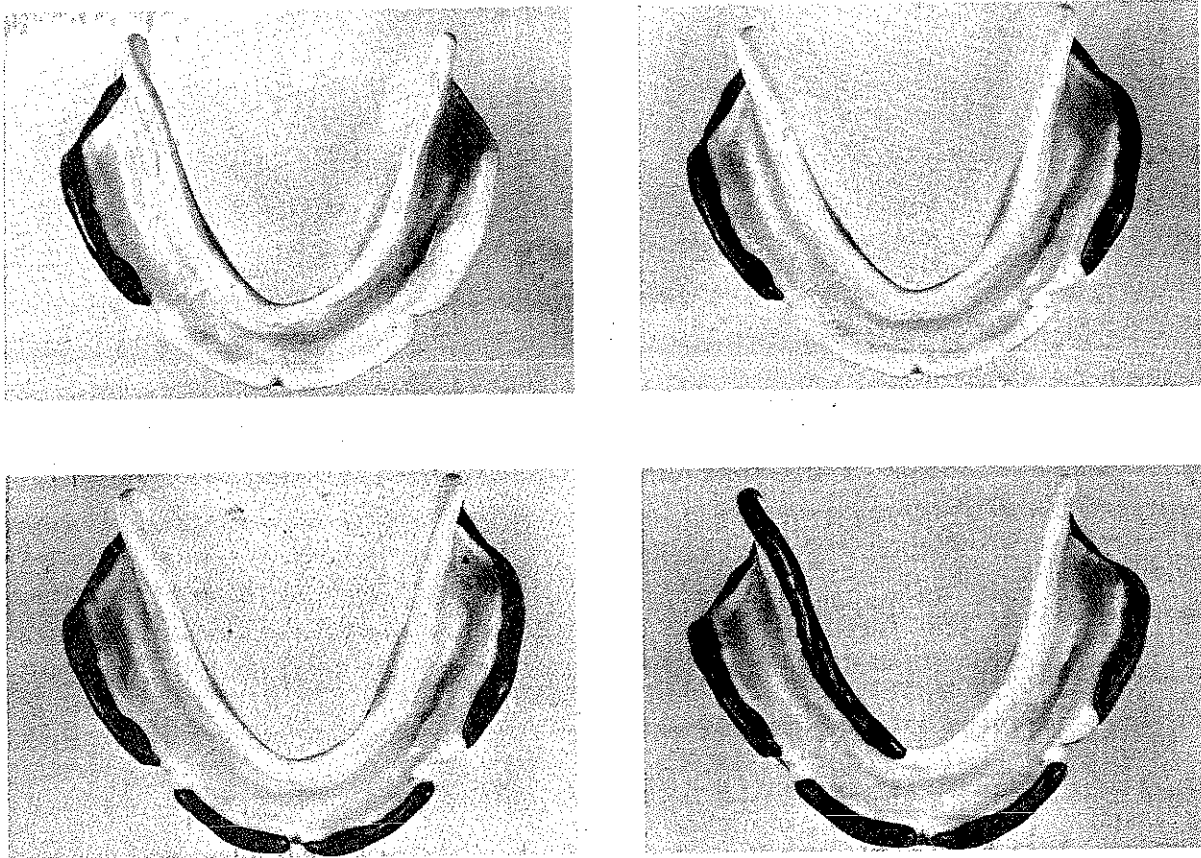


Figure 1:44. Small Segments of the Stick Compound are Added to the Tray. The Compound is Flamed Lightly, Tempered and then Seated Over the Tissues to Extend the Flanges to the Appropriate Length.

6. Remove and inspect the flanges. Trim the excess compound to the acceptable flange length using a sharp red-handled knife.

7. When the flanges have been restored to an acceptable length and width, the notches can then be better defined using again small compound additions. Remember to always temper the hot compound before placing the tray in the patient's mouth (Figure 1:45).

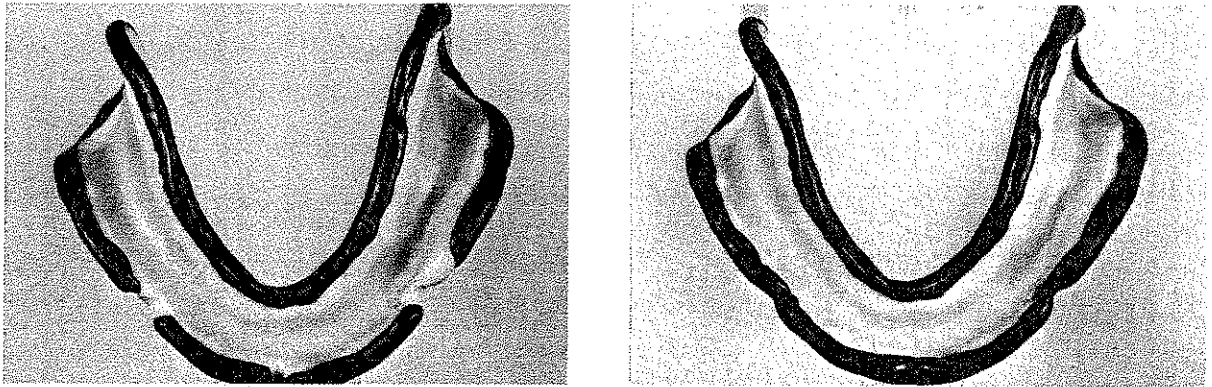


Figure 1:45. The Position and Configuration of the Frenum Can be Defined by Compound Additions.

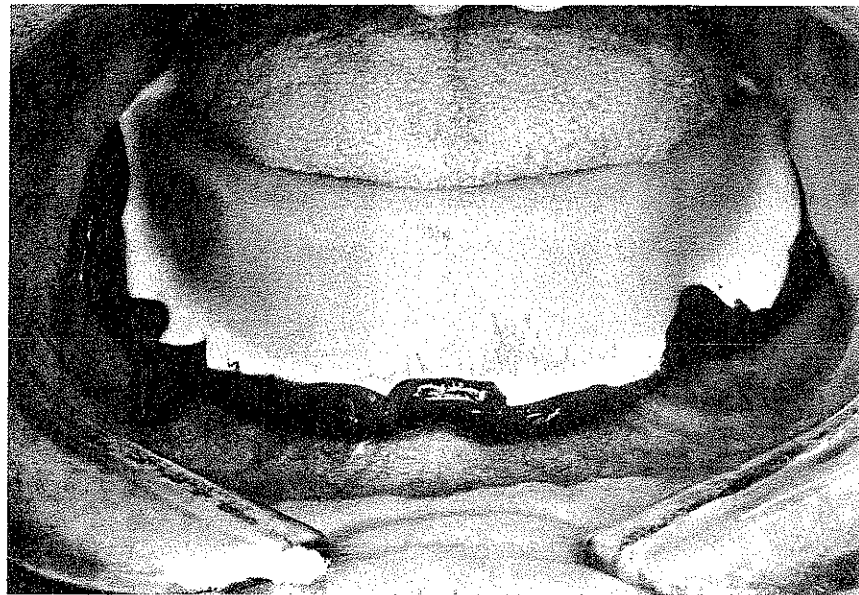
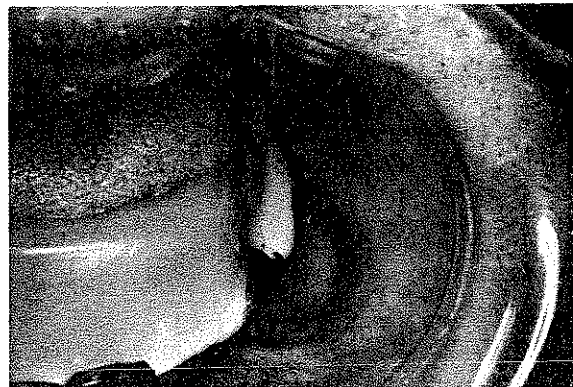
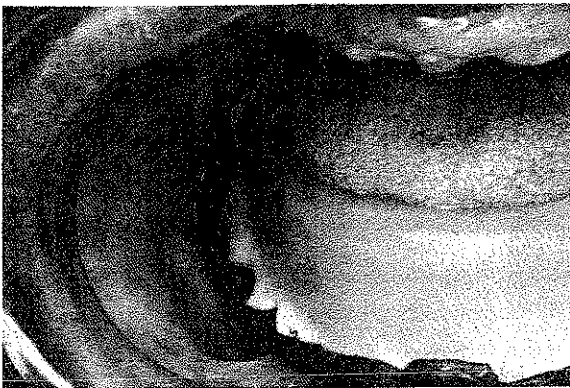
Figure 1:46. The Periphery of the Impression Tray has been Extended to the Appropriate Lengths by Dental Compound Additions and Border Molding Procedures.

Figure 1:47. The Buccal Flanges Have Been Extended in Length and Width by Dental Compound Additions and are Evaluated Intraorally.

8. After all the flanges and notches have been extended and/or defined in dental compound, the tray should be carefully inspected in position over the oral tissues and also evaluated to see that it fulfills the necessary criteria (Figure 1:46 and 1:47).



CRITERIA - BORDER MOLDED MANDIBULAR IMPRESSION TRAY

		<u>Meets</u> <u>Criteria</u>	<u>Does not</u> <u>meet Criteria</u>	<u>Comments</u>
1.	The tray covers, but does not extend beyond the retro-molar pads.			
	Maxillary			
	Right	<input type="checkbox"/>	<input type="checkbox"/>	
	Left	<input type="checkbox"/>	<input type="checkbox"/>	
	Mandibular			
	Right	<input type="checkbox"/>	<input type="checkbox"/>	
	Left	<input type="checkbox"/>	<input type="checkbox"/>	
2.	The tray covers, but does not extend beyond the buccal shelf.			
	Right	<input type="checkbox"/>	<input type="checkbox"/>	
	Left	<input type="checkbox"/>	<input type="checkbox"/>	
3.	The labial flanges extend into the labial sulci.			
	Right	<input type="checkbox"/>	<input type="checkbox"/>	
	Left	<input type="checkbox"/>	<input type="checkbox"/>	
4.	The tray does not impinge on the frenula.			
	Labial	<input type="checkbox"/>	<input type="checkbox"/>	
	Lingual	<input type="checkbox"/>	<input type="checkbox"/>	
	Right	<input type="checkbox"/>	<input type="checkbox"/>	
	Buccal	<input type="checkbox"/>	<input type="checkbox"/>	
	Left	<input type="checkbox"/>	<input type="checkbox"/>	
5.	The notches are not excessively relieved.			
	Labial	<input type="checkbox"/>	<input type="checkbox"/>	
	Lingual	<input type="checkbox"/>	<input type="checkbox"/>	
	Right	<input type="checkbox"/>	<input type="checkbox"/>	
	Buccal	<input type="checkbox"/>	<input type="checkbox"/>	
	Left	<input type="checkbox"/>	<input type="checkbox"/>	

		<u>Meets</u> <u>Criteria</u>	<u>Does not</u> <u>Meet Criteria</u>	<u>Comments</u>
6.	The lingual flanges are at or slightly below the mylohyoid ridges.			
	Right	<input type="checkbox"/>	<input type="checkbox"/>	
	Left	<input type="checkbox"/>	<input type="checkbox"/>	
7.	The most posterior extensions of the lingual flanges extend into the retromylohyoid spaces.			
	Right	<input type="checkbox"/>	<input type="checkbox"/>	
	Left	<input type="checkbox"/>	<input type="checkbox"/>	
8.	All flanges are rolled and not sharp.			
	Labial			
	Right	<input type="checkbox"/>	<input type="checkbox"/>	
	Left	<input type="checkbox"/>	<input type="checkbox"/>	
	Buccal			
	Right	<input type="checkbox"/>	<input type="checkbox"/>	
	Left	<input type="checkbox"/>	<input type="checkbox"/>	
	Lingual			
	Right	<input type="checkbox"/>	<input type="checkbox"/>	
	Left	<input type="checkbox"/>	<input type="checkbox"/>	
9.	The flanges are symmetrical.			
	Labial			
	Right	<input type="checkbox"/>	<input type="checkbox"/>	
	Left	<input type="checkbox"/>	<input type="checkbox"/>	
	Buccal			
	Right	<input type="checkbox"/>	<input type="checkbox"/>	
	Left	<input type="checkbox"/>	<input type="checkbox"/>	
	Lingual			
	Right	<input type="checkbox"/>	<input type="checkbox"/>	
	Left	<input type="checkbox"/>	<input type="checkbox"/>	

STEPS IN MAKING THE MAXILLARY FINAL IMPRESSION USING A RUBBER
BASE IMPRESSION MATERIAL

1. Any 28 gauge relief wax that still remains on the inner surface of the impression tray should be removed at this time.
2. Paint the inner surface and the peripheries of the final impression tray with rubber base adhesive. Let dry for approximately 5-10 minutes (Figure 1:48).

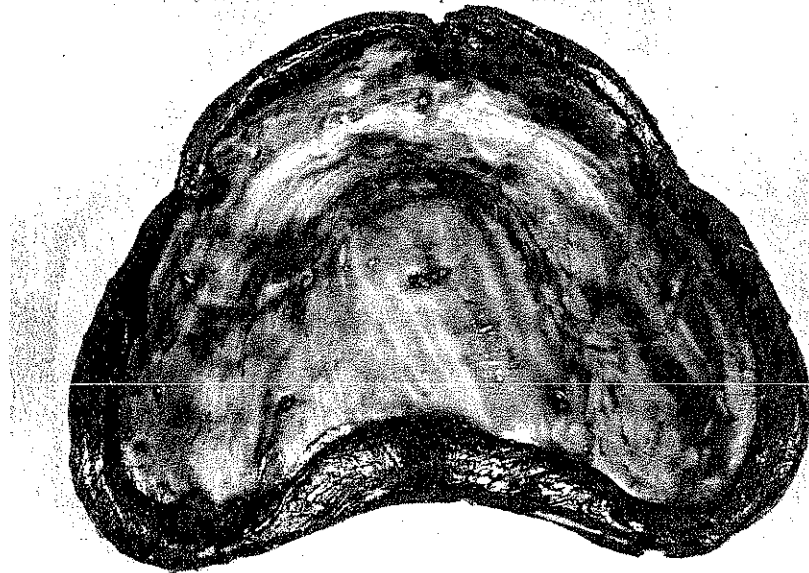

Figure 1:48. The Relief Wax has been Removed and the Necessary Adhesive Painted Over the Inner Surface of the Tray and its Peripheries.

3. Using light-bodied rubber base impression material, mix equal lengths (approximately 2-3 inches of each) of the base and the catalyst as demonstrated in the videotape and apply a thin uniform layer of the impression material within the impression tray and over the peripheries. This small amount of material will register the tissues adequately, since the tray has been only minimally relieved. Avoid over-filling the tray.
4. Place the impression tray over the maxillary ridge and seat the posterior border first, rotating the impression as it is carried forward to place. Gently hold the impression tray in position for 10 minutes, or until the impression material sets. **ONE SHOULD NEVER LEAVE THE PATIENT UNATTENDED!** Patients become apprehensive at this point in the procedure.

5. Remove the final impression and inspect it to ensure that it records all of the necessary structures and has no voids. If the impression is not acceptable, remove the rubber base and prepare a new wash of impression material (Figure 1:49).

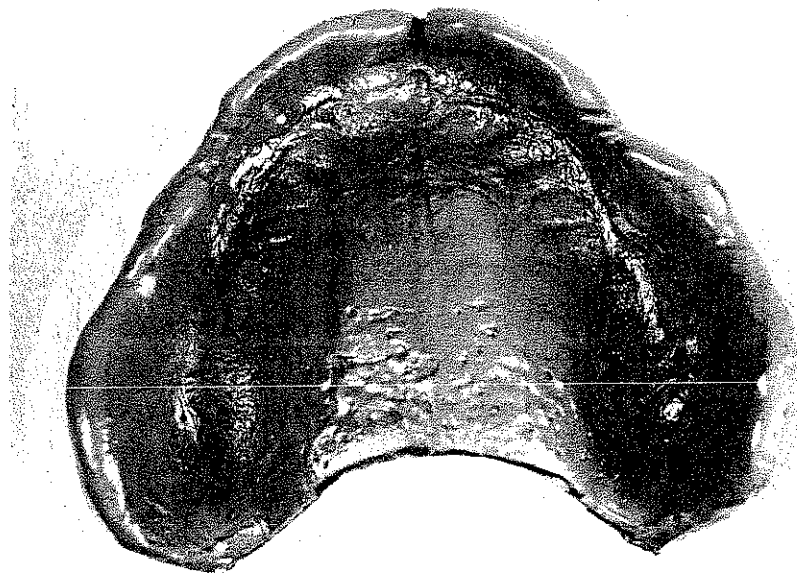


Figure 1:49. An Acceptable Final Maxillary Rubber Base Impression.

6. When the final impression is acceptable, trim excess impression material extending from the posterior border to the length established in compound during the border molding. This length can be checked by applying the indelible pencil to the posterior border of the final impression, drying the palatal seal area with gauze and reseating the final impression. An indelible line will be transferred to the palate marking the posterior extension of the impression, much as it did when the impression tray was being border molded in dental compound. Ask the patient to say "ah" and visually observe whether the posterior border is properly positioned. The denture base should end at the junction of the movable and immovable tissues.

7. Develop a functional posterior palatal seal by first placing a very thin film of sticky wax across the posterior border of the impression with the hot end of the #7 spatula. The sticky wax will enhance adherence of the #4 Korecta Wax to the rubber base material.
8. Next apply molten #4 Korecta Wax to the posterior border of the impression as illustrated in Figure 1:50. Reposition the final impression over the maxillary residual ridge and hold with light pressure for 2-3 minutes. Remove the impression and inspect the posterior palatal seal (Figure 1:50).
9. The posterior palatal seal is adequate when the #4 Korecta Wax is smooth, indicating it has flowed and is in contact with the oral tissues, and when retention of the impression can be demonstrated. Evaluation of retention is made when a moderate pressure with a lateral component is applied in the maxillary cuspid region unilaterally (Figure 1:51).

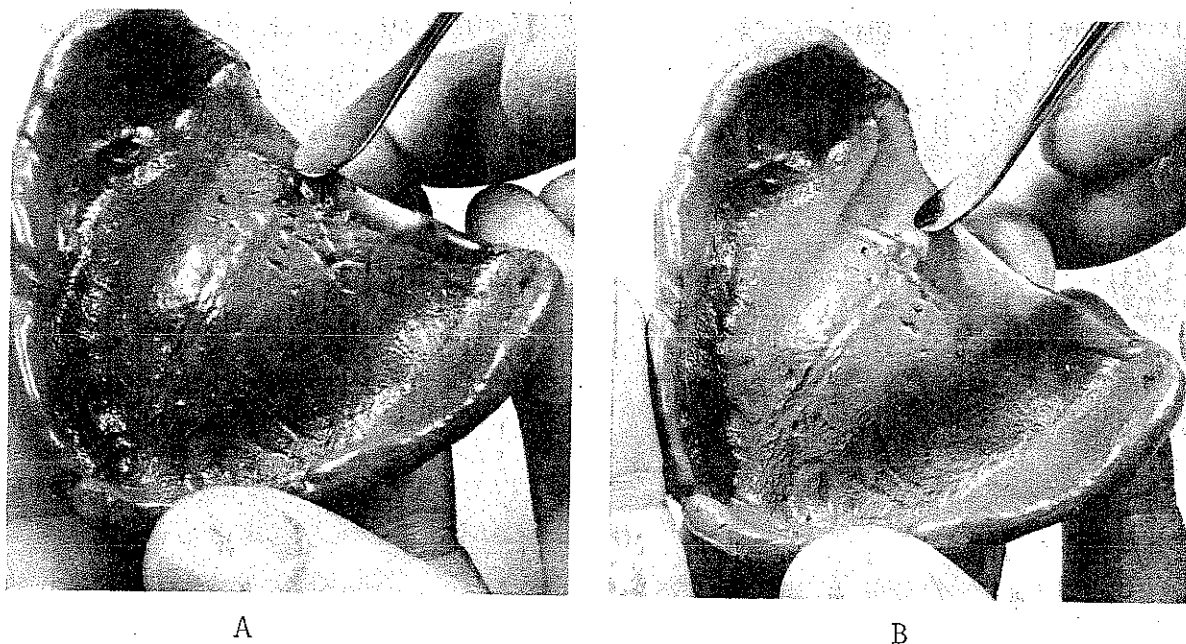


Figure 1:50. A) A Thin Addition of Sticky Wax is Applied Across the Posterior Border of the Impression to, B) Enhance the Adherence of the #4 Korecta Wax.

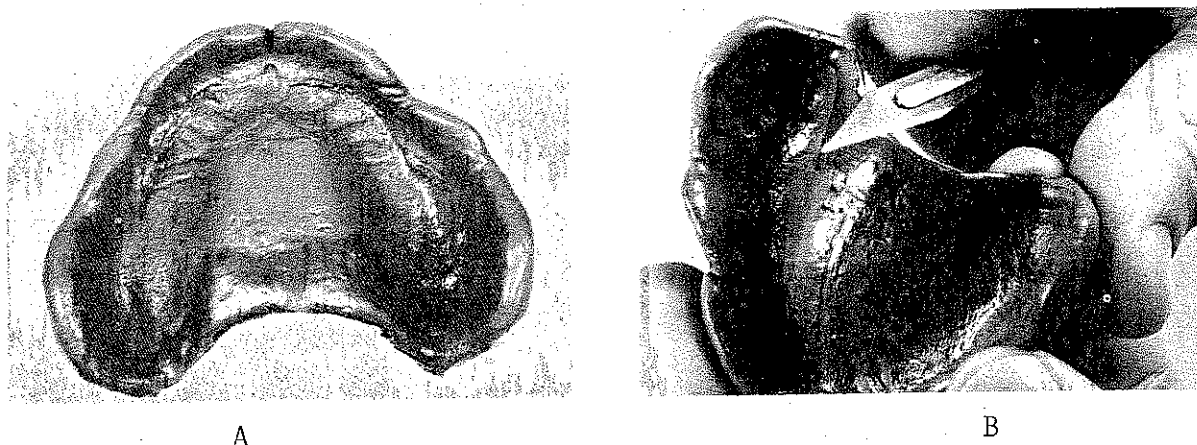



Figure 1:51. A) The Posterior Palatal Seal is Adequate When the Wax is Smooth. B) Excess Wax that Flows Posteriorly Can Be Carefully Removed with the Sharp Knife Blade.

STEPS IN MAKING THE MANDIBULAR FINAL IMPRESSION


1. Remove all of the remaining 28 gauge relief wax and round the compound extension with a sharp knife (Figure 1:52).
2. If the pressure relief holes were not previously placed, be sure to do so at this time using a #4 round bur.
3. Paint the inner surface and the peripheries of the final impression tray with the rubber base adhesive. Let dry for approximately 5-10 minutes (Figure 1:53).



Figure 1:52. All Remaining Relief Wax is Removed and the Compound Extensions Rounded with a Sharp Knife.



A



B

Figure 1:53. A) Pressure Relief Holes are Placed with the #4 Round Bur and, B) The Tray is Painted with The Rubber Base Adhesive.

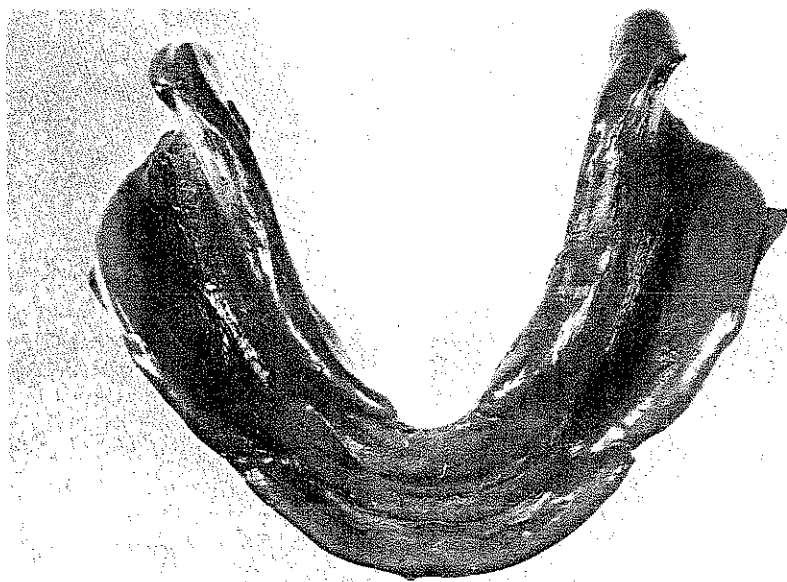


Figure 1:54. Final Mandibular Rubber Base Impression.

4. Using light-bodied rubber base impression material, mix equal lengths (approximately 2-3 inches of each) of the base and the catalyst and paint a thin wash over the inner surface and the peripheries of the impression tray.
5. Seat the impression tray over the mandibular ridge as demonstrated, and gently hold in position for approximately 10 minutes or until the material sets.
6. Remove the final impression and inspect it for voids. Repeat the procedure if necessary (Figure 1:54).

STEPS IN MAKING MAXILLARY OR MANDIBULAR FINAL IMPRESSIONS USING A ZINC OXIDE AND EUGENOL PASTE MATERIAL AS THE FINAL WASH

The steps in making final impressions with a zinc-oxide and eugenol impression paste are the same as when using the rubber base material with the following exceptions:

1. An adhesive painted on the trays is not required. However the trays should be dry.
2. When opposing bony undercuts are present, zinc oxide-eugenol impression material should not be used. Rubber base material is the material of choice.
3. The sticky wax does not need to be applied to the posterior border of the zinc oxide and eugenol maxillary final impression, however, the final impression must be dry before adding Korecta Wax #4 (Figure 1:55).
4. Any zinc oxide-eugenol paste material that gets onto the patient's face can be removed with gauze moistened with oil of orange.

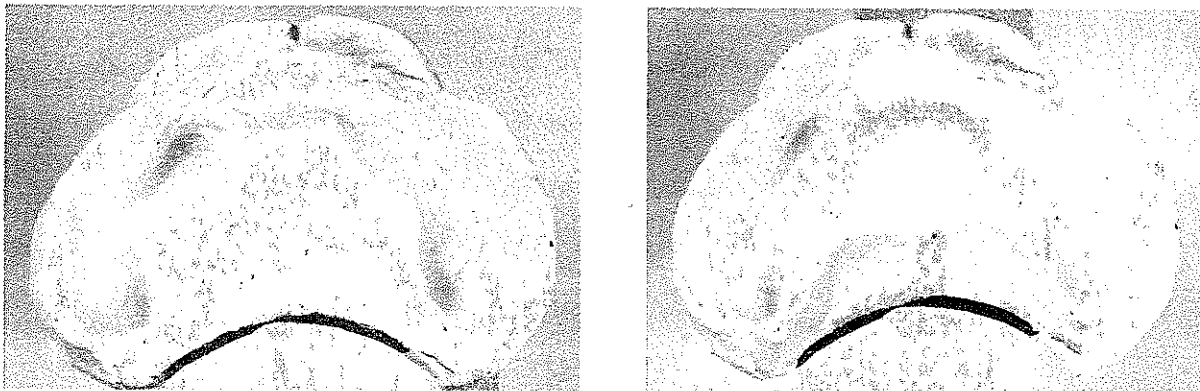


Figure 1:55. Final Maxillary Zinc Oxide and Eugenol Impression with Korecta Wax #4 Posterior Palatal Seal.

CRITERIA - FINAL MAXILLARY AND MANDIBULAR IMPRESSIONS

			Meets Criteria	Does not meet Criteria	Comments
1.	The impression material is evenly distributed in the impression tray.				
	Maxillary		<input type="checkbox"/>	<input type="checkbox"/>	
	Mandibular		<input type="checkbox"/>	<input type="checkbox"/>	
2.	The peripheries are well defined.				
	Maxillary	Labial	Right	<input type="checkbox"/>	<input type="checkbox"/>
			Left	<input type="checkbox"/>	<input type="checkbox"/>
	Maxillary	Buccal	Right	<input type="checkbox"/>	<input type="checkbox"/>
			Left	<input type="checkbox"/>	<input type="checkbox"/>
	Mandibular	Labial	Right	<input type="checkbox"/>	<input type="checkbox"/>
			Left	<input type="checkbox"/>	<input type="checkbox"/>
	Mandibular	Buccal	Right	<input type="checkbox"/>	<input type="checkbox"/>
			Left	<input type="checkbox"/>	<input type="checkbox"/>
		Lingual	Right	<input type="checkbox"/>	<input type="checkbox"/>
			Left	<input type="checkbox"/>	<input type="checkbox"/>
3.	There are no significant voids.				
	Maxillary		<input type="checkbox"/>	<input type="checkbox"/>	
	Mandibular		<input type="checkbox"/>	<input type="checkbox"/>	
4.	There are no significant areas in which the trays have contacted the supporting tissues.				
	Maxillary		<input type="checkbox"/>	<input type="checkbox"/>	
	Mandibular		<input type="checkbox"/>	<input type="checkbox"/>	

	<u>Meets</u> <u>Criteria</u>	<u>Does not</u> <u>Meet Criteria</u>	<u>Comments</u>
5. The posterior border of the maxillary impression accurately records the area in which the posterior palatal seal is to be established.	<input type="checkbox"/>	<input type="checkbox"/>	
6. When the functional posterior palatal seal is used, the fluid wax shows evidence of having flowed evenly across the posterior border.	<input type="checkbox"/>	<input type="checkbox"/>	
7. The posterior palatal seal outline form is adequate.	<input type="checkbox"/>	<input type="checkbox"/>	
8. The maxillary impression is retentive. [Evaluation of retention is made when a moderate pressure with a lateral component is applied in the maxillary cuspid region unilaterally.]	<input type="checkbox"/>	<input type="checkbox"/>	
9. The impression should resist movement when moderate pressure is applied vertically and horizontally in the first molar areas both unilaterally and bilaterally.			
Maxillary	<input type="checkbox"/>	<input type="checkbox"/>	
Mandibular	<input type="checkbox"/>	<input type="checkbox"/>	
10. The impression material contacts the supporting tissues everywhere.			
Maxillary	<input type="checkbox"/>	<input type="checkbox"/>	
Mandibular	<input type="checkbox"/>	<input type="checkbox"/>	

OBJECTIVES

Knowledge. Upon completion of this Procedure, you will be able to:

1. State, for the maxillary master cast produced by the wax boxing method, for the mandibular master cast boxed in the 3:1 mixture of impression plaster and filler, and for the arbitrary posterior palatal seal:
 - a. In sequential order, the steps in fabrication.
 - b. The criteria for a clinically acceptable product.
2. State the consequences if the base of the master cast is too thick or too thin.

Skill. While you will not box final impressions or pour master casts in the Preclinical Course, you should understand how they are done. You will develop an arbitrary posterior palatal seal on a maxillary master cast which will be supplied.

VIDEOTAPES

1. Requirements of a Master Cast.
2. Boxing Maxillary and Mandibular Final Impressions.
3. Pouring Models and Trimming Master Casts.
4. Arbitrary Posterior Palatal Seal.

MATERIALS NEEDED FOR PROCEDURE #4

1. Bunsen burner.
2. #7 spatula or a vulcanite scraper.
3. Boxing rope.
4. Boxing strip.
5. Impression plaster.
6. Pumice.
7. Rubber bowl.
8. Kerr laboratory spatula.
9. Glass slab.
10. Liquid foil substitute and brush.
11. Dental stone (yellow).
12. #8 round bur (straight handpiece).

STEPS IN MAKING THE MAXILLARY MASTER CAST FROM THE FINAL IMPRESSION USING THE WAX BOXING METHOD

1. Seal wax boxing rope around the periphery, 1 to 2 mms. below the borders of the impression (Figure 1:56 and 1:57).

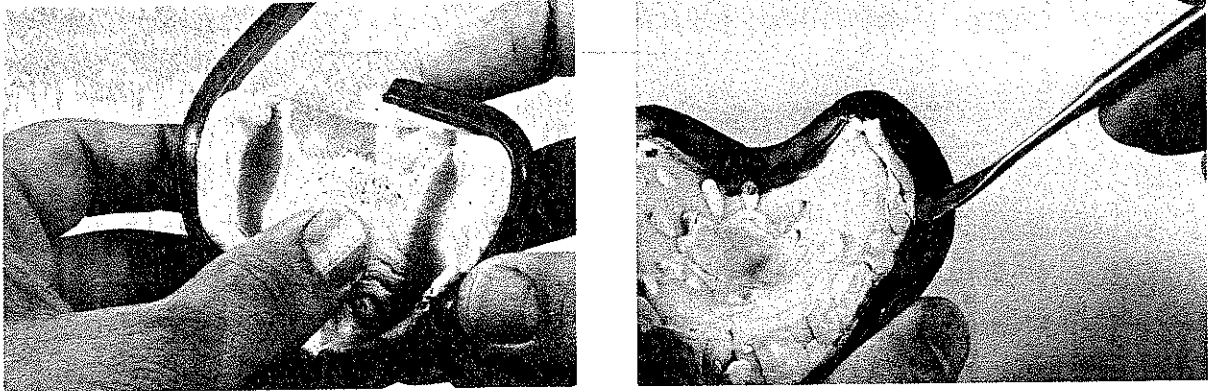

Figure 1:56. The Boxing Rope is Positioned 1-2 mms. Below the Peripheral Roll. The Wax is Sealed to the Impression Tray on the Reverse Surface.




Figure 1:57. Be Sure That the Boxing Rope is Slightly Below the Posterior Border of the Impression in Order to Create the Proper Landing Area.

2. Join the wax boxing strip to the boxing rope and seal the waxes with a hot #7 spatula.
3. Mix dental stone (yellow) in a proportion of 30 cc. of water to 100 gms. of dental stone (yellow). To pour the maxillary impression you will need 45 cc. of water and 150 gms. of dental stone (yellow).
4. Vibrate mixed dental stone onto all tissue surfaces of the boxed impression in an even flow. So you will not trap air, pour the stone in one corner and allow to flow slowly around the impression to the other corner (Figure 1:58).





Figure 1:58. The Wax Boxing Strip is Sealed to the Rope from the Reverse Side. The Impression is Positioned Within the Boxing Strip to Create a Base of at Least 1/2 inch Thickness and the Impression is Poured in Yellow Dental Stone.

5. Let the dental stone set, remove the boxing wax, and trim the master cast to the proper dimensions as stated on the criteria sheet (Figure 1:59).

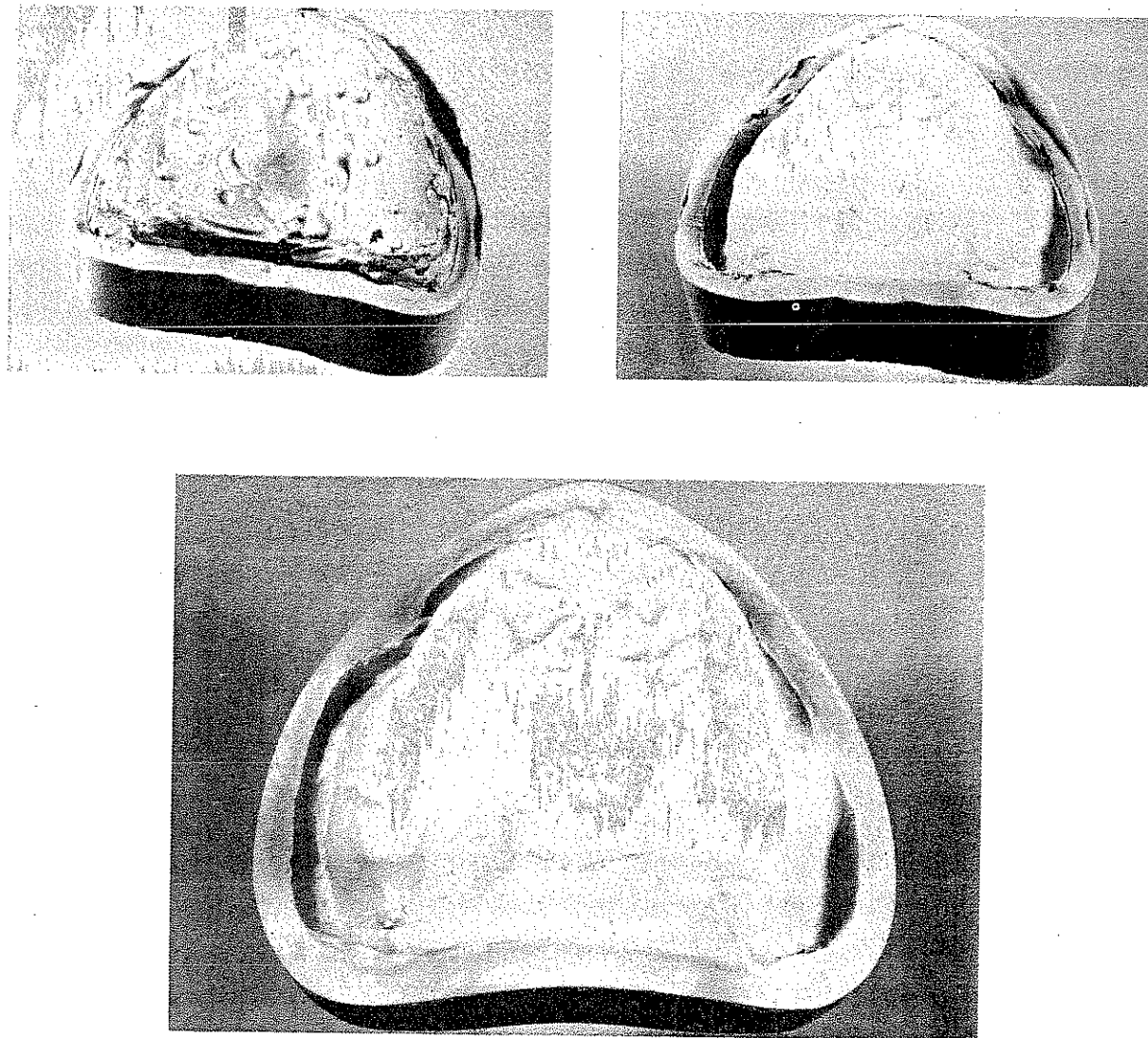


Figure 1:59. The Impression Tray is Separated from the Master Cast and Trimmed to the Proper Base Dimensions.

STEPS IN MAKING THE MANDIBULAR MASTER CAST FROM THE FINAL
IMPRESSION USING THE IMPRESSION PLASTER - PUMICE METHOD

1. Add a mixture of 3 parts IMPRESSION PLASTER and 1 part PUMICE to water to prepare a thin mix. It will set quite rapidly if it is too thick.
2. Place the plaster-pumice mixture on the glass slab and the mandibular impression (tissue side up) within this mass. Leave the tissue surface of the impression tray exposed (Figure 1:60).
3. Work the mixture around the impression to form the landing area. If it hardens before you have completely formed the landing area, prepare a second mixture. Additions, made where necessary, bond easily to the first mixture.
4. After the plaster and pumice mixture has set, grind it with the model trimmer to establish a boxing edge of 3-4 mms. (Figure 1:61).

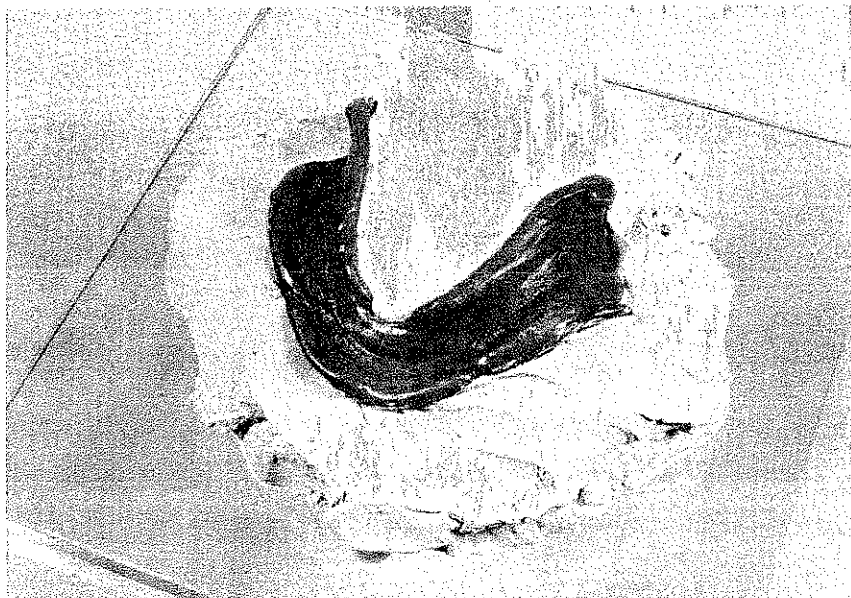

Figure 1:60. The Final Mandibular Impression is Placed in the Impression Plaster-Pumice Mix.

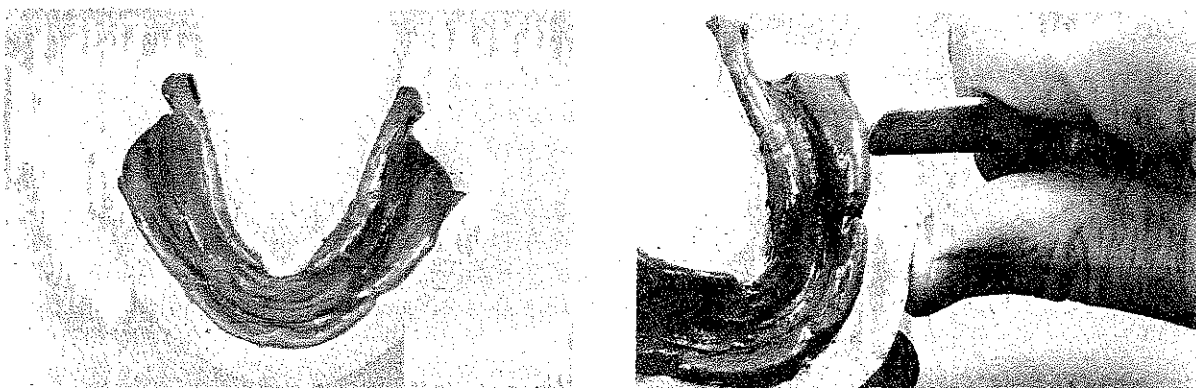

Figure 1:61. The Plaster-Pumice Base is Carefully Trimmed.

5. Apply sticky wax to the plaster-pumice base, and attach the boxing strip.
6. Paint the exposed landing areas and the tongue space with the liquid foil substitute (Figure 1:62).
7. Vibrate 150 gms. of mixed dental stone (yellow) onto all tissue surfaces of the boxed impression in an even flow. Pour the stone in one corner and allow it to flow slowly around the impression to the other corner (Figure 1:63).




Figure 1:62. Sticky Wax is Applied to Facilitate Attachment of the Boxing Strips. The Plaster-Pumice is Painted with the Liquid Foil Substitute.




Figure 1:63. The Impression is Poured in Yellow Dental Stone.

8. Let the dental stone set, remove boxing wax and plaster-pumice base, and trim the master cast to the proper dimensions as stated on the criteria sheet (Figures 1:64 and 1:65).


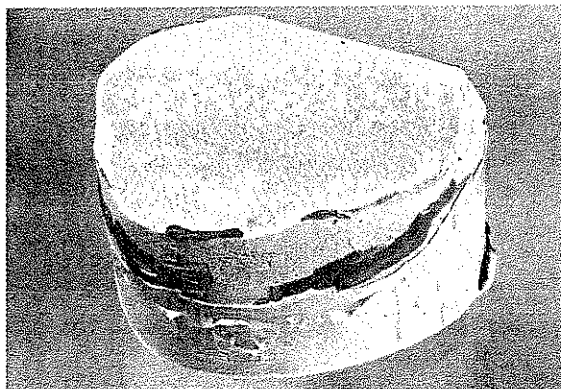


Figure 1:64. The Boxing Wax is Removed and the Master Cast is Separated from the Plaster-Pumice Base.

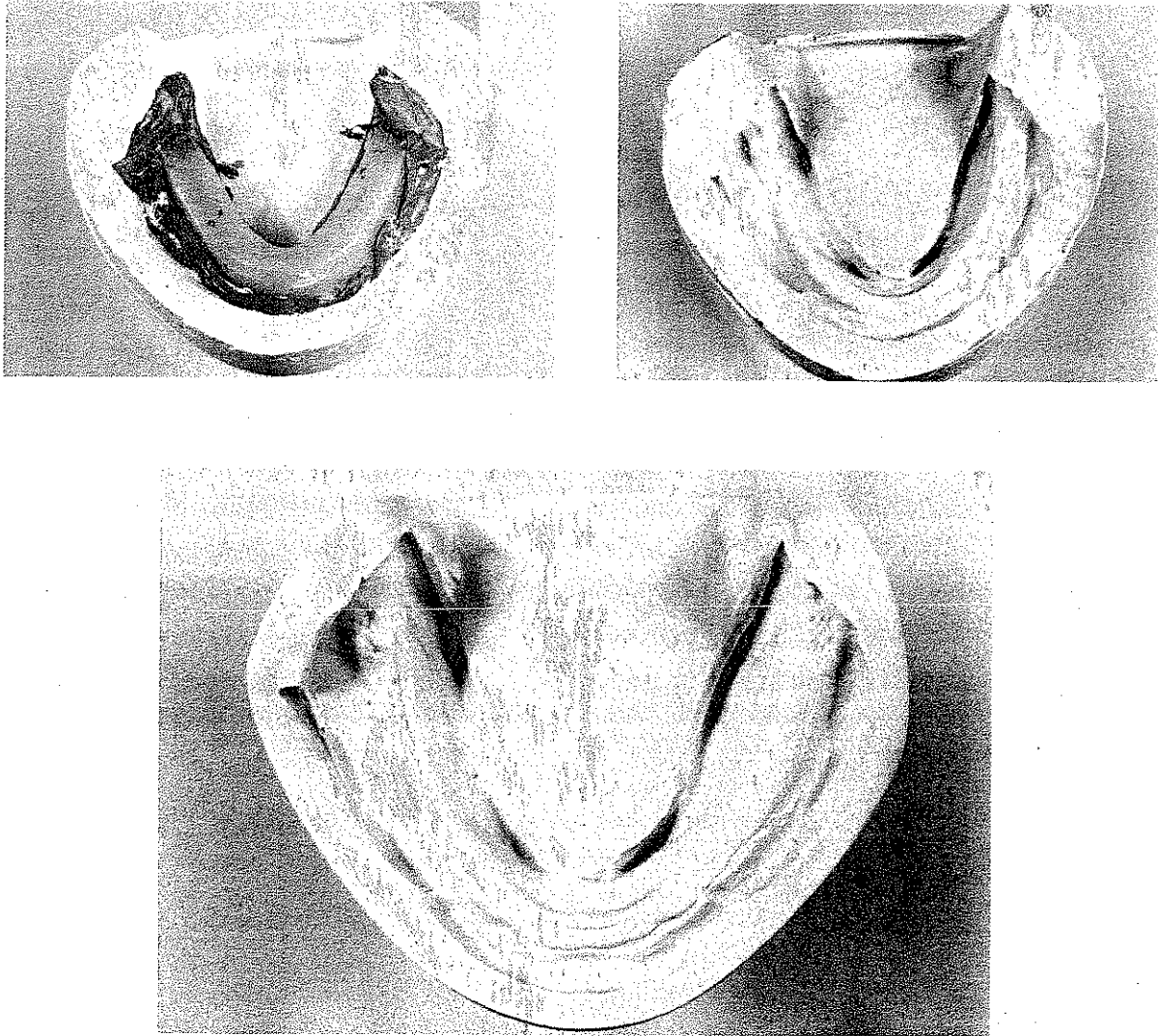


Figure 1:65. The Master Cast is Separated from the Impression, Cleansed of Debris and Trimmed to the Proper Base Dimensions.

9. Evaluate the master casts using the criteria sheet.

CRITERIA - MAXILLARY AND MANDIBULAR MASTER CASTS

	<u>Meets Criteria</u>	<u>Does not meet Criteria</u>	<u>Comments</u>
1. The cast includes <u>all</u> anatomical surfaces of the final impression.	<input type="checkbox"/>	<input type="checkbox"/>	
2. The cast includes a 3-4 mm. landing area around the entire periphery of the master cast.	<input type="checkbox"/>	<input type="checkbox"/>	
3. The peripheral borders are not more than 2 mms. below the landing edge.	<input type="checkbox"/>	<input type="checkbox"/>	
4. The base of the master cast is parallel to the residual ridge and about <u>1/2 inch thick.</u>	<input type="checkbox"/>	<input type="checkbox"/>	
5. The cast contains no bubbles or flaws in the stone.	<input type="checkbox"/>	<input type="checkbox"/>	

STEPS IN DEVELOPING AN ARBITRARY POSTERIOR PALATAL SEAL ON THE MAXILLARY MASTER CAST

1. A reasonably accurate determination of the posterior extension of the denture base has been transferred by the final impression to the master cast. This border extends from each hamular notch bilaterally and usually covers the foveae palatinae in the midline. Using a pencil draw a line along the posterior extension of the denture base using these anatomical guides. You should recognize what is landing area and what is tissue (Figure 1:66).
2. Draw a second line anterior to the line drawn. The second line should be at least 6-7 mms. anterior to the posterior line at the midline and should follow the configuration shown in Figure 1:66.


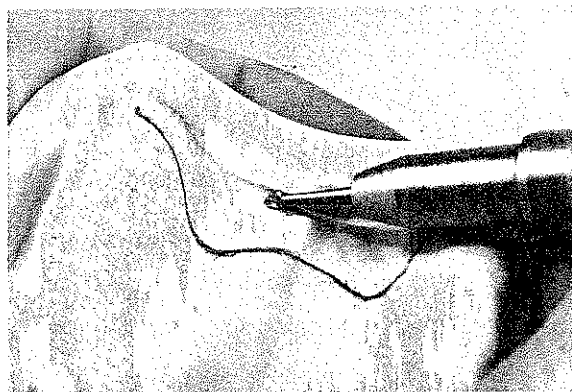
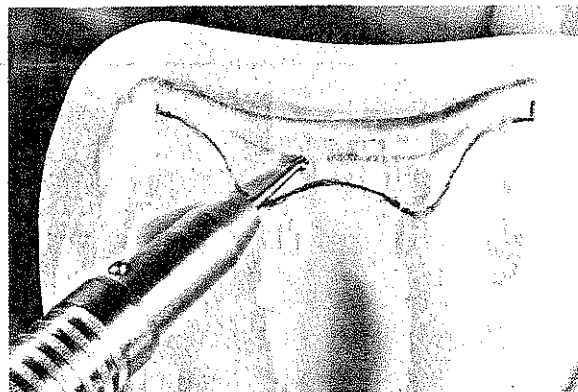


Figure 1:66. The Outline of the Posterior Palatal Seal is Drawn on the Master Cast. It Should Extend Through the Hamular Notches Bilaterally and Extend Anteriorly in the Areas of the Palatal Glandular Tissues.

3. Using a #8 round bur cut along the posterior line on the stone master cast to a depth one-half the diameter of the bur.
4. Cut a second line slightly anterior to the posterior cut, but penetrating only one-quarter the diameter of the bur (Figure 1:67).



A



B

Figure 1:67. A) The Posterior Line on the Stone Master Cast is Cut to a Depth of $\frac{1}{2}$ the Diameter of a #8 Straight Handpiece Round Bur. B) A Second Cut is Made Anterior to the First $\frac{1}{4}$ of the Diameter of the #8 Bur.


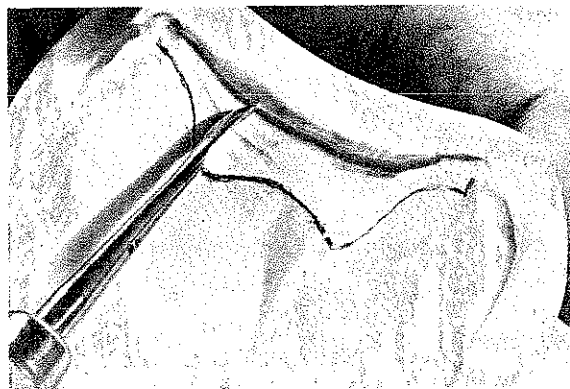


Figure 1:68. With the Large End of a #7 Spatula or a Vulcanite Scraper the Stone Between the Two Bur Cuts is Removed and the Area is Smoothed and Blended so as not to Create a Sharp Stone Edge.

5. Use the large end of the #7 spatula or a vulcanite scraper to remove the stone between the two bur cuts. Continue to remove stone forward of this area toward the most anterior outline that was drawn for the posterior palatal seal, blending and smoothing your scraping so as not to create a sharp stone edge where relief for the posterior palatal seal meets the unaltered anatomical form of the master cast. (Figure 1:68).
6. The mechanically created arbitrary posterior palatal seal should extend laterally through the hamular notches and fulfill the stated criteria. (Figure 1:69).

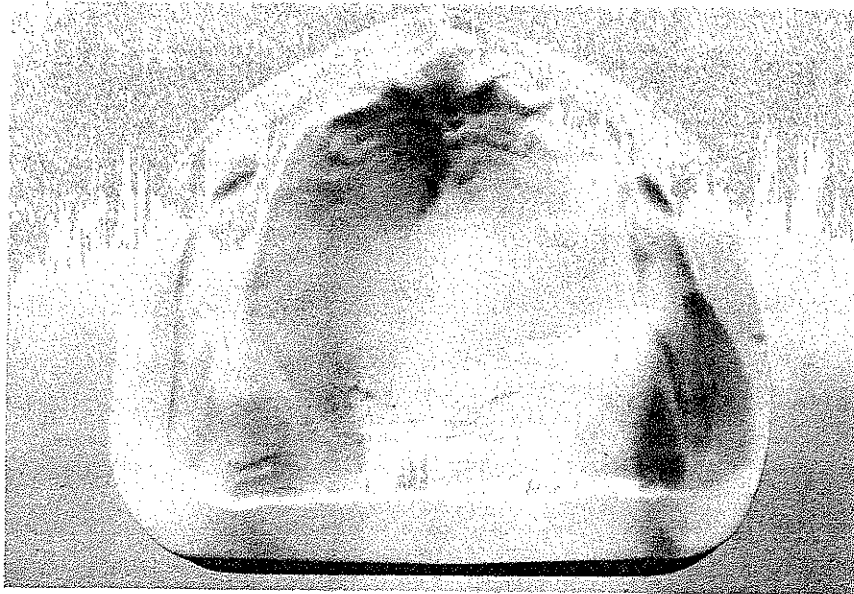


Figure 1:69. The Arbitrary Posterior Palatal Seal that Fulfills the Stated Criteria.

CRITERIA - ARBITRARY POSTERIOR PALATAL SEAL

	<u>Meets Criteria</u>	<u>Does not meet Criteria</u>	<u>Comments</u>
1. The posterior border of the posterior palatal seal is on tissue and not on the landing area of the cast.	<input type="checkbox"/>	<input type="checkbox"/>	
2. The posterior palatal seal extends laterally through the hamular notches and covers the foveae palatinae in the midline of the cast.	<input type="checkbox"/>	<input type="checkbox"/>	
3. The posterior palatal seal area is 6-7 mms. anterior to the posterior border.	<input type="checkbox"/>	<input type="checkbox"/>	
4. The depth of the posterior palatal seal area is 1/2 the diameter of an #8 round bur at the posterior border.	<input type="checkbox"/>	<input type="checkbox"/>	
5. The depth of the post dam decreases to blend with the tissues in the anterior line of the posterior palatal seal.	<input type="checkbox"/>	<input type="checkbox"/>	
6. The stone at the edges of the post dam is not sharp.	<input type="checkbox"/>	<input type="checkbox"/>	

COMPUTER-GENERATED SECTION TEST 1

You are now ready to take Computer-Generated Section Test 1, which will cover:

1. Anatomy of the Edentulous Mouth and Corresponding Landmarks on the Maxillary and Mandibular Final Impressions and on the Master Casts.
2. Preliminary Impressions.
3. Final Impression Trays.
4. Final Impressions.
5. Boxing the Final Impressions and Pouring the Master Casts.
6. Posterior Palatal Seal.

When you have completed the laboratory procedures which this Section Test covers and are ready to take this test, go to the Caident Center. All Section Tests are on the computer. The proctor in the Caident Center will instruct you on how to take the test. As you take the test, the computer will inform you of your incorrect answers and tell you the correct answer. As soon as you have completed the test, the computer will display your score. Call the proctor to record your score on the Clinic Progress Card.

There are 12 items in this test. The criterion level (the required correct score) is 75%.

BASEPLATES AND THEIR STABILIZATION

OBJECTIVES

Knowledge. Upon completion of this Section you will be able to:

1. Define a baseplate and name the types of baseplates.
2. List the materials from which baseplates are constructed and the reasons that influence the material selected.
3. List the steps in making baseplates and state the criteria for a clinically acceptable product.
4. State the rationale for stabilizing baseplates and the methods available.
5. State the criteria for a stable baseplate.

Skill. You will develop the skills necessary to complete Procedures #5 and #6.

BASEPLATES

A baseplate is a temporary form representing the base of a complete denture which is used for making maxillomandibular (jaw) relation records and for the arrangement of teeth. The potential for errors in transferring jaw relation records to the articulator is reduced when baseplates are both accurately fitting and stable.

Baseplates are adapted over the master casts so that they will fit the mouth comfortably and accurately. However, they must not be adapted into the undercut areas of the master cast.

Baseplates are modified by lining them with a suitable material to gain additional accuracy or stability. Baseplates thus modified are called stabilized baseplates.

There are two types of baseplates. They differ in construction and in materials used.

1. Temporary Baseplates
 - a. Shellac
 - b. Acrylic resin (autopolymerized)
 - c. Vacuum formed vinyl

2. Permanent Baseplates (become the actual base of the denture)
 - a. Acrylic resin (heat-processed)
 - b. Metal
 1. chromium alloy
 2. gold

BASEPLATE MATERIALS

The choice of baseplate material depends on clinical factors such as the availability of space between the residual ridges and the bulk of material required to achieve the necessary strength in the baseplate. Shellac baseplate material is an excellent choice for maxillary baseplates. Autopolymerizing acrylic resin materials of proper thickness are very suitable for mandibular baseplates. The hazard of breakage of the master casts must always be considered when constructing baseplates regardless of the materials selected. However, a blockout of the undercuts will minimize this problem. Vacuum formed vinyl can be used for maxillary and mandibular baseplates; but there is still the hazard of breaking the master cast when using this process.

STABILIZING THE BASEPLATES

Several materials are available for stabilizing baseplates. The choice of material depends on the material used in the baseplate construction. Another purpose of the stabilizing material is to establish a more accurate fit of the baseplate to the master cast. The baseplate stabilizing material must, in combination with the baseplate material, possess rigidity. A light-bodied rubber base or zinc-oxide eugenol impression paste have been used with satisfactory results. When the baseplates are constructed from a shellac baseplate material, the zinc oxide-eugenol impression paste should be used as the stabilizing material. Rubber base used with shellac will not provide the needed rigidity. The light-bodied rubber base will provide sufficient stability when combined with the autopolymerizing acrylic resin baseplate.

REFERENCE

1. Glossary of Prosthodontic Terms. 3rd ed. J. Prosthet. Dent., 20:443-80, Nov. 1968.

OBJECTIVES

Knowledge. Upon completion of this Procedure, you will be able to:

1. State, for the maxillary shellac baseplate and for the mandibular acrylic resin baseplate:
 - a. In sequential order, the steps in fabrication.
 - b. The precautions to take at certain procedural steps in order to avoid potential difficulties.
 - c. The criteria for a clinically acceptable product.
2. From photographs, identify criteria not met.

Skill. Upon completion of this Procedure, you will be able to construct the following:

1. A maxillary shellac baseplate.
2. A mandibular acrylic resin baseplate.

VIDEOTAPES

1. Fabrication of Shellac Baseplates.
2. Mandibular Acrylic Resin Baseplates.

MATERIALS NEEDED FOR PROCEDURE #5

1. Bunsen burner.
2. Alcohol torch.
3. #7 spatula.
4. Asbestos.
5. Rubber bowl.
6. Pink baseplate wax.
7. Liquid foil substitute.
8. Maxillary shellac baseplate.
9. Autopolymerizing acrylic resin.
10. Maxillary and mandibular master casts.
11. Clauss plate shears.
12. File.
13. Arbor bands and chuck.
14. Roller board and roller.

15. Faskut lathe wheel.
16. 703 Dentate Revelation Bur.
17. Vulcanite Bur.
18. Red handled knife and #25 blade.

STEPS FOR FABRICATION OF SHELLAC BASEPLATES

1. Thoroughly wet the maxillary master cast by placing it in a bowl of water for 5-10 minutes prior to baseplate fabrication. Repeat the wetting of the cast as needed during the construction of the baseplate.
2. Through careful examination, find the areas of undercut on the master cast. They are usually located in the labial vestibule or lateral to the tuberosities. When present, these areas must be blocked out prior to baseplate fabrication.
3. Block out the areas of undercut with a small amount of wet asbestos as illustrated in Figure 2:1. If you create too much relief, the baseplate flange will not be adapted closely to the stone model. The flanges will become quite thick when the baseplate is stabilized and tooth setting will be extremely difficult.

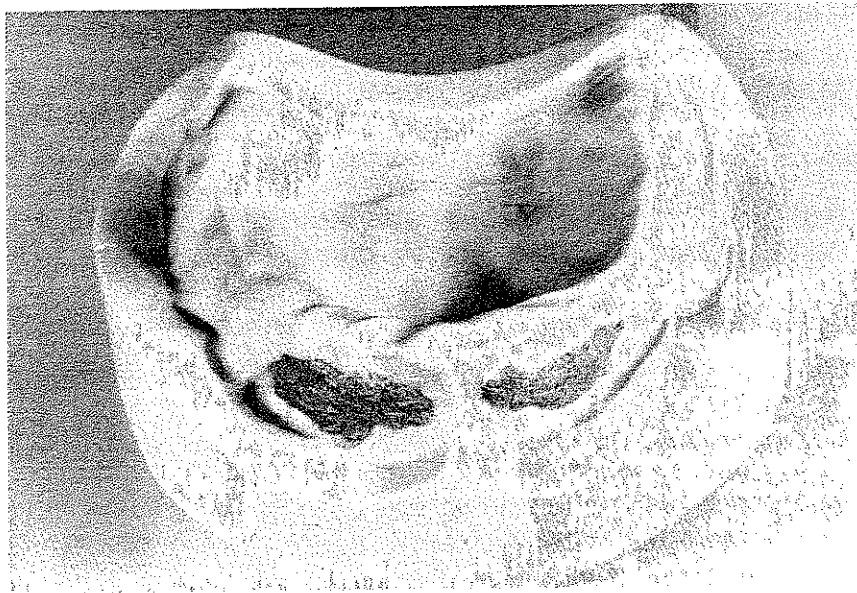


Figure 2:1. The Maxillary Cast with Anterior Undercuts Blocked Out with Wet Asbestos.

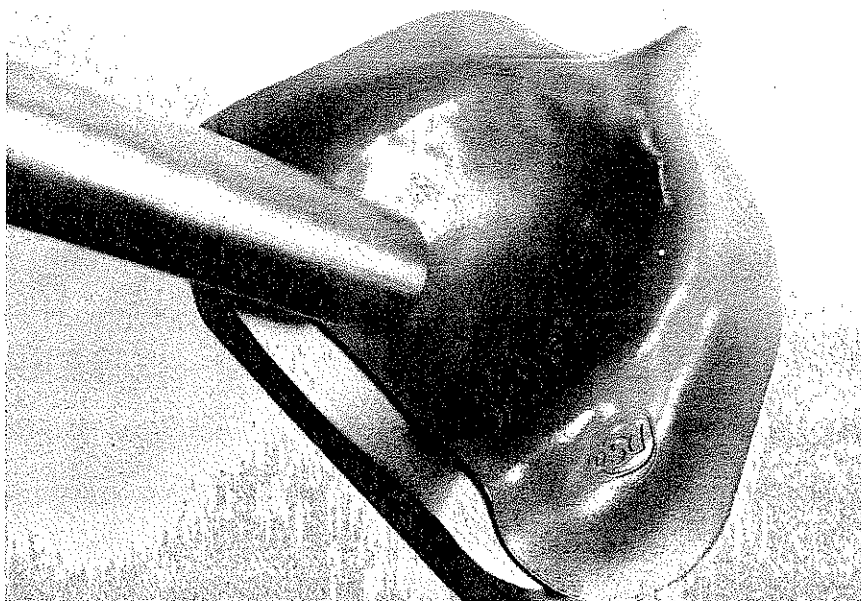


Figure 2:2. The Maxillary Baseplate is Centered Over the Cast and Heated Carefully with the Bunsen Burner.

4. Center the flat baseplate blank on the wet master cast. Heat evenly with a brush flame from the bunsen burner until the baseplate sags onto the master cast surface (Figure 2:2). Use caution. A flame that is too hot or too close to the shellac will scorch it.
5. Mold the baseplate to the surface of the master cast with finger pressure. Wet your fingers to avoid a burn. If you inadvertently adapt the baseplate into an undercut, and cannot remove it from the master cast, heat the area, remove the baseplate, add additional blockout material, and readapt (Figure 2:3).




Figure 2:3. A) Wet Fingers are Used to Apply Pressure and Adapt the Baseplate to the Maxillary Model. B) A Hanau Torch is Used to Reheat the Peripheries for Adaptation or Removal of the Baseplate from an Area of Undercut.

6. Trim the baseplate, leaving 5-6 mms. of excess baseplate material beyond the peripheries of the denture. Thicken the margins of the baseplate by folding the excess baseplate material back onto the flange area. This is most easily accomplished by heating short sections of the flanges with the brush flame of the Hanau torch, then folding the material back with wet fingers or with the #7 spatula (Figure 2:4).
7. The flanges of the baseplate must end short of the eventual denture base periphery, approximately 3 mms., as illustrated in Figure 2:5. Allowing 3 mms. between the peripheries of the baseplate and the eventual denture base outline permits easy removal of the baseplate from the master cast and also avoids scraping or breakage of the model. The baseplate margins should not be sharp.
8. The baseplate should not impinge on the frenula.

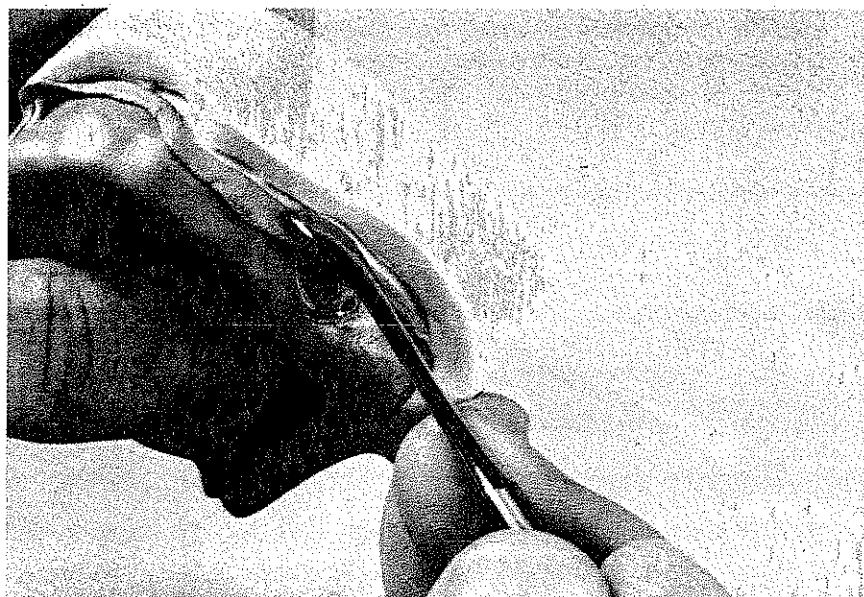




Figure 2:4. The Peripheries of the Baseplate are Trimmed with Plate Shearers to the Proper Length and the #7 Spatula is Used to Fold the Warm Baseplate Peripheries and Create Thicker Margins.

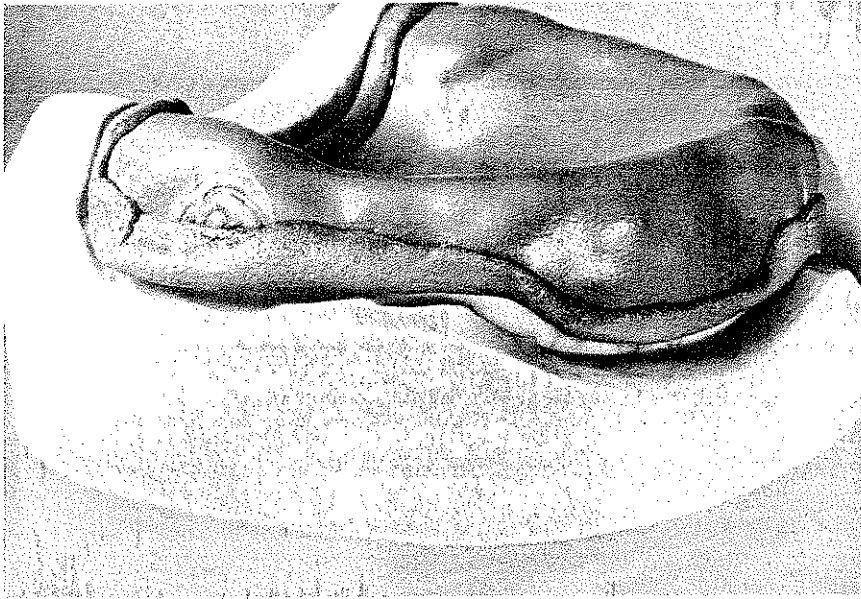


Figure 2:5. The Peripheries of the Baseplate are 3 mms. Short of the Eventual Denture Peripheries.

9. The shellac material, rolled back to create a thickness to the periphery, must be made smooth. Melt the shellac and blend the material with the heated large end of the #7 spatula. Reheat the baseplate flange with a brush flame on the Hanau torch until the shellac surface is softened, then rub the shellac surface with wet fingers until it is smooth (Figure 2:6).


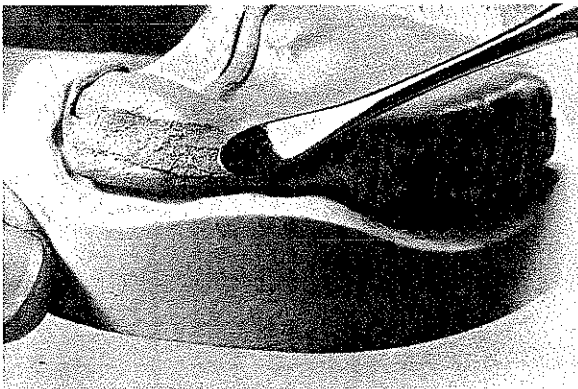


Figure 2:6. The Baseplate is Smoothed with the #7 Spatula and the Hanau Torch.

10. When the peripheries are well molded and smooth, remove the baseplate and chill.
11. Smooth and round the peripheral borders further with the file or selected burs and prepare the labial notch (Figure 2:7).
12. Be sure that the final product is clean and smooth and neat because baseplates go into the patient's mouth.
13. Evaluate your baseplate to see that it satisfies the criteria for an acceptable baseplate (Figure 2:8).

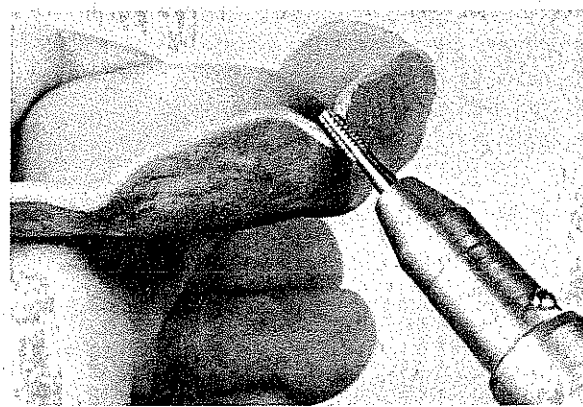
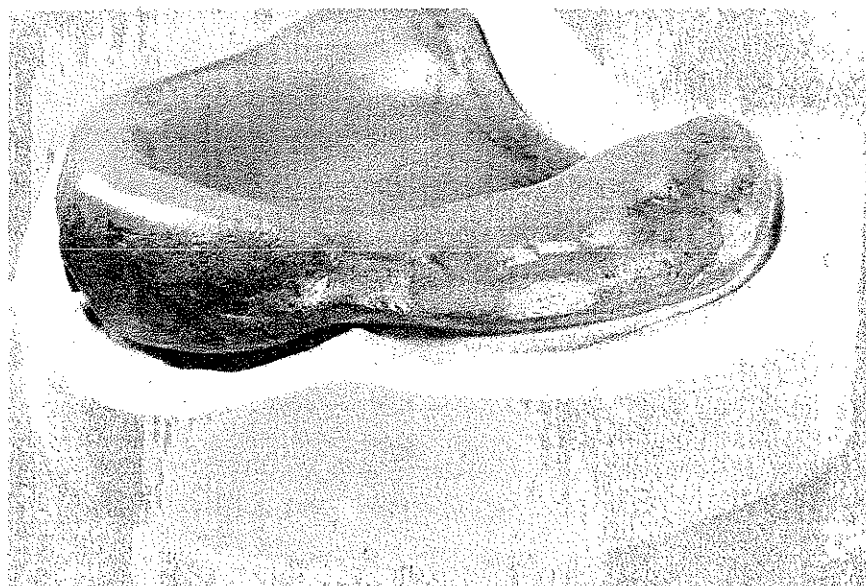


Figure 2:7. The Borders of the Baseplate and the Labial Notch are Adjusted with a File and Bur.

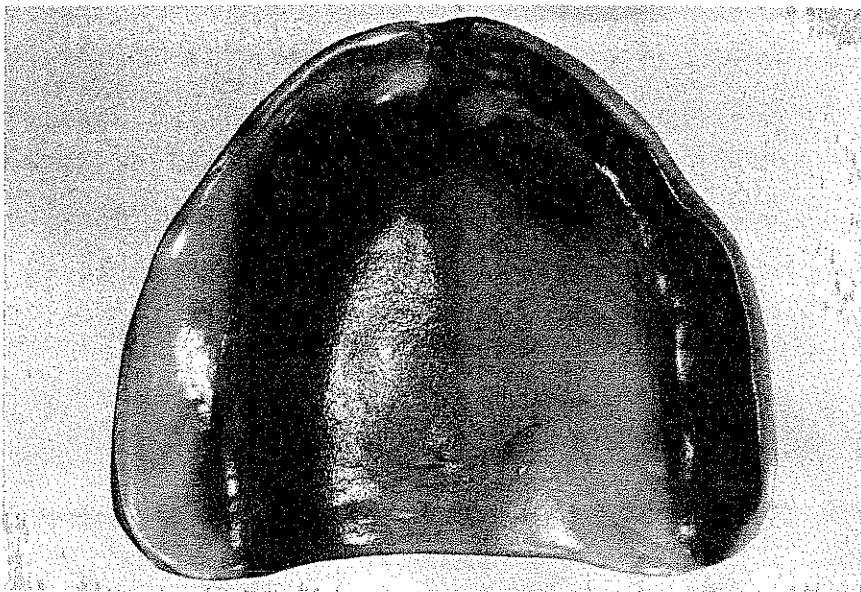
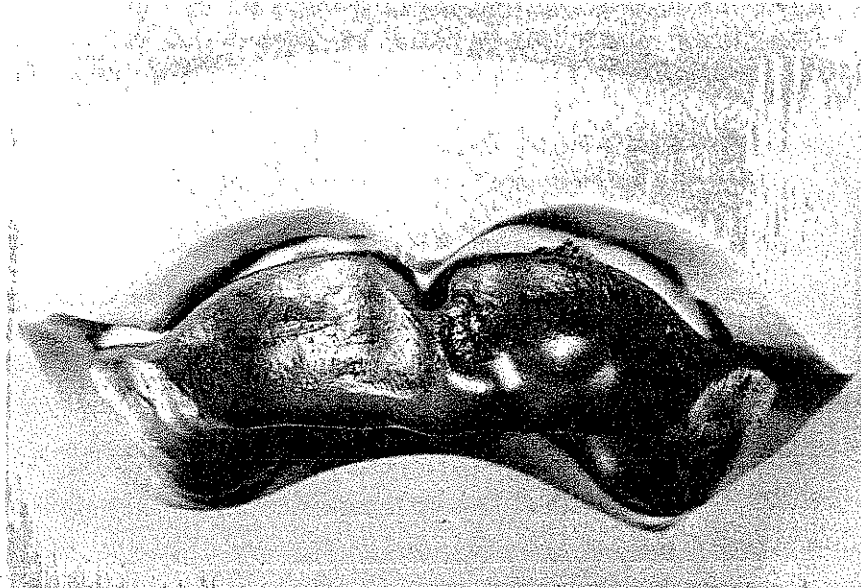


Figure 2:8. The Finished Baseplate Must be Well Adapted, Smooth, and Not Impinge on the Labial Frenum.

STEPS FOR CONSTRUCTING AN ACRYLIC RESIN MANDIBULAR BASEPLATE

1. When using the autopolymerizing acrylic resin material, the master cast must be dry. Relieve the undercuts by using pink baseplate wax instead of the moistened asbestos used for shellac baseplates. Determine the areas of undercut and apply a small amount of molten wax to them (Figure 2:9).
2. When the undercuts have been suitably relieved, paint the master cast and the wax-covered undercuts with a liquid foil substitute.

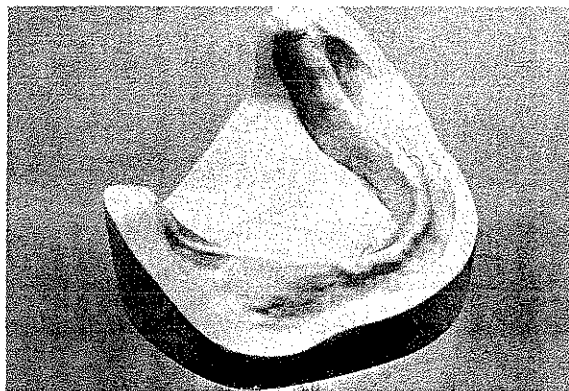
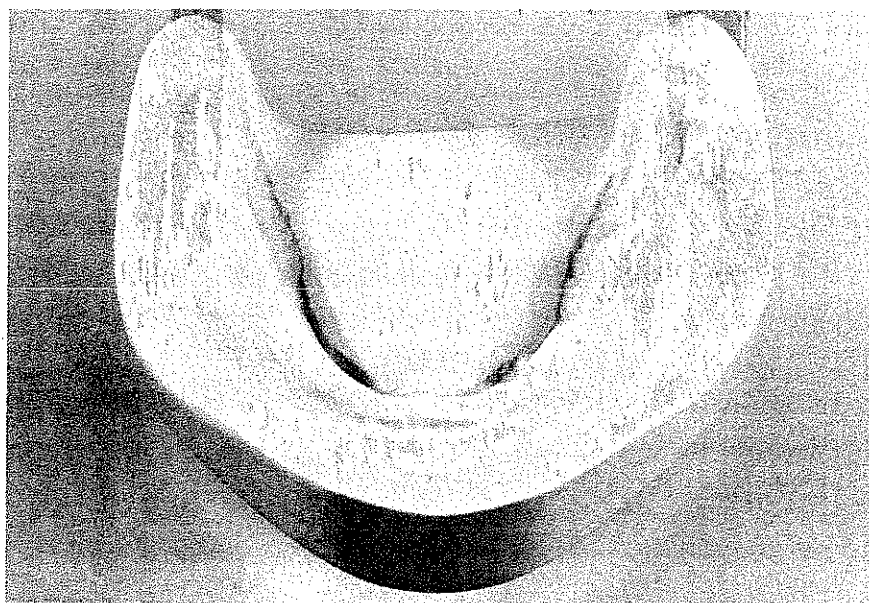


Figure 2:9. The Master Cast Undercuts are Relieved with Wax and Painted with Liquid Foil Substitute.

3. Mix autopolymerizing acrylic resin according to the manufacturer's recommendations. Roll the material using the thin side of the roller board to a thickness of approximately 2 mms. and adapt it over the master cast with light finger pressure. Exercise care here; do not construct a baseplate that is too thick or too thin.
4. After polymerization, remove the baseplate from the master cast, inspect it, and remove any excess material with the lathe mounted arbor band and selected burs (Figure 2:10).

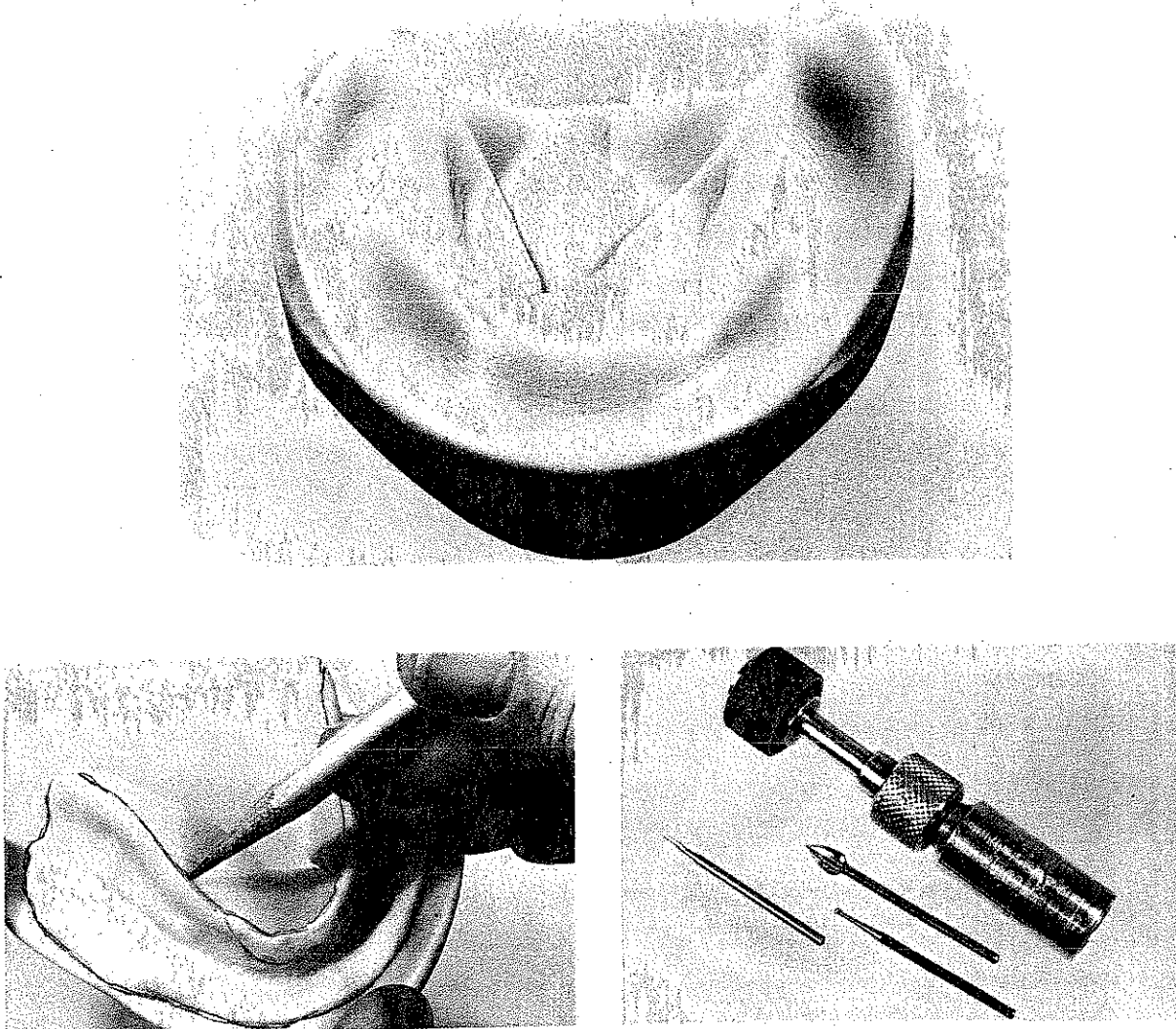


Figure 2:10. The Acrylic Resin Baseplate is Removed from the Master Cast and Trimmed with Assorted Burs and the Lathe Mounted Arbor Band.

5. The flanges of the baseplate must be short of the peripheries of the master cast (about 3 mms.), and rounded without any sharp edges. If frenula are present and recorded on the master casts, relief must be provided for them (Figure 2:11).
6. Evaluate your baseplate to see that it satisfies the criteria for an acceptable baseplate.

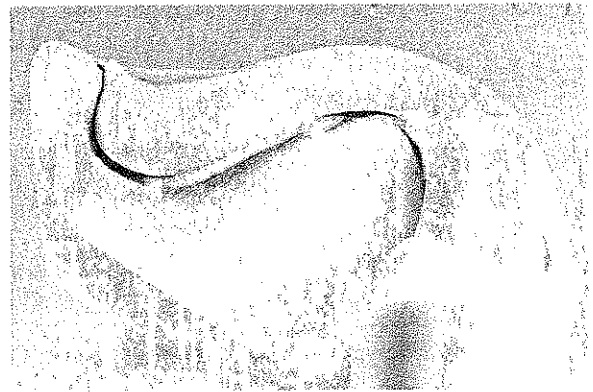
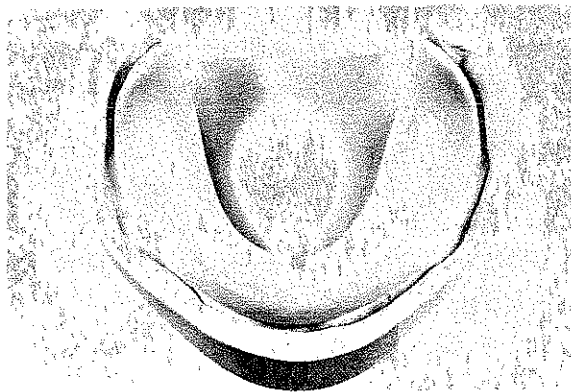
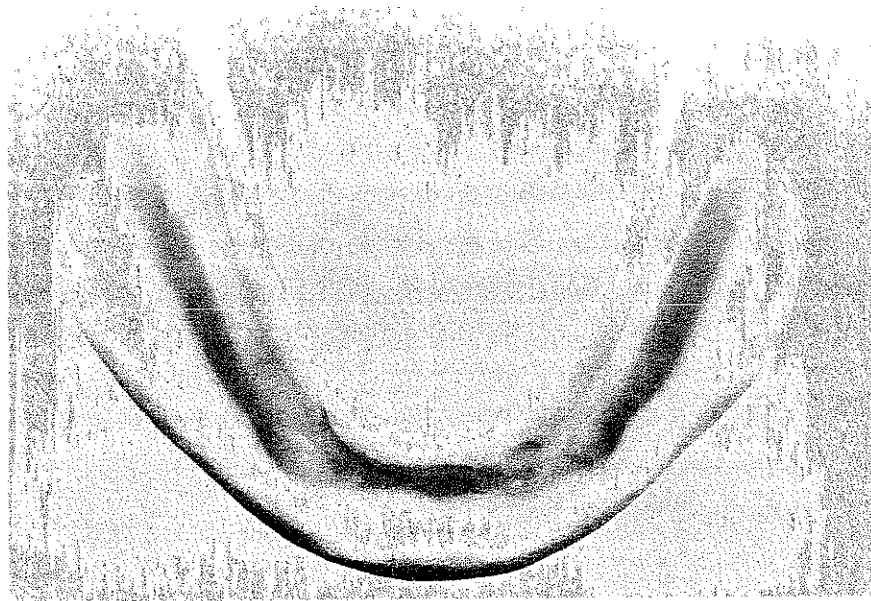


Figure 2:11. A Finished Acrylic Resin Mandibular Baseplate 2-3 mms. Short of the Periphery with the Flange Edges Round and Smooth.

CRITERIA - BASEPLATES

Evaluate your product, using the criteria listed and check the appropriate boxes. After filling in the boxes, take your product and this Study Guide to an instructor for evaluation.

			<u>Meets</u> <u>Criteria</u>	<u>Does not</u> <u>meet Criteria</u>	<u>Comments</u>
1.	The baseplates are well adapted to the master casts.				
	Maxillary		<input type="checkbox"/>	<input type="checkbox"/>	
	Mandibular		<input type="checkbox"/>	<input type="checkbox"/>	
2.	The baseplates are easily removed from the master casts without scraping the models.				
	Maxillary		<input type="checkbox"/>	<input type="checkbox"/>	
	Mandibular		<input type="checkbox"/>	<input type="checkbox"/>	
3.	The flanges are short of the peripheral rolls as recorded on the master casts (approximately 3 mms.)				
	Maxillary	Buccal	Right	<input type="checkbox"/>	<input type="checkbox"/>
			Left	<input type="checkbox"/>	<input type="checkbox"/>
		Labial	Right	<input type="checkbox"/>	<input type="checkbox"/>
			Left	<input type="checkbox"/>	<input type="checkbox"/>
	Mandibular	Buccal	Right	<input type="checkbox"/>	<input type="checkbox"/>
			Left	<input type="checkbox"/>	<input type="checkbox"/>
		Labial	Right	<input type="checkbox"/>	<input type="checkbox"/>
			Left	<input type="checkbox"/>	<input type="checkbox"/>
		Lingual		<input type="checkbox"/>	<input type="checkbox"/>

			<u>Meets</u> <u>Criteria</u>	<u>Does not</u> <u>meet Criteria</u>	<u>Comments</u>
4.	The baseplates do not impinge on the frenula.				
	Maxillary	Buccal Right	<input type="checkbox"/>	<input type="checkbox"/>	
		Left	<input type="checkbox"/>	<input type="checkbox"/>	
		Labial	<input type="checkbox"/>	<input type="checkbox"/>	
	Mandibular	Buccal Right	<input type="checkbox"/>	<input type="checkbox"/>	
		Left	<input type="checkbox"/>	<input type="checkbox"/>	
		Labial	<input type="checkbox"/>	<input type="checkbox"/>	
		Lingual	<input type="checkbox"/>	<input type="checkbox"/>	
5.	The baseplates are clean.				
	Maxillary		<input type="checkbox"/>	<input type="checkbox"/>	
	Mandibular		<input type="checkbox"/>	<input type="checkbox"/>	
6.	The baseplate peripheries are rounded and smooth.				
	Maxillary		<input type="checkbox"/>	<input type="checkbox"/>	
	Mandibular		<input type="checkbox"/>	<input type="checkbox"/>	

PRACTICAL SKILL EXAMINATION #2

OBJECTIVES

To determine if each student is able:

1. To fabricate a maxillary shellac baseplate for an edentulous arch.
2. Time limit 1 1/2 hours.

STEPS IN THE EXAMINATION

1. You will construct a shellac baseplate on a maxillary master cast.
2. When you have completed the examination, place your honor code number and the date on the bottom of the cast and on the baseplate and turn in the baseplate and master cast at the designated area.
3. The shellac baseplate will be evaluated using the criteria listed.

CRITERIA FOR EXAMINATION AND EVALUATION

Shellac Baseplate. Each of the criteria listed can receive a maximum of three points or a total of 15 points for this examination.

1. The baseplate is well adapted to the maxillary cast and reproduces the anatomical landmarks.

POINTS 3. Well adapted, has landmarks.
RECEIVED: 2. Well adapted, lacks landmarks.
 1. Poorly adapted, lacks landmarks.

2. The baseplate is easily removed from the master cast without scraping the cast.

POINTS 3. Easily removed, no scraping.
RECEIVED: 2. Scrapes the cast.
 1. Broken cast.

3. The flanges are short of the peripheral roll as recorded on the master cast (approximately 3 mms.).

POINTS 3. Correct.
RECEIVED: 2. Too short.
 1. Too long or touches periphery.

4. The baseplate does not infringe upon the frenula.

POINTS 3. Correct.
RECEIVED: 2. Too much relief.
 1. No apparent relief.

5. The baseplate is neat, smooth, clean.

POINTS 3. Smooth and clean.
RECEIVED: 2. Rough and clean.
 1. Rough and dirty.

SELF TEST 2
BASEPLATES

(Circle correct response(s) or write brief answers. For correct answers, consult the Answer Key.)

1. What are the two types of baseplates?
 - a. _____:
 - b. _____:
2. The mandibular acrylic baseplate illustrated in Figure T2:1 demonstrates the following error(s):
 - a. Not adapted closely enough.
 - b. Overextended.
 - c. Underextended.
 - d. Flanges are too thin not rolled.

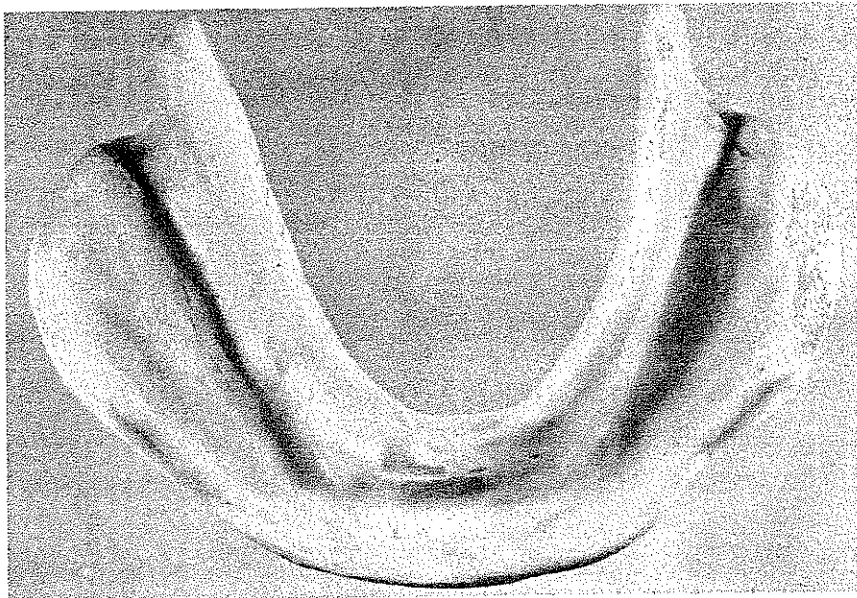


Figure T2:1

3. The choice of baseplate material is based on: (Circle all that apply)
- a. Required bulk.
 - b. Required strength.
 - c. Required flexibility.
 - d. Available interarch distance.
 - e. Ability to attain a polished finish.
4. The maxillary shellac baseplate illustrated in Figure T2:2 demonstrates the following error(s):
- a. Not adapted closely enough.
 - b. Overextended.
 - c. Underextended.
 - d. Flanges are too thin not rolled.
 - e. Labial notch excessively relieved.

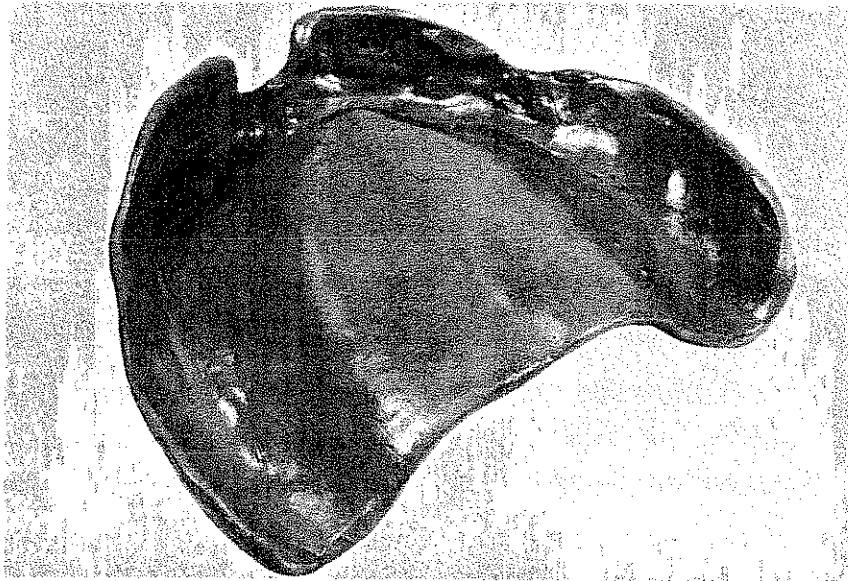


Figure T2:2

5. The flanges of the baseplate should end ___ mms. short of the periphery of the denture base.
6. The shellac baseplate illustrated in Figure T2:3 demonstrates the following error(s):
 - a. Not adapted closely enough.
 - b. Overextended.
 - c. Underextended.
 - d. Flanges are too thin not rolled.
 - e. Notches are excessively relieved.

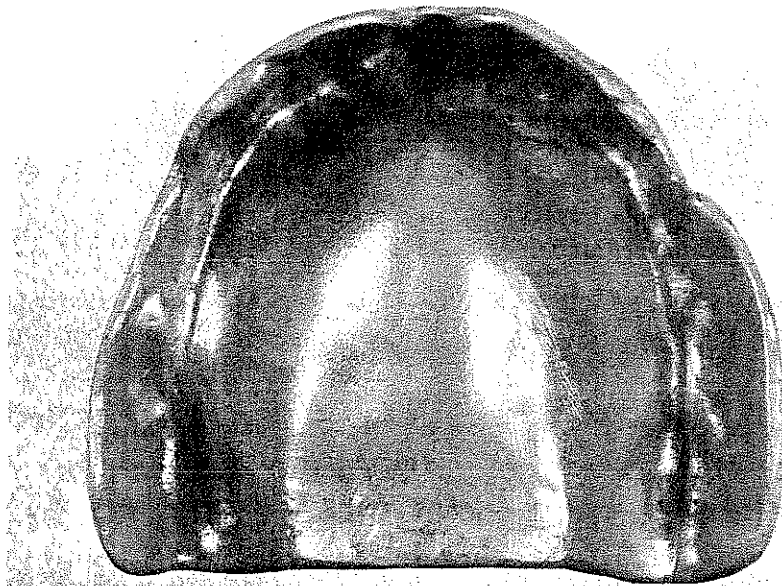


Figure T2:3


7. To avoid breaking the master cast when making a maxillary shellac baseplate, you should:
 - a. Be sure the master cast is thoroughly dry.
 - b. Lubricate the master cast with Vaseline.
 - c. Keep the flanges short of the denture base outline.
 - d. Wet the master cast.
 - e. Block out undercuts with asbestos.

8. The shellac baseplate illustrated in Figure T2:4 demonstrates the following error(s):
 - a. Not adapted closely enough.
 - b. Overextended.
 - c. Underextended.
 - d. Flanges are too thin not rolled.
 - e. Labial notch excessively relieved.

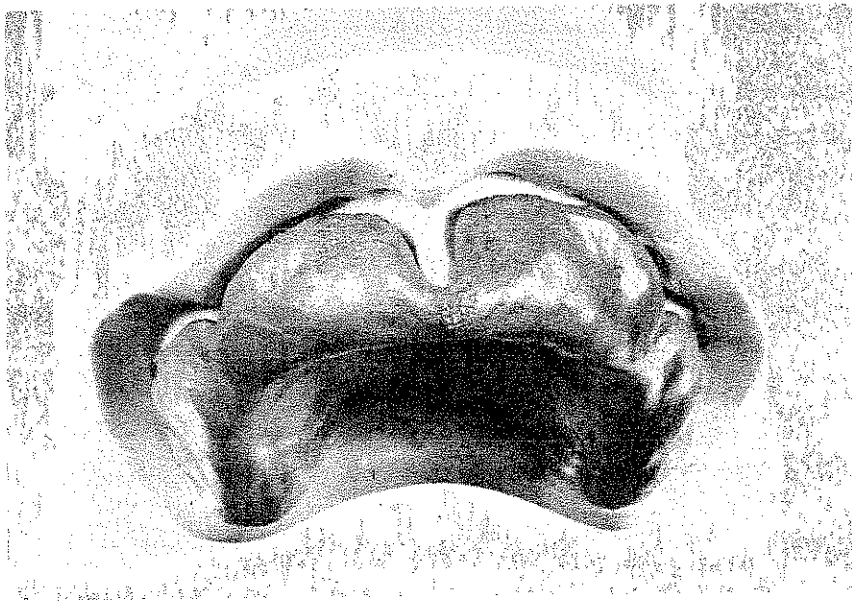

Figure T2:4

9. _____ should be the material of choice to block out the undercuts when making an acrylic resin baseplate.
10. The thickness of a mandibular acrylic resin baseplate prior to stabilization is:
1. 1 mms.
 2. 2 mms.
 3. 3 mms.
 4. 4 mms.



OBJECTIVES

Knowledge. Upon completion of this Procedure you will be able to:

1. State, for the maxillary and mandibular baseplates, in sequential order, the steps in stabilization.

Skill. Upon completion of this Procedure, you will be able to perform the following:

1. Stabilize the maxillary shellac baseplate with a zinc-oxide and eugenol impression paste.
2. Stabilize the mandibular acrylic resin baseplate with a light-bodied rubber base.
3. Add a wax occlusal rim to the mandibular baseplate.

VIDEOTAPES

1. Stabilization of Baseplates.
2. Mandibular Wax Occlusal Rim.

MATERIALS NEEDED FOR PROCEDURE #6

1. Maxillary and mandibular baseplates. (Procedure #5)
2. 1 pkg. Kerr light-bodied rubber base impression material.
3. 1 pkg. Coe Zinc-oxide and eugenol impression paste.
4. Tinfoil, .001 in. thickness.
5. Cotton rolls (2).
6. Rubber base adhesive.
7. #7 spatula.
8. Mixing sticks.
9. Mixing pad.

STEPS IN STABILIZING THE MAXILLARY SHELLAC BASEPLATE

Prior to beginning this procedure, check your baseplate to assure that the flanges end short of the peripheries (3 mms.) and are well adapted.

1. Cleanse the master cast of all debris and residual asbestos. If the asbestos relief for the labial flanges was excessive, you should wet the cast, reseal the baseplate and gently flame the flange areas with the Hanau torch. Carefully readapt the labial flanges and then remove the baseplate before the flanges cool. This will allow you to remove the baseplate without breaking the master cast (Figure 2:12).






Figure 2:12. Carefully Readapt the Labial Flanges in Areas where the Asbestos Relief was Excessive and the Flange is too Far Away from the Surface of the Cast.

2. Adapt a four-inch square of tinfoil (.001 in. thickness) over the anatomical portion of the maxillary master cast. Burnish it into all undercuts and peripheral extensions with a cotton roll.
3. Heat the baseplate carefully on the tissue surface and seat it over the tinfoil. Heating permits proper seating of the baseplate on the tinfoiled master cast without fracturing the baseplate (Figure 2:13).



A



B

Figure 2:13. A) Tinfoil .001 mm. Thickness is Burnished Over the Anatomical Portion of the Master Cast and, B) The Baseplate after Being Heated on the Tissue Surface, is Carefully Seated on the Tinfoiled Master Cast.

4. Prepare a mix of zinc oxide-eugenol impression paste according to the manufacturer's recommendations and paint a thin wash on the tissue surface of the baseplate. A minimal amount of impression material is required for stabilization. Approximately 2 inches of base material, and an equal length of catalyst, is recommended.
5. Seat the baseplate and impression material over the tinfoiled master cast. Press it into place until the baseplate is completely seated and the impression paste appears at the peripheries (Figure 2:14).
6. When the impression paste has set, carefully remove the stabilized baseplate from the master cast. Inspect the tissue surface of the impression material for voids. If any voids are found, remove the tinfoil and impression material and repeat the procedure.




Figure 2:14. A) Zinc Oxide and Eugenol Paste is Placed on the Tissue Surface of the Maxillary Baseplate, and B) the Baseplate is Seated on the Foil Covered Master Cast.

7. Use a sharp scalpel blade to remove excess impression material and tin foil at the peripheries. Create smooth edges. All residual impression paste must be removed from the baseplate. For final cleansing, wipe the baseplate with gauze moistened with oil of orange.
8. Flow pink baseplate wax on any of the edges of the baseplate which are not smooth (Figure 2:15).

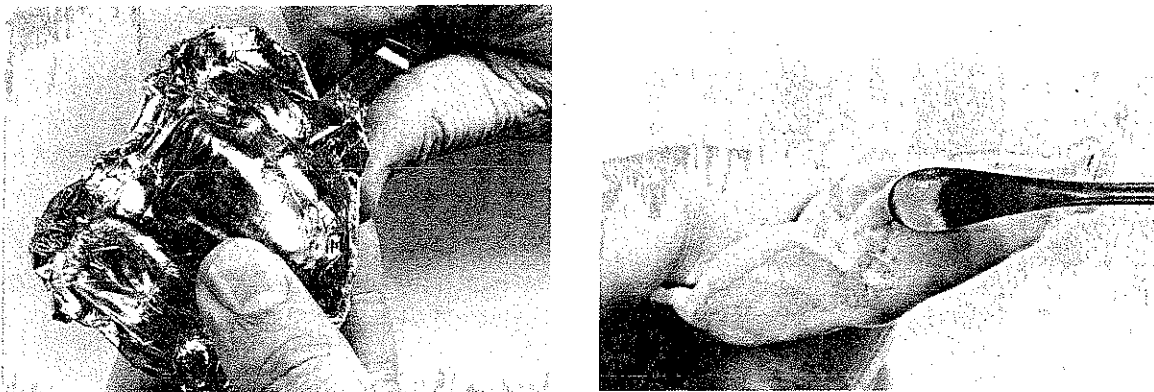


Figure 2:15. The Excess Impression Material and Tinfoil is Removed and Pink Baseplate Wax is Flowed Over the Edges of the Baseplate to Make Them Smooth.

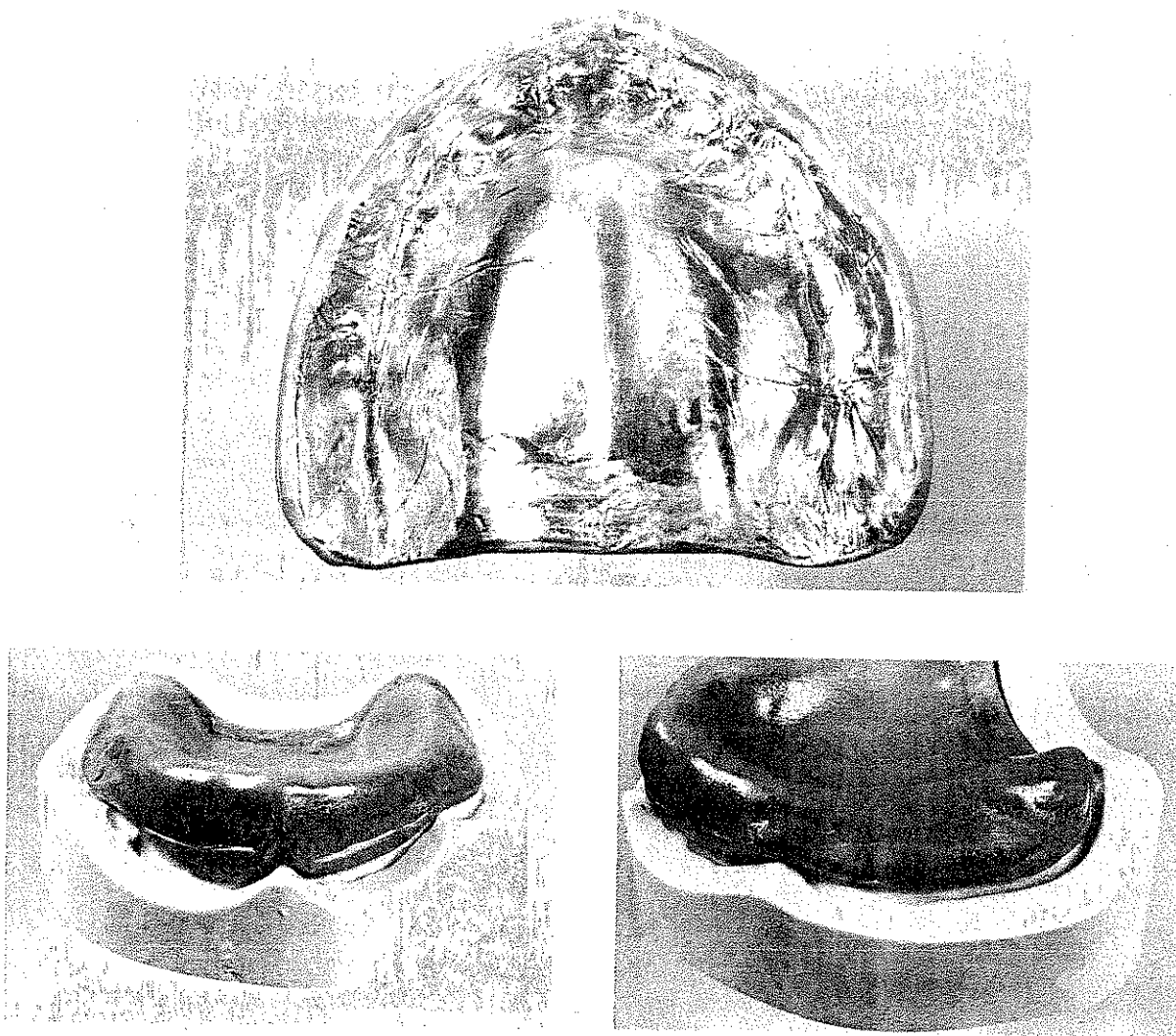


Figure 2:16. The Stabilized Maxillary Baseplate.

9. Evaluate the stabilized maxillary baseplate to see that it fulfills the criteria (Figure 2:16).

STEPS FOR STABILIZING THE MANDIBULAR ACRYLIC RESIN BASEPLATE

Prior to beginning this procedure, check the peripheries of the baseplate to ensure that they are short of the borders as recorded on the master cast. The flanges must be 3 to 4 mms. short of the peripheries.

1. The mandibular master cast must be cleansed of all residual wax that has been used in the blocking out of undercuts.
2. After removing the wax from the master cast, mold tin-foil to the master cast and paint the exposed surface of the tinfoil with the rubber base adhesive.
3. Also apply the adhesive to the tissue side of the acrylic resin baseplate and allow the painted surfaces of the baseplate and the tinfoil to dry for approximately 10 minutes (Figure 2:17).

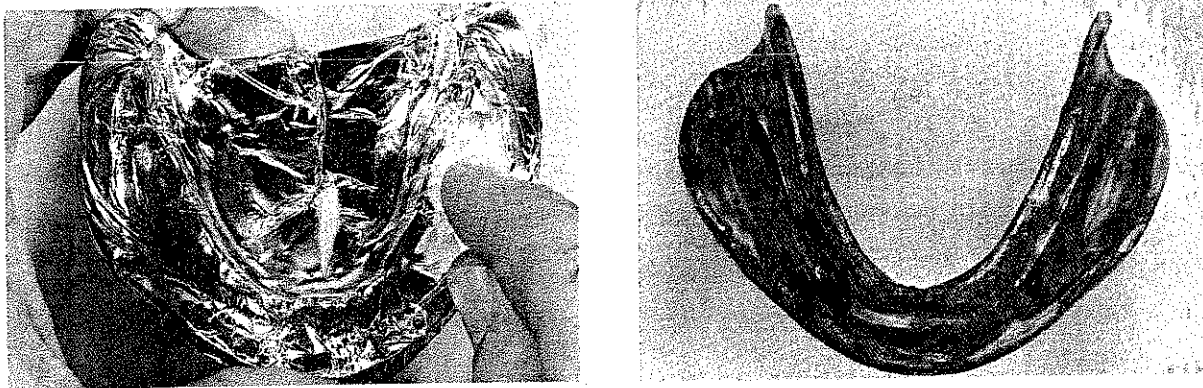


Figure 2:17. Burnish the Tinfoil Over the Anatomic Portion of the Master Cast. Be Sure to Apply the Adhesive to Both the Tinfoil and Baseplate.

4. Make a mix of light-bodied rubber base according to directions, then paint it in a thin wash over the tissue surface of the baseplate. Since this is a thin wash, it is not necessary to use a great deal of impression material. Use approximately 2-inch lengths of base and catalyst. Carefully position the baseplate on the tin-foiled master cast and properly seat it (Figure 2:18).

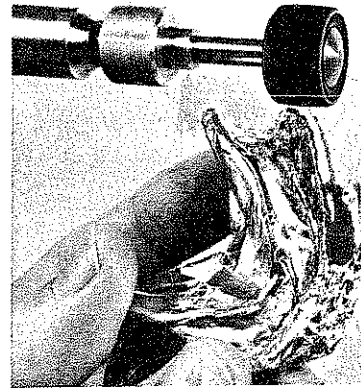
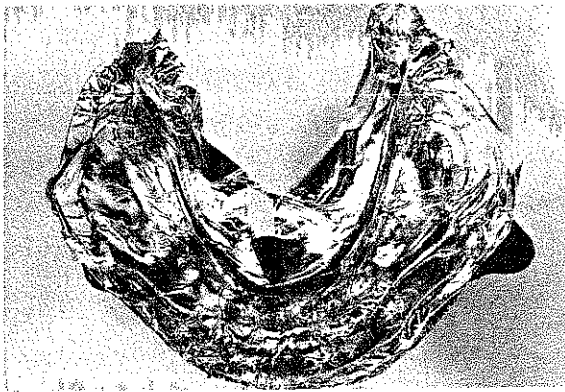
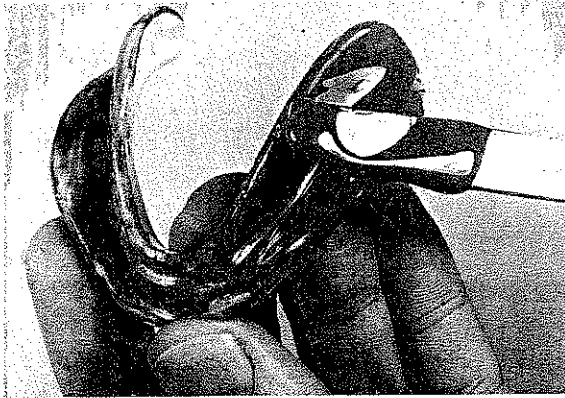


Figure 2:18. A Thin Wash of Rubber Base is Placed Over the Tissue Surface of the Baseplate and the Baseplate is Seated on the Master Cast. After the Rubber Sets, the Baseplate is Inspected for Voids.

5. Following the appropriate waiting period (10 minutes minimum), remove the stabilized baseplate and inspect it for voids.
6. Adjust the peripheries with a lathe mounted arbor band (Figure 2:18). Do not cover the edges of the flanges with rubber base material or with tinfoil. Rather, cut back the impression material to expose the acrylic resin. Rubber peripheral edges cause the baseplate to bounce on the master cast, an undesirable situation.
7. Cleanse the excess stabilizing materials from the baseplate and verify its accuracy by reseating the baseplate on the master cast (Figure 2:19).

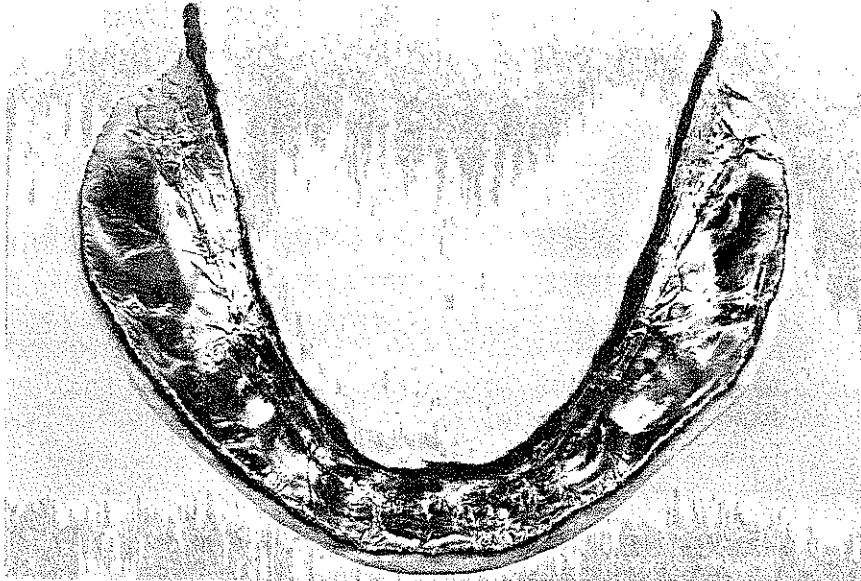

Figure 2:19. The Stabilized Mandibular Baseplate.

STEPS IN ADDING A WAX OCCLUSAL RIM TO THE MANDIBULAR BASEPLATE

1. As a last step in the stabilization of the mandibular baseplate, adapt a wax occlusal rim using the same guidelines as outlined for the wax occlusal rim on the mandibular impression tray.
2. Apply sticky wax in several places along the top of the baseplate.
3. Heat one sheet of baseplate wax, and roll it into a cylinder to form the wax occlusal rim.
4. While the wax rim is still soft, form and adapt it to the baseplate with your fingers.
5. Seal the wax rim to the acrylic resin baseplate with the large end of a #7 spatula.
6. Modify the occlusal rim to its proper form, and cut and shape it with the red-handled knife or with a hot wax spatula to meet the criteria listed (Figure 2:20).
7. Evaluate your product.

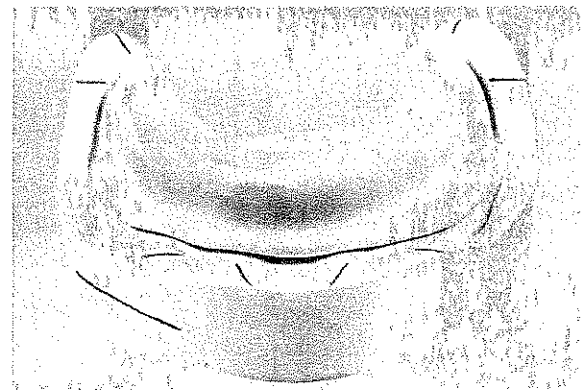
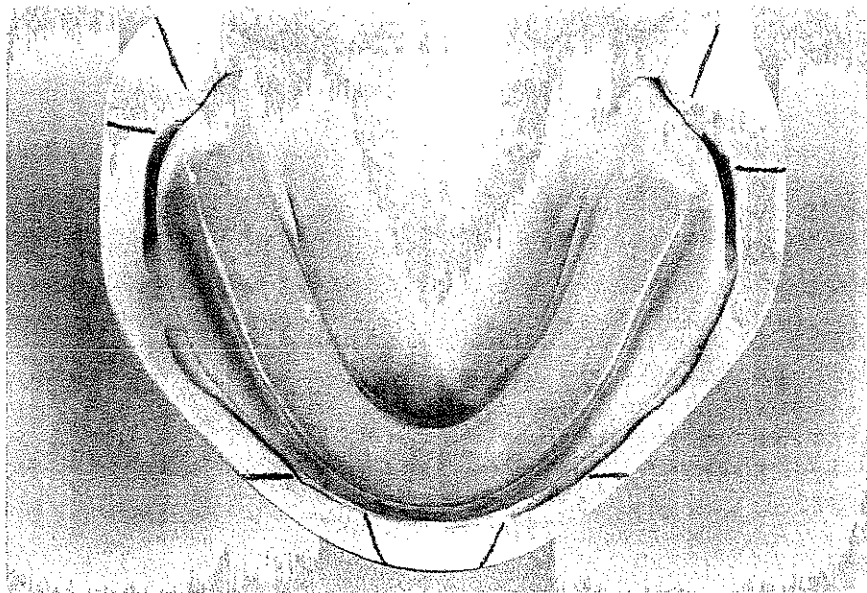
Figure 2:20. The Stabilized Mandibular Baseplate to Which Has Been Added the Wax Occlusal Rim.

CRITERIA - STABILIZED BASEPLATES

Evaluate your product using the criteria listed and check the appropriate boxes. After filling in the boxes, take your products and this Study Guide to an instructor for evaluation.

	<u>Meets</u> <u>Criteria</u>	<u>Does not</u> <u>meet Criteria</u>	<u>Comments</u>
1. The baseplates are well adapted to the maxillary and mandibular casts and do not exhibit any rocking.			
Mandibular	<input type="checkbox"/>	<input type="checkbox"/>	
Maxillary	<input type="checkbox"/>	<input type="checkbox"/>	
2. The peripheries of the baseplates are rounded and smooth.			
Mandibular	<input type="checkbox"/>	<input type="checkbox"/>	
Maxillary	<input type="checkbox"/>	<input type="checkbox"/>	
3. The outer surfaces of the baseplates are free of stabilizing materials.			
Mandibular	<input type="checkbox"/>	<input type="checkbox"/>	
Maxillary	<input type="checkbox"/>	<input type="checkbox"/>	
4. The baseplates are short of the peripheries of the master cast. (Approximately 3-4 mms.)			
Mandibular	<input type="checkbox"/>	<input type="checkbox"/>	
Maxillary	<input type="checkbox"/>	<input type="checkbox"/>	
5. The mandibular baseplate has a properly formed wax occlusal rim.			
	<input type="checkbox"/>	<input type="checkbox"/>	

CRITERIA FOR WAX OCCLUSAL RIM

<u>Position</u>	<u>Meets Criteria</u>	<u>Does not meet Criteria</u>	<u>Comments</u>
1. Centered buccal-lingually over the line drawn along the length of the residual ridge.	<input type="checkbox"/>	<input type="checkbox"/>	
2. 1-2 mms. below the top of the retromolar pad.	<input type="checkbox"/>	<input type="checkbox"/>	
3. Parallel to the residual ridge.	<input type="checkbox"/>	<input type="checkbox"/>	
4. Labially oriented.	<input type="checkbox"/>	<input type="checkbox"/>	
<u>Dimension</u>			
1. Width of rim in posterior region is 10 mms.	<input type="checkbox"/>	<input type="checkbox"/>	
2. Width in anterior region is 7-10 mms. (Slightly less than in posterior region.)	<input type="checkbox"/>	<input type="checkbox"/>	
3. Flat occlusal surface.	<input type="checkbox"/>	<input type="checkbox"/>	
<u>Finish</u>			
1. Wax sealed to impression tray.	<input type="checkbox"/>	<input type="checkbox"/>	
2. No voids in wax.	<input type="checkbox"/>	<input type="checkbox"/>	
3. Wax surface smooth.	<input type="checkbox"/>	<input type="checkbox"/>	

COMPUTER-GENERATED SECTION TEST 2

You are now ready to take Computer-Generated Section Test 2, which will cover:

1. Baseplates.
2. Stabilizing the Baseplates.

When you have completed the laboratory procedures which this Section Test covers and are ready to take this test, go to the Caident Center. All Section Tests are on the computer. The proctor in the Caident Center will instruct you on how to take the test. As you take the test, the computer will inform you of your incorrect answers and tell you the correct answer. As soon as you have completed the test, the computer will display your score. Call the proctor to record your score on the Clinic Progress Card.

There are 6 items in this test. The criterion level (the required correct score) is 67%.

MAXILLOMANDIBULAR JAW RELATIONS

OBJECTIVES

Knowledge. Upon completion of this Section, you will be able to:

1. Define the types of face-bows.
2. Describe the arbitrary method of face-bow transfer and the mounting of the maxillary master cast.
3. List the goals in establishing maxillomandibular jaw relations for the edentulous patient.
4. Define the terms related to registering and transferring jaw relation records.
5. Describe the steps in registering and transferring maxillomandibular jaw relations for the edentulous patient.
6. Describe the methods used in mounting the mandibular master cast and setting the articulator.

Skills. Although you will not perform these Procedures in the Preclinical course, you should know how they are done in order to better understand their significance in the overall management of the complete denture patient.

THE FACE-BOW TRANSFER

The face-bow is a caliper-like device that is used to record the relationship of the maxillary arch to the opening axis of the jaws and to orient the maxillary master cast in the same relationship to the opening axis of the articulator. There are two methods of face-bow transfer used in complete denture prosthodontics; one uses the arbitrary axis and the other the true hinge axis to relate the face-bow to the head.

Arbitrary Hinge Axis. There are two common technics for locating the arbitrary hinge axis: the automatic method using an ear rod type face-bow, and the measurement method.

Kinematic Hinge Axis. The "true" hinge axis may be located with the kinematic face-bow or hinge axis locator. The kinematic face-bow is placed on the face over accurately located points on the skin, which fall on the "true" opening axis of the mandible.

In the construction of complete dentures, the arbitrary method of the face-bow transfer is usually used. The face-bow transfer records the arbitrary position of the hinge axis or condyle of the patient, and is used to orient the maxillary master cast to the opening and closing axis of the articulator. Three reference points are required in the face-bow transfer, and the points used will vary with the type of face-bow that is selected.

Location of the "Third Point of Reference." The location of any free body (maxilla) in space requires three points of reference. The condyles serve as two of these three points. There are several methods used to locate the third point: nasion, the infra-orbital notch, the parallelism of the maxillary residual ridge, the relationship of the bitefork to either the incisal pin of the articulator or a facial plane.

The Hanau Face-bow Measurement Method. The three points of reference of the simple Hanau arbitrary face-bow that we will use in the clinic are:

1. Two points located bilaterally, 13 mms. anterior to the tragus of the ear on a line from the middle of the tragus of the ear to the outer canthus of the eye.
2. The bitefork oriented perpendicular to the long axis of the face.

The long axis of the face is defined as a line that extends from the bridge of the nose (nasion) through the ala of the nose extending inferiorly.

The Hanau Automatic (ear rod) Face-bow Method. The three points of reference for the Hanau ear rod face-bow that will be used in the clinic are:

1. Positioning bilaterally the face-bow's earpiece into the external auditory meatus of the ear.
2. The bitefork oriented perpendicular to the long axis of the face and orienting the bitefork to a specific marking on the articulator's incisal pin when mounting the maxillary cast.

MAXILLOMANDIBULAR JAW RELATIONS

The Problem. It is quite difficult to establish the relationship of the mandible to the maxilla when the patient is edentulous. We need to determine: 1) how far vertically the jaws should be separated when the denture teeth are in contact, and 2) what horizontal jaw-to-jaw relationships should exist when the denture teeth are in maximum contact.

The Solution. The goals of establishing intermaxillary relations for the denture patient are: 1) to establish a correct vertical dimension for the patient's jaws, and 2) to determine the proper horizontal relationships of the patient's jaws. Establishing these relationships is essential for the success of the complete denture service.

Vertical Dimension of the Jaws. The Occlusal Vertical Dimension (OVD) of the jaws when the teeth are in contact is defined as the vertical dimension of the jaws when the teeth or occlusal rims are in contact in centric occlusion.

To determine this dimension (OVD) for an edentulous patient, other jaw-to-jaw relationships, which are measurable, must first be established. Two measurable relationships which must be used are:

1. Physiologic Rest Position (PRP) - The habitual postural position of the mandible when the patient is resting comfortably in the upright position and the condyles are in a neutral unstrained position in the glenoid fossae. Ramfjord and Ash refer to this as postural rest position.³
2. Interocclusal Distance (ID) - The distance between the occluding surfaces of the maxillary and mandibular teeth when the mandible is in its physiologic rest position. Ramfjord and Ash refer to this as a space which is usually present between the occlusal surfaces of the maxillary and mandibular teeth when anti-gravity tonus is maintained.³

The Interocclusal Distance is also referred to as interocclusal clearance, interocclusal gap, freeway space, and interocclusal rest space.

It is generally accepted that some interocclusal distance is absolutely necessary to the success of complete dentures, so an arbitrary distance of 2-3 mms. is used as an initial interocclusal distance. This measurement may be modified following esthetic and phonetic tests, but it is always true that the physiologic vertical dimension of the jaws at physiologic rest position should be greater than the occlusal vertical dimension.

After the PRP (Physiologic Rest Position) and the ID (Interocclusal Distance) have been located and recorded, the OVD (Occlusal Vertical Dimension) can be established simply by subtracting the ID from the PRP:

$$\text{OVD} = \text{PRP} - \text{ID}$$

The OVD is the vertical opening of the mandible at which the denture teeth will be set in contact (Figure 3:1).

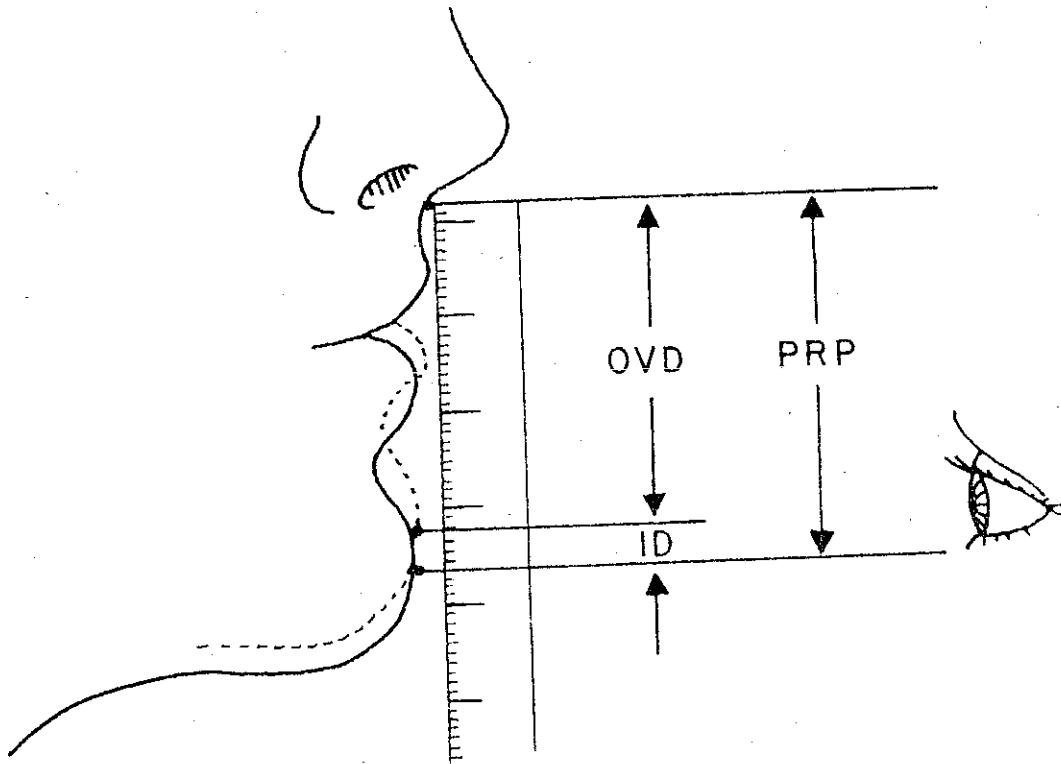


Figure 3:1. Determination of the (OVD) Occlusal Vertical Dimension.

Horizontal Relations of the Jaws (Centric Relation and Centric Occlusion). The classical prosthodontic definition of centric relation (CR) is: The jaw relation when the condyles are in the most unstrained position in the glenoid fossae from which lateral movement can be made at any given degree of jaw separation. After you establish a suitable vertical dimension (OVD) you may record the centric relation.

Centric relation has been a confusing term for many years. It is easily confused with the term centric occlusion. The prosthodontic definition of centric occlusion (CO) is: The occlusion of the teeth when the mandible is in centric relation to the maxilla. A definition of centric occlusion for dentulous persons is: the jaw-to-jaw relationship when the teeth are in maximum occlusal contact. Usually thought to be different from centric jaw relation. The mandible of most dentulous patients can be moved slightly distal (average 1-2 mms.) from the position where the teeth are in maximum occlusal contact (CO).⁴ This indicates that there is a difference between centric relation and centric occlusion. It is helpful to remember that centric relation (CR) is a bone-to-bone (maxilla to mandible) relationship and that centric occlusion (CO) is a tooth-to-tooth (mandibular teeth to maxillary teeth) relationship.⁵

In the field of complete denture prosthodontics, it is commonly stated that CO = CR. However, it may be stated, that CO coincides with CR because the denture teeth (planned occlusion) are set to occlude properly (CO) when the jaws are in centric relation (CR). Dr. Richard Kingery made a statement that helps maintain the distinction between CO and CR. He wrote, . . .we record centric relation, we establish centric occlusion.⁶

REFERENCES

1. Glossary of Prosthodontic Terms, 3rd Edition, J. Prosth. Dent., 1968. 20:444-480.
2. Ash, M.M., et al. Introduction to Functional Occlusion. School of Dentistry, University of Michigan, 1975, pp. 94-101, 127-128.
3. Ramfjord, S.P., and Ash, M.M. Occlusion, 2nd Edition. Philadelphia: W. B. Saunders Co., 1971. pp. 12-14.
4. Posselt, U. Physiology of Occlusion and Rehabilitation. Philadelphia: F.A. Davis Co., 1966. p. 58.
5. Avant, W.E. Using the Term "Centric", J. Pros. Dent., 1971. 25:12-18.
6. Kingery, R.H. Review of Some of the Problems Associated with Centric Relation. J. Pros. Dent., 1952. 2:307-319.

OBJECTIVES

Knowledge. Upon completion of this Procedure you will be able to:

1. State, in sequential order, the steps in securing a face-bow transfer and in mounting a maxillary master cast.

Skill. Although you will not perform these Procedures in the Preclinical course, you should understand how they are done in order to better perform later Procedures in this course and in your clinical experiences.

VIDEOTAPE

1. Face-bow Transfer of a Maxillary Cast.

MATERIALS NEEDED FOR PROCEDURE #7

1. Hanau face-bow and bitefork.
2. Pink baseplate wax.
3. Hanau H-2 articulator and mounting ring.
4. Rubber bowl.
5. Kerr laboratory spatula.
6. Maxillary master cast and stabilized baseplate.
7. Impression plaster.
8. Faskut stone and chuck.
9. Bunsen burner.
10. #7 spatula.
11. 1 mm. ruler.
12. Red handled knife #25 blade.
13. Mounting jack.
14. Straight incisal pin.

STEPS IN PERFORMING THE FACE-BOW TRANSFER USING THE HANAU MEASUREMENT FACE-BOW METHOD

1. Soften one piece of pink baseplate wax uniformly and roll it into a cylinder shape. Carefully adapt the rolled wax to the maxillary bitefork.
2. Place yellow sticky wax along the ridge crest area of the maxillary baseplate (Figure 3:2).

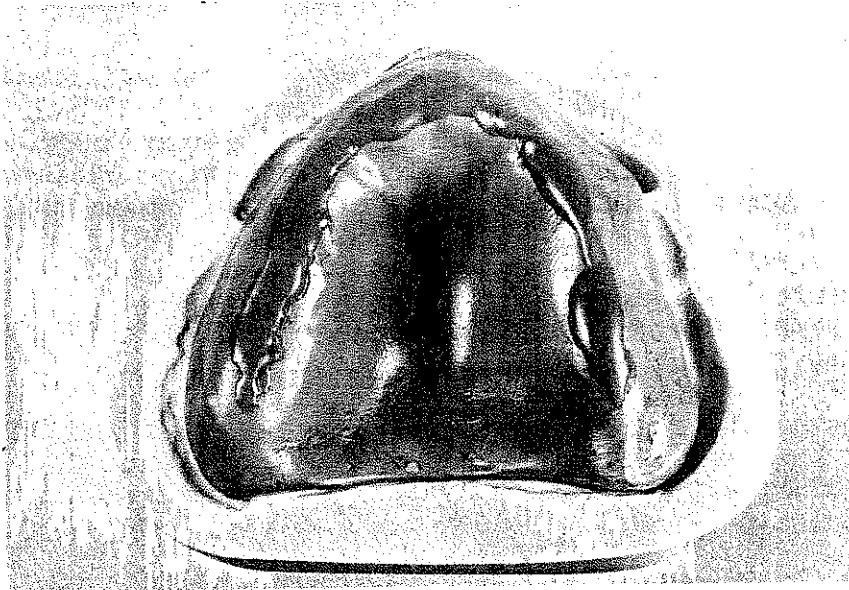


Figure 3:2. Sticky Wax is Placed on the Ridge Area of the Maxillary Stabilized Baseplate.

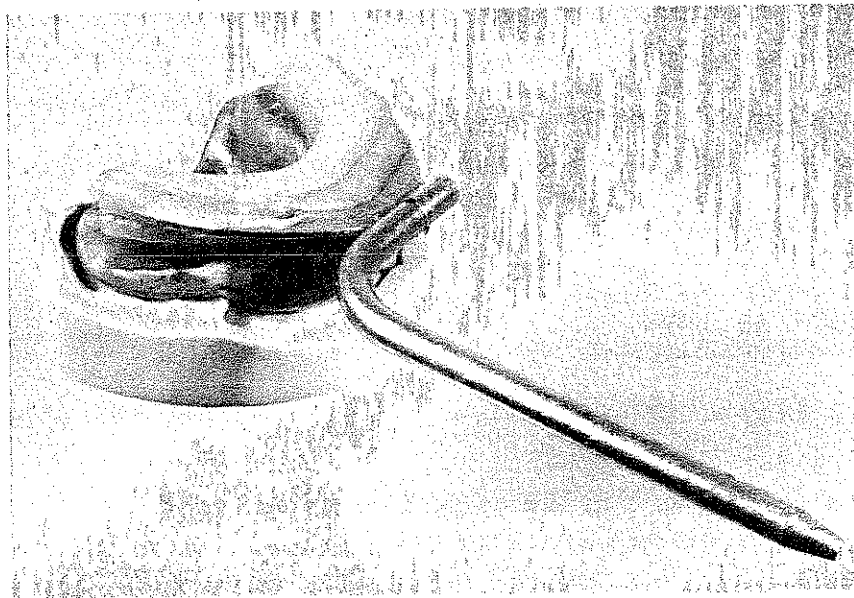


Figure 3:3. The Bitefork is Attached to the Maxillary Stabilized Baseplate Parallel to the Residual Ridge.

3. Heat the pink wax attached to the bitefork, then seat it over the maxillary baseplate and seal it to the baseplate. Make certain that the stem of the bitefork is parallel to the maxillary residual ridge (Figure 3:3).
4. Apply sticky wax to several posterior areas of the occlusal surface of the pink baseplate wax on the bitefork and attach two cotton rolls, one on each side of the arch (Figure 3:4).
5. Place the baseplate with bitefork and cotton rolls in the patient's mouth and ask him to stand and to bite gently against the cotton rolls using his mandibular baseplate and wax occlusal rim, or his existing mandibular denture. The bitefork stem must be perpendicular to the long axis of the face, when viewing the patient from the side (Figure 3:5). Make whatever adjustments are necessary to achieve this relationship.

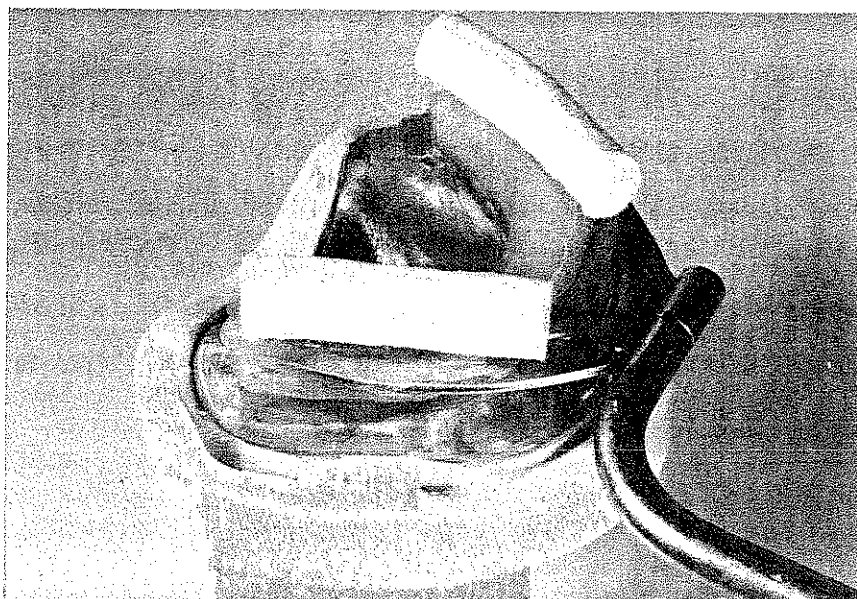


Figure 3:4. Cotton Rolls are Attached to the Bitefork.

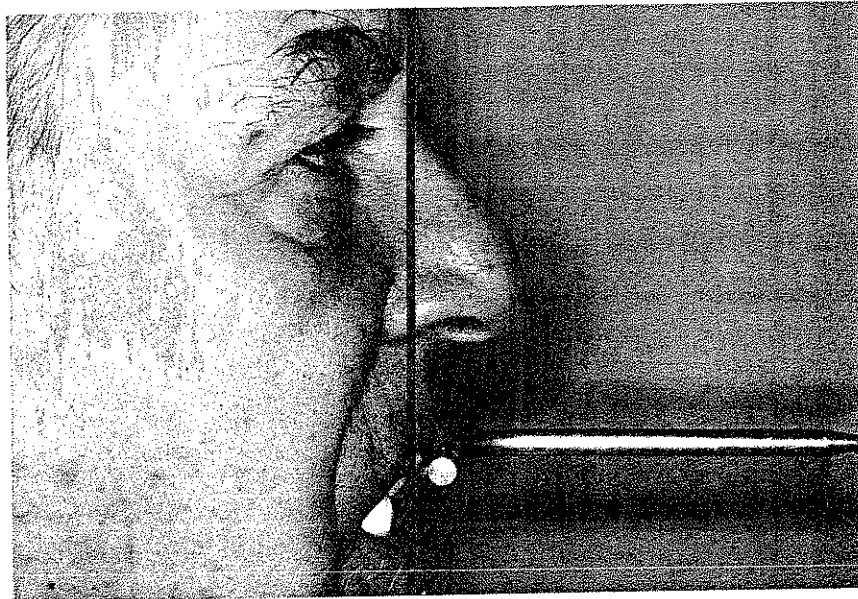
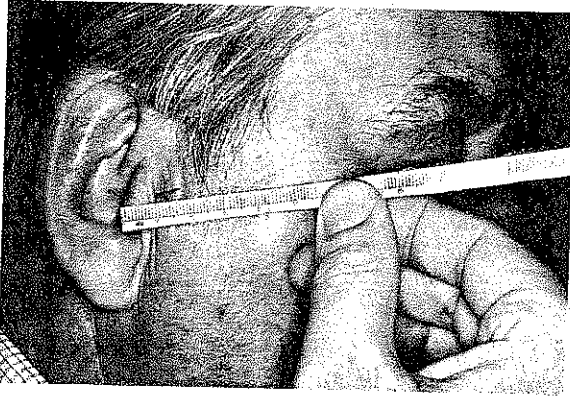
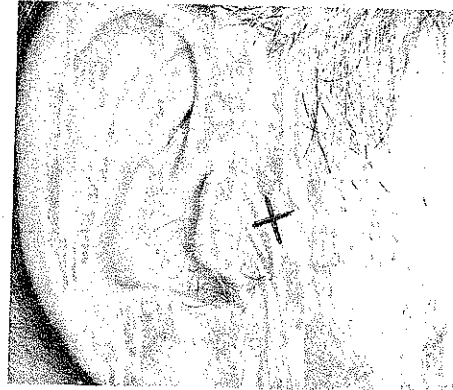


Figure 3:5. The Bitefork is Placed in the Patient's Mouth. Note: Bitefork stem is perpendicular to the long axis of the face.

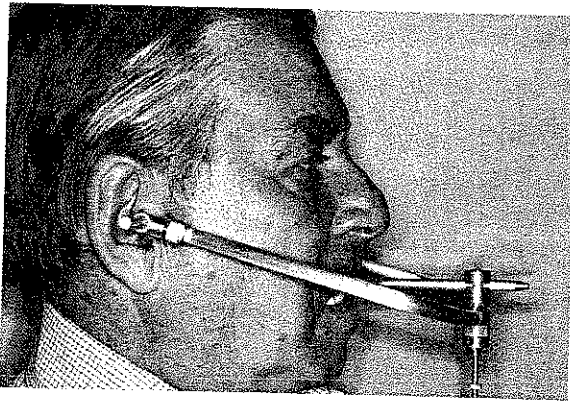
6. Mark the two posterior reference points bilaterally 13 mms. anterior to the tragus of the ear on a line from the middle of the tragus of the ear to the outer canthus of the eye.
7. Join the bitefork to the face-bow and position the condylar rods over the two posterior reference points. (In the clinic, this normally is a two person operation.)
8. Adjust the condylar rods to center the face-bow by setting and resetting the calibrated rods until they are equal, and the rods make minimal contact with the surface of the skin.
9. After the face-bow has been adjusted, tighten the locking mechanisms securely with the face-bow wrench.
10. Now release the condylar rods, remove the face-bow and bitefork, and prepare for mounting the maxillary master cast on the articulator (Figure 3:6).



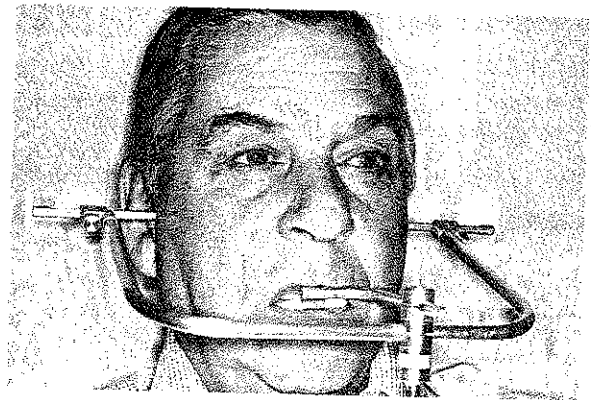
A



B



C



D

Figure 3:6. A) Marking the Posterior Reference Points on the Patient Bilaterally, B) 13 mms. Anterior to the Tragus of the Ear. C) The Face-bow is Centered with Minimal Contact of the Condylar Rods Against the Skin, and D) The Locking Mechanism is Securely Tightened.

STEPS IN PERFORMING THE FACE-BOW TRANSFER USING THE HANAU
AUTOMATIC (EAR ROD) FACE-BOW METHOD

1. The bitefork is attached to the maxillary baseplate in the manner previously described for the Hanau measurement method.
2. Place the baseplate with the attached bitefork and cotton rolls in the patient's mouth and ask him to stand and to bite gently against the cotton rolls to stabilize the bitefork and baseplate. The bitefork stem must be perpendicular to the long axis of the face when viewing the patient from the side. Make whatever adjustments are necessary to achieve this relationship.
3. After the bitefork has been prepared, set it aside for now. Loosen the thumb screws of the ear rod extensions on the face-bow and slide the scales outward to abut the nylon earpieces with the face-bow frame (Figure 3:7).
4. The face-bow is gently positioned over the patient's face and the ear-rod extensions are positioned so that the nylon earpiece enters the meatus of the ear (Figure 3:7).

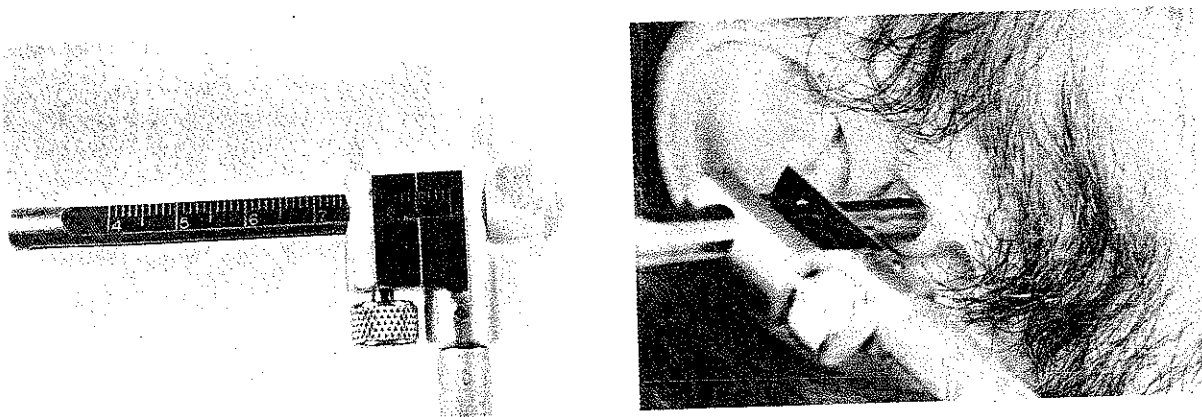


Figure 3:7. The Scales are Slid Outward to Abut the Nylon Earpiece with the Frame Prior to Positioning the Face-bow on the Patient. The Nylon Earpiece is then Extended into Contact with the External Auditory Meatus.

5. Adjust the scales bilaterally until they read the same. The ear rods should be comfortable to the patient and yet provide secure suspension of the face-bow. Make a mental note of the numerical figure on the scale; slide the scale outward and remove the face-bow (Figure 3:8).

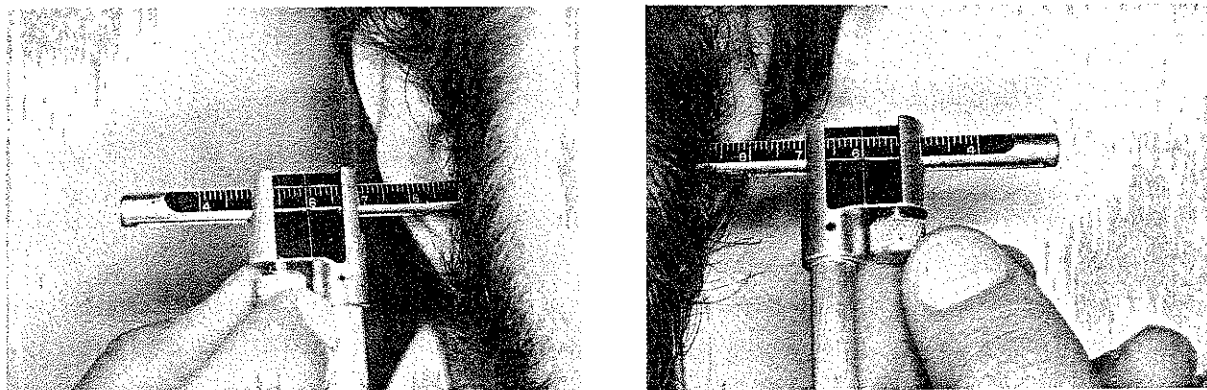


Figure 3:8. Adjust the Scales Bilaterally Until They are Even.

6. Insert the stem of the bitefork into the bitefork clamp of the face-bow and gently tighten the clasp. Once the baseplate is positioned over the maxillary residual ridge loosen the clamp so that the face-bow can be positioned properly. You may want to use the patient's old dentures to bite against the cotton rolls to support the bitefork.
7. With the baseplate and bitefork in position, the ear rods can be inserted into the meatus of the ear and again adjusted to the previously recorded measurement on the extension scales.
8. Tighten the thumb screws to maintain the ear rods in light contact with the external auditory meatus.
9. Tighten the thumb screw clamp to securely tighten the bitefork to the face-bow (Figure 3:9).
10. Release the two thumb screws maintaining the contact of the ear rods with the meatus of the ears and withdraw the scales with the nylon earpieces from the meatus.
11. Remove the entire face-bow assembly and the maxillary baseplate from the patient's mouth. The face-bow can now be taken to the laboratory to mount the maxillary master cast on the articulator (Figure 3:10).

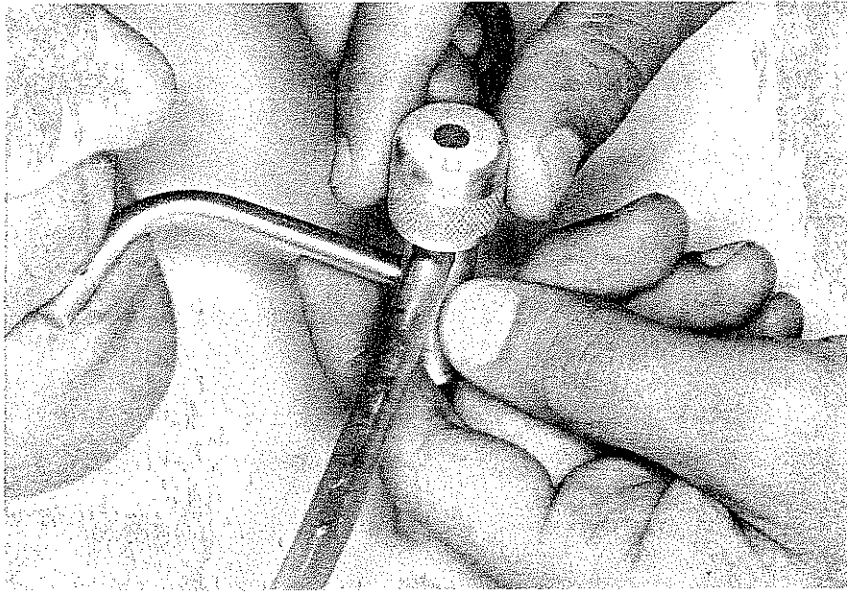


Figure 3:9. Tighten the Thumb Screw Clamp to Securely Unite the Bitefork to the Face-bow.




Figure 3:10. The Face-bow Assembly is Positioned on the Articulator for Mounting the Master Cast.

STEPS IN MOUNTING THE MAXILLARY MASTER CAST FROM THE HANAU
MEASUREMENT FACE-BOW METHOD

1. Center the Hanau face-bow on the articulator by adjusting the condylar rods until they are equal.
2. With the face-bow attached to the articulator, lock the condylar mechanisms and lock the incisal pin flush with the upper member of the instrument.
3. Raise or lower the face-bow until the stem is parallel to the upper member of the articulator by adjusting its supporting jack, not by twisting the locking mechanism (Figure 3:11).




Figure 3:11. The Master Cast is Seated in the Baseplate After the Face-bow is Adjusted to the Articulator.

4. Using the Faskut wheel, cut several mounting keyways into the base of the maxillary master cast. Before mounting the master cast, soak it in water for five minutes. Place the mounting ring on the articulator and be sure it is locked tightly (Figure 3:12).




Figure 3:12. Several Mounting Keyways are Cut into the Base of the Master Cast with the Faskut Wheel.




Figure 3:13. The Maxillary Master Cast is Mounted on the Articulator.

5. Seat the maxillary master cast into the baseplate and using the impression plaster join the model to the mounting ring.
6. After the plaster has set, disassemble the face-bow and remove the mounted cast from the articulator.
7. Cleanse the articulator of residual plaster. Fill in any voids in the plaster and smooth it with wet Carborundum paper (Figure 3:13).
8. Recover the maxillary stabilized baseplate and remove the bitefork and any remaining wax. This baseplate will be used in registering and transferring other maxillomandibular records.

STEPS IN MOUNTING THE MAXILLARY MASTER CAST FROM THE HANAU
AUTOMATIC (EAR ROD) FACE-BOW METHOD

1. Check the articulator to be certain that:
 - a. the incisal pin is flush with the upper member of the articulator.
 - b. the lateral condylar guidance is set at zero.
 - c. the condylar elements are against their respective metal stops.
 - d. the incisal pin is centered on the incisal guide table.
2. Set the condylar horizontal guidance to 70° mechanical equivalents (Figure 3:14).




Figure 3:14. The Horizontal Condylar Guidance is Set at 70° Mechanical Equivalents.

3. Check to be certain that the centric locks are tightened to restrict the instrument to opening and closing movements only.
4. Attach the mounting ring to the upper member of the articulator.
5. Attach the earpiece face-bow assembly to the articulator by equally adjusting the scales to suspend the nylon earpieces securely over the auditory pins of the centric locks (Figure 3:15).




Figure 3:15. Adjust the Scales Until Both Sides are Even and the Nylon Earpieces are Suspended Over the Auditory Pins of the Centric Locks for each Condylar Mechanism.

6. Raise or lower the adjustable screw on the bottom of the bitefork support clamp until the stem of the bitefork approximates the level of the lower notch on the incisal pin (Figure 3:16).
7. Support the maxillary cast and the bitefork from beneath with the telescoping cast support and attach the master cast to the mounting ring of the articulator with a mix of impression plaster.
8. After the plaster hardens, remove the face-bow assembly. Cleanse the articulator of residual plaster, fill in any voids in the plaster and smooth it with wet Carborundum paper.
9. Recover the baseplate for future use in registering and transferring other maxillomandibular records.




Figure 3:16. Raise or Lower the Adjustable Screw on the Bottom of the Bitefork Support Clamp Until the Stem of the Bitefork Approximates the Level of the Lower Notch on the Incisal Pin.

OBJECTIVES

Knowledge. Upon completion of this unit, you will be able to:

1. State the steps in determining the occlusal vertical dimension.
2. State the steps in recording and transferring the centric jaw relation.
3. State the steps in recording and transferring the protrusive registration.

Skill. Although you will not perform these Procedures in the Preclinical course, you should understand how they are done in order to better perform later Procedures in this course and in your clinical experiences.

VIDEOTAPES

1. Maxillomandibular Jaw Relations.

MATERIALS NEEDED FOR PROCEDURE #8

1. Hanau H-2 Articulator with Maxillary Master Cast Mounted.
2. Mandibular Master Cast and Stabilized Baseplate.
3. mm. Ruler and Indelible Pencil.
4. Wax Hot Plate (putty knife).
5. Pink Baseplate Wax.
6. #7 spatula.
7. Bunsen burner.
8. Hanau torch.
9. Red Handle Knife and #25 Blade.
10. Vaseline.
11. Aluwax.
12. Faskut Stone and Chuck.
13. Mounting Stand.
14. Rubber Bowl.
15. Kerr Laboratory Spatula.
16. Impression Plaster.

STEPS IN ESTABLISHING THE OCCLUSAL VERTICAL DIMENSIONThe Mandibular Occlusal Plane

1. Tentatively develop the mandibular occlusal plane by using previously described guidelines for a mandibular wax occlusal rim.
2. Examine the wax occlusal rim intraorally. With the patient's mouth partly opened, the rim should be at or slightly below the corners of the mouth (Figures 3:17 and 3:18). Looking at the patient from the front, the wax occlusal rim must be parallel to an imaginary line through the pupils of the eyes. If this proves to be its position, proceed to the establishing of the occlusal vertical dimension. However, if it is materially above or below the corners of the mouth, review the requirements of your patient with your instructor.

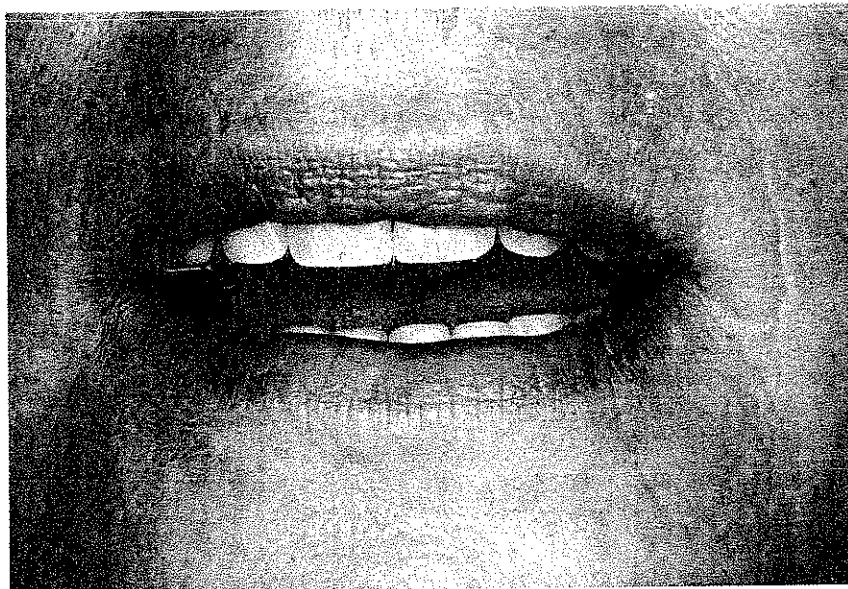


Figure 3:17. The Wax Occlusal Rim Will be Replaced in a Later Procedure by the Supplied Teeth. It is therefore Essential that the Tentative Wax Occlusal Rim be Developed Using the Available Anatomic Guides. One Should Realize the Importance of Lip Support by the Mandibular as well as the Maxillary Teeth and Esthetic Considerations.

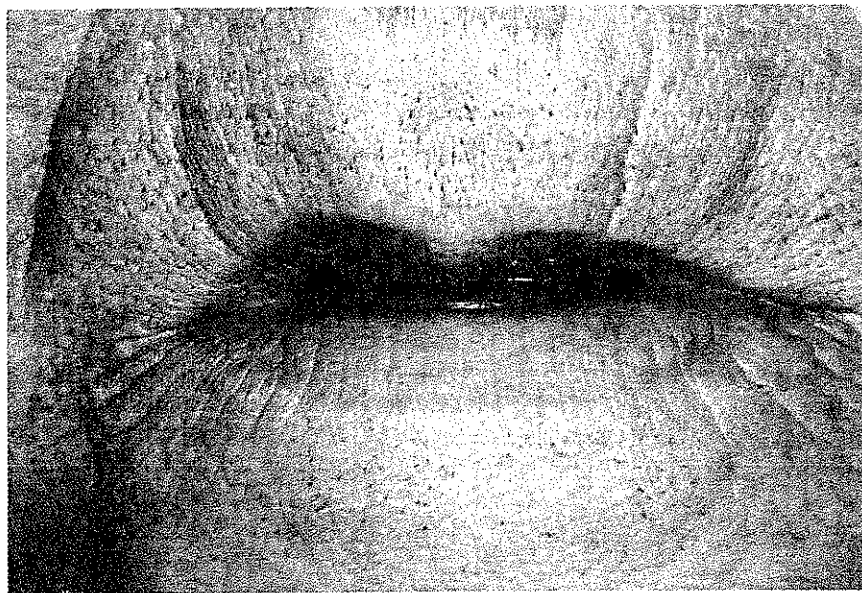
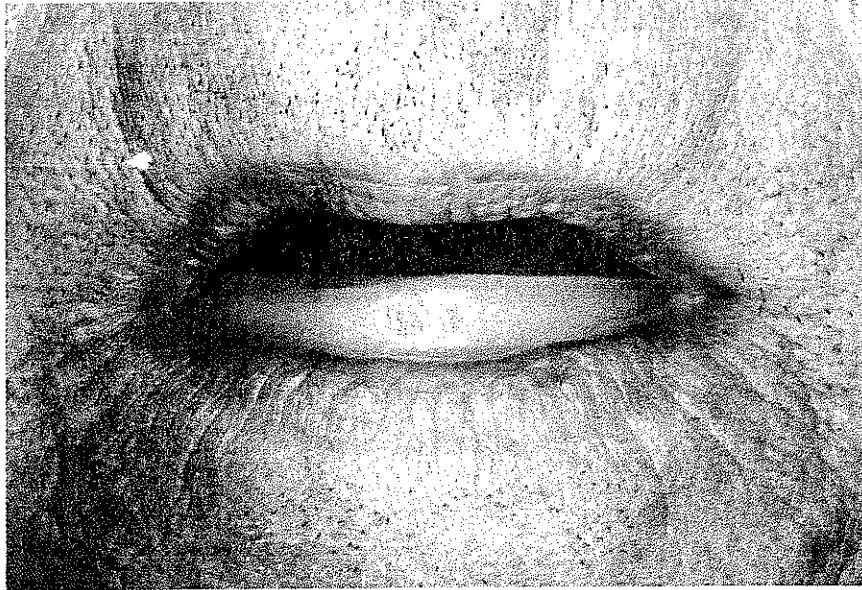

Figure 3:18. The Tentative Occlusal Plane is Examined in the Patient's Mouth and Adjusted as Needed. When the Plane is too High it is Reduced by Melting Away the Wax Using the Heated Wax Plate (putty knife). One Should Attempt to Maintain the Wax Rim as Parallel as Possible to the Mean Residual Ridge.

The Occlusal Vertical Dimension (OVD)

1. Establish the occlusal vertical dimension of the edentulous patient from the physiologic rest position (PRP). Seat the patient in an upright position. To establish the vertical dimension of occlusion is perhaps the most difficult clinical procedure a student will encounter. Use as many of the clinical methods as are available to you in determining the vertical jaw relation. Phonetics, pre-extraction records, and radiographs are helpful. However, these records often are not available. The phonetic test and the patient's profile with particular attention given to the activity of the muscles of facial expression are quite reliable.

Phonetic Tests

- a. Place two small ink dots, one on the patient's maxillary lip at the junction of the philtrum and septum and the other on the most forward point of the chin. Ask your patient to pronounce the letter "m" and, following the complete pronunciation of the letter, to maintain this position of the lower jaw. Measure the distance between these dots in millimeters and record this physiologic rest position. Repeat the procedures several times and calculate an average of the distances. Some patients have the ability to move the skin over their chin without moving the mandible. This may account for variation in measurement.
- b. Any measurement is valid only at the time it is used and only for the operator making the measurement. Recheck the physiologic rest position at subsequent appointments, for its determination is a continuing process ending with the trial dentures.

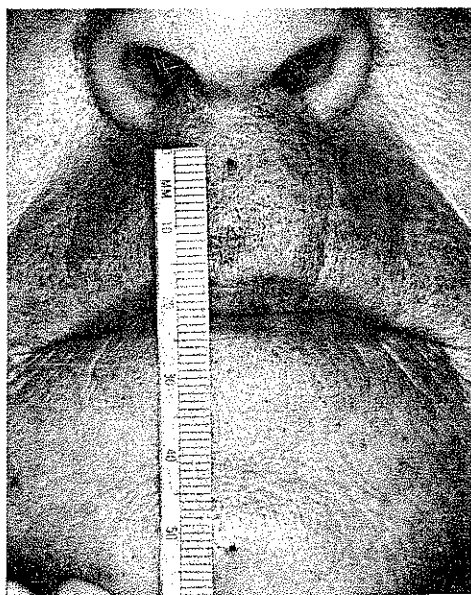
In the rest position of the mandible there is a harmony of facial muscles which serves the experienced operator as a further check of the measurement of the physiologic rest position. If the mandible is overclosed, the lips and mandible appear protruded, causing a reverse curve to the lips. If the mandible is held open from the rest position, a strained appearance is evident when the lips are brought into contact.

The Interocclusal Distance (ID)

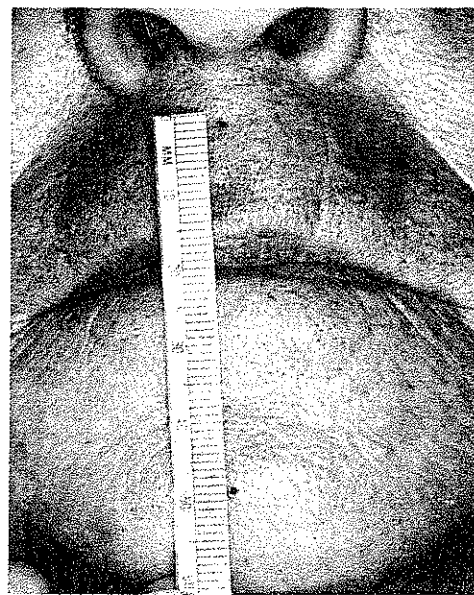
The interocclusal distance (ID) is the space between the teeth when the mandible is at the resting position. This distance is from one to ten millimeters in natural dentition. In the edentulous patient, the amount of interocclusal distance is an arbitrary decision made by the dentist; however, some basic guidelines must be considered.

1. If the patient is wearing dentures, measure the amount of interocclusal distance in the existing dentures and use it as a guide. If the patient has worn these dentures for several years, a more than adequate interocclusal distance usually exists.
2. The dentist must establish the interocclusal distance for a patient without previous dentures. As a general rule, provide a greater amount of interocclusal distance as the age of the patient increases. An interocclusal distance of 2-3 mms. is adequate for a young patient, while an elderly patient should be given 4-5 mms. of space.

The occlusal vertical dimension (OVD) represents the distance the mandible is separated from the maxilla when the teeth are in maximum contact. Determine this by subtracting the interocclusal distance from the physiologic rest position (Figure 3:19).



A



B

Figure 3:19. A) Physiologic Rest Position is Determined Phonetically and Repeated Measurements are Recorded. B) The Occlusal Vertical Dimension is Established by the Dentist and is Less Than the Physiologic Rest Dimension.

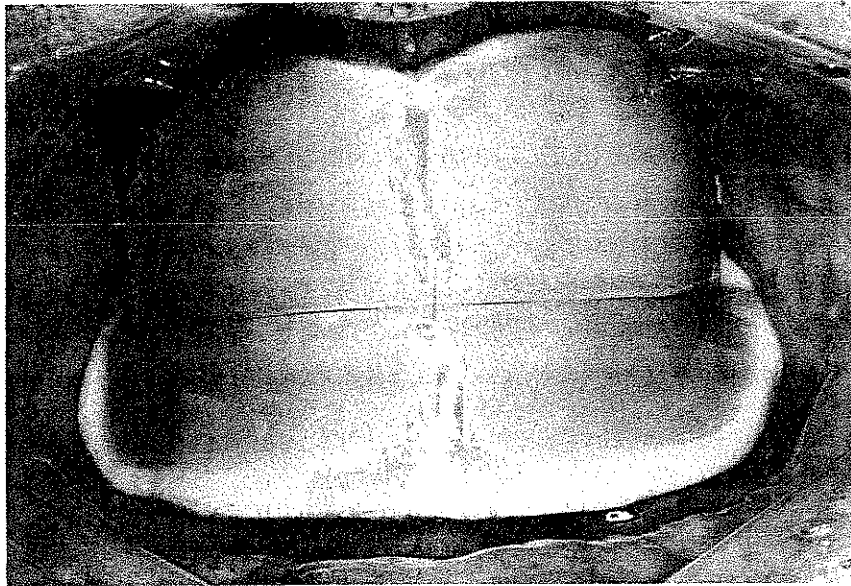


Figure 3:20. The Maxillary Wax Occlusal Rim, Contoured to Support the Lip at the Established Occlusal Vertical Dimension.

The Maxillary Wax Occlusal Rim

1. After the physiologic rest position is measured and the interocclusal distance for the patient determined, place the mandibular baseplate with wax occlusal rim in the patient's mouth (Figure 3:20). Lubricate the occlusal surface of the wax occlusal rim with a small amount of Vaseline. With the maxillary baseplate positioned on the master cast, place yellow sticky wax along the crest of ridge.

2. Warm one sheet of pink baseplate wax, form it into a roll, and attach it to the maxillary baseplate with a hot #7 spatula.
3. Place the maxillary baseplate with the soft wax occlusal rim in the patient's mouth and guide his jaw to closure with the mandibular wax occlusal rim.
4. Measure this OVD and compare it to the OVD previously measured.
5. Add or remove wax from the occlusal surface of the maxillary rim until you establish the desired dimension.
6. Remove and chill the baseplates, and remove any excess wax from the maxillary wax occlusal rim.
7. In order to create proper support for the upper lip, contour the maxillary wax occlusal rim (Figure 3:20).

Tests for the Adequacy of the Occlusal Vertical Distance

1. A patient's lips must not appear strained when the wax occlusal rims are in contact. Instruct the patient to repeat the word "Mississippi" or "66" several times so that you can check for 1 mm. of space between the rims in the anterior. If the wax occlusal rims contact, it is an indication that there is insufficient interocclusal distance (1 mm. space usually indicates that approximately 3 mms. of interocclusal distance has been established).
2. Also instruct the patient to open his mouth as widely as possible, then close it until the lips touch and facial muscles appear relaxed to the operator. Place your index finger lightly on the lower border of the patient's chin and instruct him to close until the occlusal rims contact. If you cannot perceive movement, the interocclusal distance is insufficient, and further modification is necessary.
3. Always check for final determination of the interocclusal distance at the try-in appointment, when phonetic tests may be easier for the patient to accomplish.
4. Guard against the desire of some patients to remove all facial wrinkles by increasing the occlusal vertical dimension. Trying to do this will result in an insufficient interocclusal distance in the new dentures. Granting such wishes of your patient will result in a disgruntled patient who cannot function with the new dentures and will place all the blame on you.
5. Excessive interocclusal distance usually results in complaints of discomfort and inefficiency; insufficient interocclusal distance usually results in complaints related to esthetics.

STEPS IN RECORDING AND TRANSFERRING THE CENTRIC JAW RELATION

1. Using the red handled knife, make two small V-shaped grooves bilaterally across each posterior portion of the mandibular wax occlusal rim. The grooves should be 1-2 mms. deep and should form sharp angles (Figure 3:21).


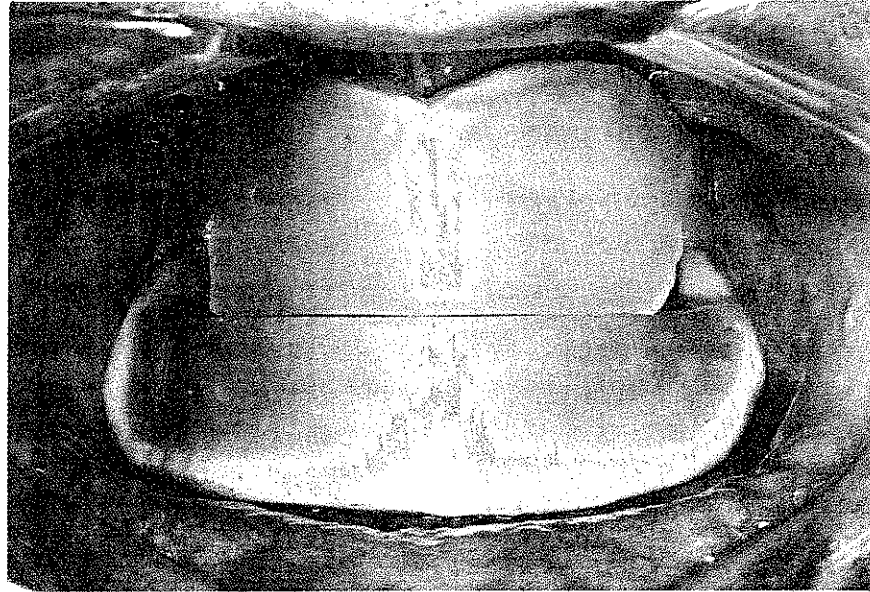


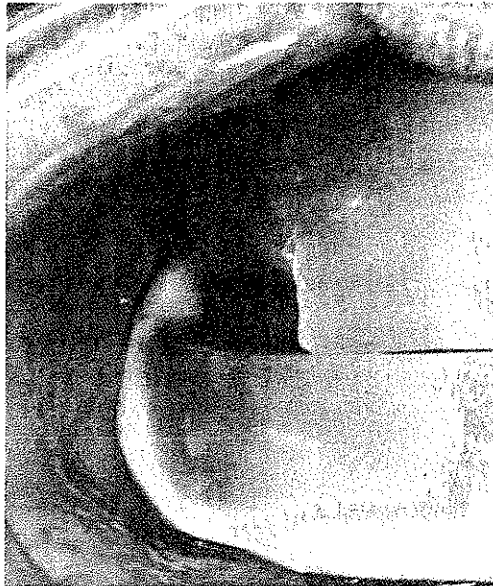
Figure 3:21. Shallow V-Shaped Grooves are Cut into the Mandibular Wax Occlusal Rim.

2. Remove 3 mms. from the occlusal surfaces of the wax occlusal rim of the maxillary arch bilaterally from the region of the cuspid eminence posteriorly (Figure 3:22). This provides adequate space for the inter-occlusal registration material. The anterior maxillary and mandibular wax occlusal rims will remain unaltered to provide the vertical stop to maintain the established occlusal vertical dimension.

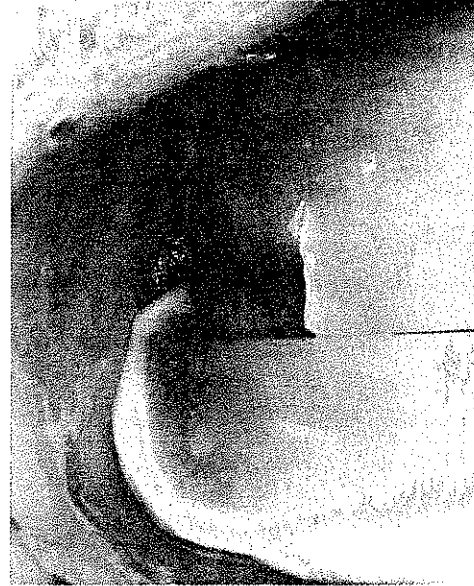Be sure to carefully check to be certain that there are no areas of contact between the maxillary baseplate and the posterior extensions of the mandibular wax rim or baseplate. If such interferences are observed they must be eliminated before registering centric relation (Figure 3:22).



A



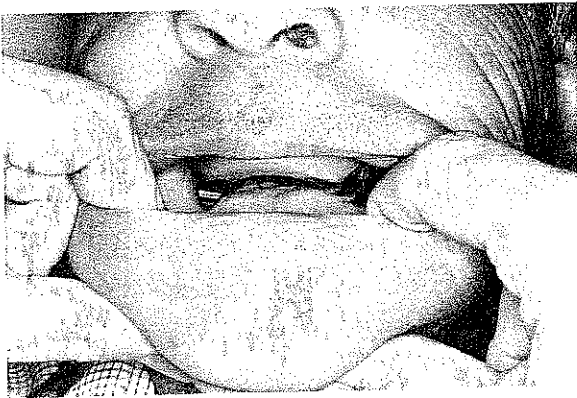
B



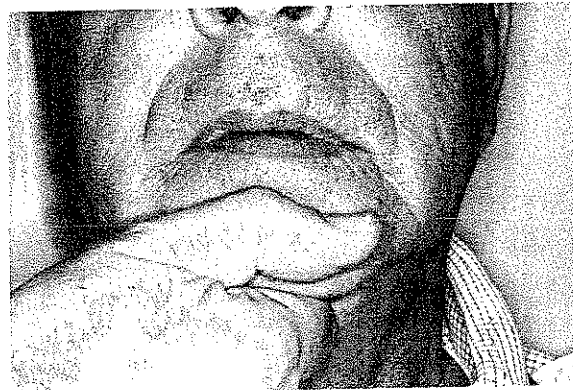
C

Figure 3:22. A) Wax is Removed Bilaterally From the Posterior Areas Leaving the Anterior Wax Unaltered as the Vertical Stop. B) When Posterior Baseplate Interferences Exist They Must be Removed, C) Before Recording Centric Relation.

3. Lubricate the occlusal surface of the mandibular wax occlusal rim with Vaseline.
4. Seal strips of the interocclusal registration material (Aluwax) to the posterior portions of the maxillary wax occlusal rim.
5. Position the patient upright with his head supported in the headrest.
6. Gently heat the Aluwax additions on the maxillary rim with a warmed instrument, or with the flame of an alcohol torch, then place the baseplate in the patient's mouth.
7. Guide the mandible backwards, with your thumbs placed on the inferior borders of the mandible for bracing, and with your index fingers placed bilaterally on the buccal flanges of the mandibular baseplate (Figure 3:23).



A



B

Figure 3:23. A) Proper Positioning of the Thumbs and Index Fingers is Essential to Keep the Mandibular Baseplate Seated. B) Grasping the Patient's Chin with the Thumb and Fingers as Illustrated will Result in a Shift of the Mandibular Baseplate and a Faulty Centric Relation Record.

8. When you feel a hinge-like motion during opening and closing mandibular movements, guide the patient's mandible to closure until initial contact is observed between the anterior portions of the maxillary and mandibular wax occlusal rims.
9. Then instruct the patient to open his jaws. Remove the baseplates and chill them in cold water.
10. Inspect the maxillary posterior wax registration for uniform contact with the mandibular wax occlusal rim, and for registrations of the mandibular posterior grooves.
11. Remove the excess interocclusal registration wax with a sharp scalpel; also eliminate any undercuts in the wax.
12. Reinsert the baseplates again guiding the patient's mandible into centric jaw relation closure. Open and close the mandible several times in centric jaw relation. Remove the baseplates from the mouth and eliminate any wax distortions (Figures 3:24 and 3:25).

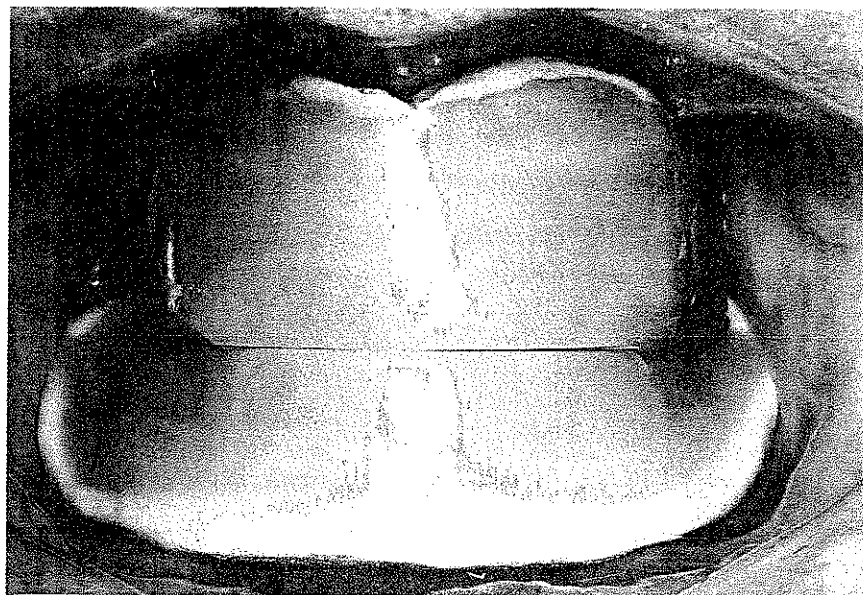


Figure 3:24. The Interocclusal Registration Material Should Register the V-Shaped Grooves When the Anterior Wax Stops are in Contact and the Mandible is Guided to Centric Relation.

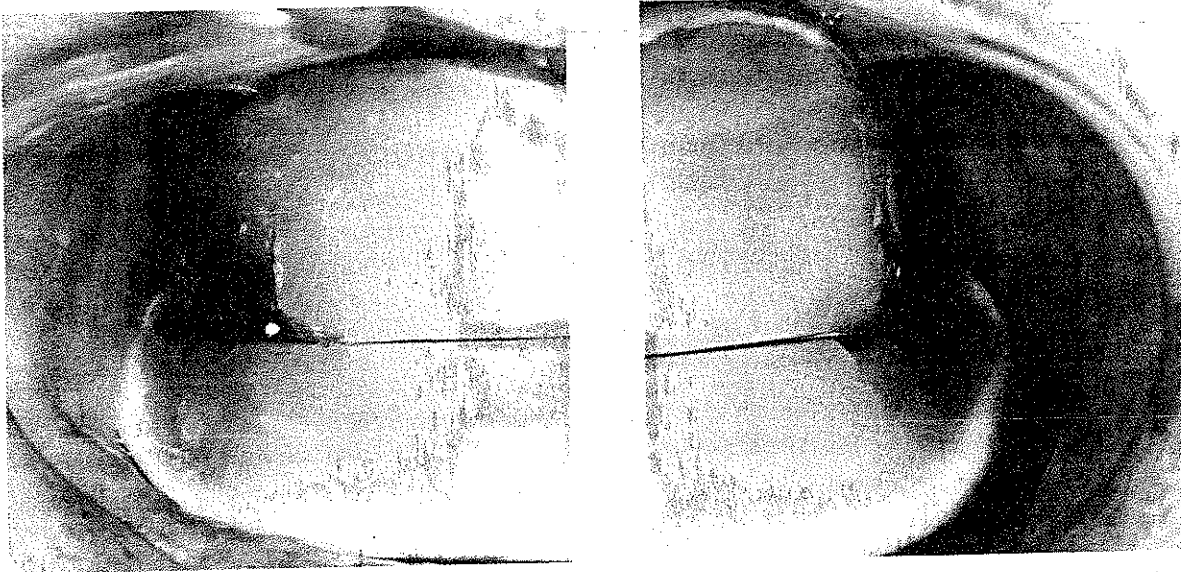
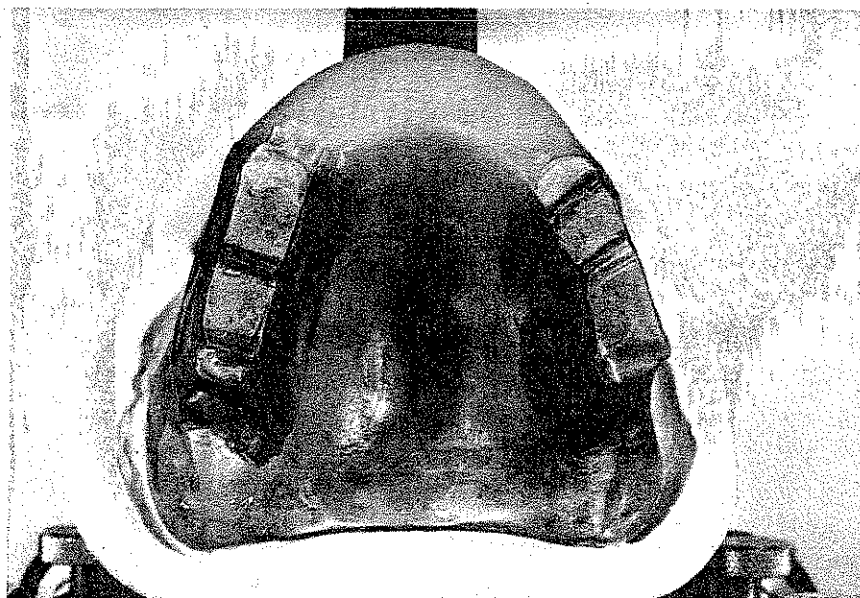
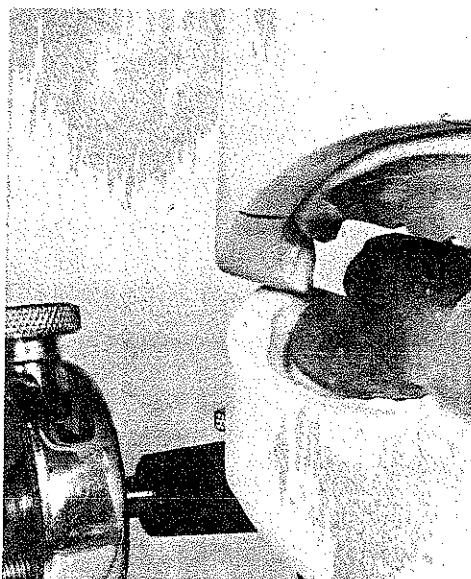

Figure 3:25. Placing the Appropriate Amount of Inter-occlusal Registration Material is Important to Register the V-Shaped Grooves in the Mandibular Wax Occlusal Rim.

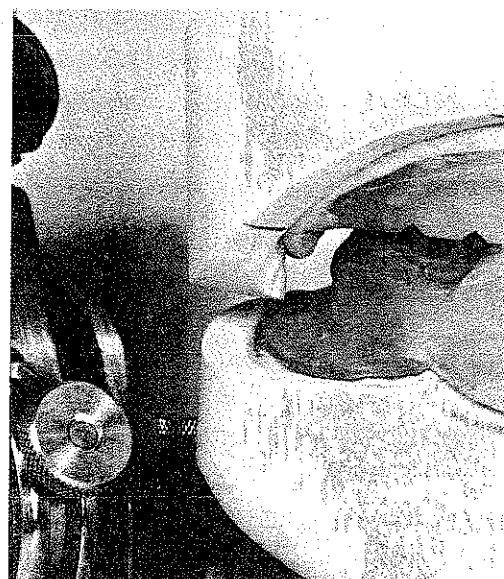
13. Set the condylar mechanisms of the articulator at 30° and lock them with the ball forward against the metal stop.
14. The incisal pin must be flush with the upper member of the articulator. Attach the mounting ring to the lower member of the articulator.
15. Using sticky wax, seal the maxillary baseplate on the master cast that was previously mounted to the upper member of the articulator (See Procedure #7). Also, seal the mandibular baseplate on its master cast, using sticky wax.
16. Before joining the two baseplates by the interdigitation of the bite, carefully check to assure that the stone extensions of the boxing edge (landing areas) posterior to the mandibular retromolar pads do not interfere with the maxillary landing edges. If there are interferences, relieve the stone extensions of the boxing edges (Figure 3:26).



A



B



C

Figure 3:26. A) The Maxillary Baseplate is Seated on its Master Cast and Sealed with Sticky Wax in Selected Areas. The Articulator is then Inverted on the Mounting Stand and Before Joining the Mandibular Baseplate and Master Cast to the Maxillary Baseplate, Carefully Check B) That the Stone Extensions of the Master Casts do not Contact. C) If Contact is Observed, it Must be Removed before Mounting the Mandibular Master Cast.




Figure 3:27. The Mandibular Master Cast is Joined to the Mounting Ring with a Thin Mix of Impression Plaster.

17. Carefully seat the Aluwax bite into the mandibular wax occlusal grooves. Seal the waxes together with a hot #7 spatula.
18. Invert the articulator on a mounting stand, and with a loose mix of impression plaster, join the previously keyed base of the mandibular cast and the articulator mounting ring (Figure 3:27).

19. After the plaster has set, open the articulator by cutting the two wax occlusal rims apart with the blade of the red handled knife. Do not attempt to pull the baseplates apart, as that would result in a separation of the mandibular cast from the mounting ring.
20. Open the articulator and remove and clean the mountings.
21. Clean the wax occlusal rims and prepare for checking the centric jaw relation mounting. Remove the interocclusal registration wax from the maxillary wax occlusal rim and replace it with new interocclusal registration wax.
22. Repeat the clinical procedures for recording the centric jaw relation registration. At this time, mark a vertical line on the labial maxillary wax occlusal rim denoting the center of the face (Figure 3:28).

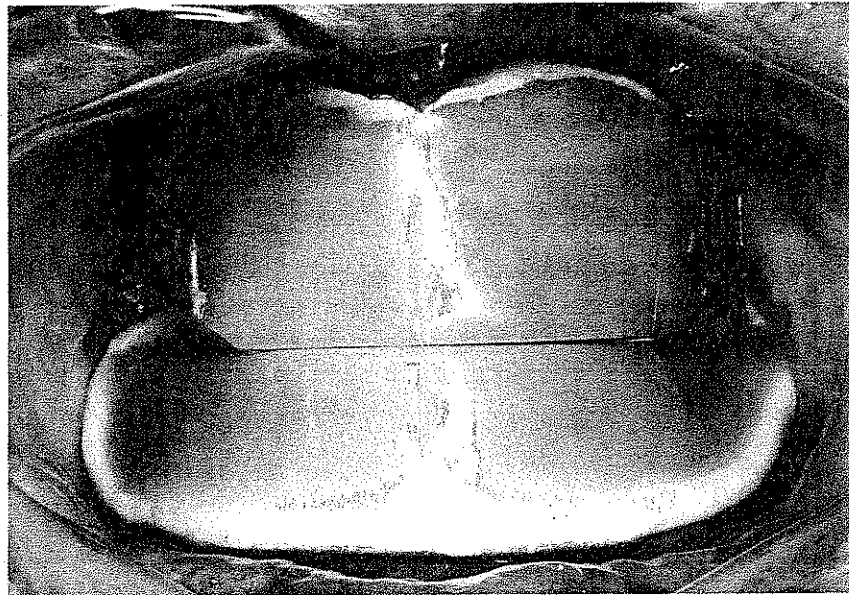


Figure 3:28. A Second Interocclusal Registration of Centric Relation is Made. The Center of the Face is Determined and a Line is Scribed on the Labial Surface of the Maxillary Wax Occlusal Rim.

23. With the articulator open, place both the maxillary and mandibular baseplates in position. Loosen the condylar mechanisms so that the ball moves freely in its channel housing. Carefully position the Aluwax interocclusal registration into the mandibular wax occlusal grooves.
24. With the interocclusal registration interdigitated, if the condylar balls return flush to their stops, the mounting is accurate and two successive centric relation records have been recorded (Figure 3:29).

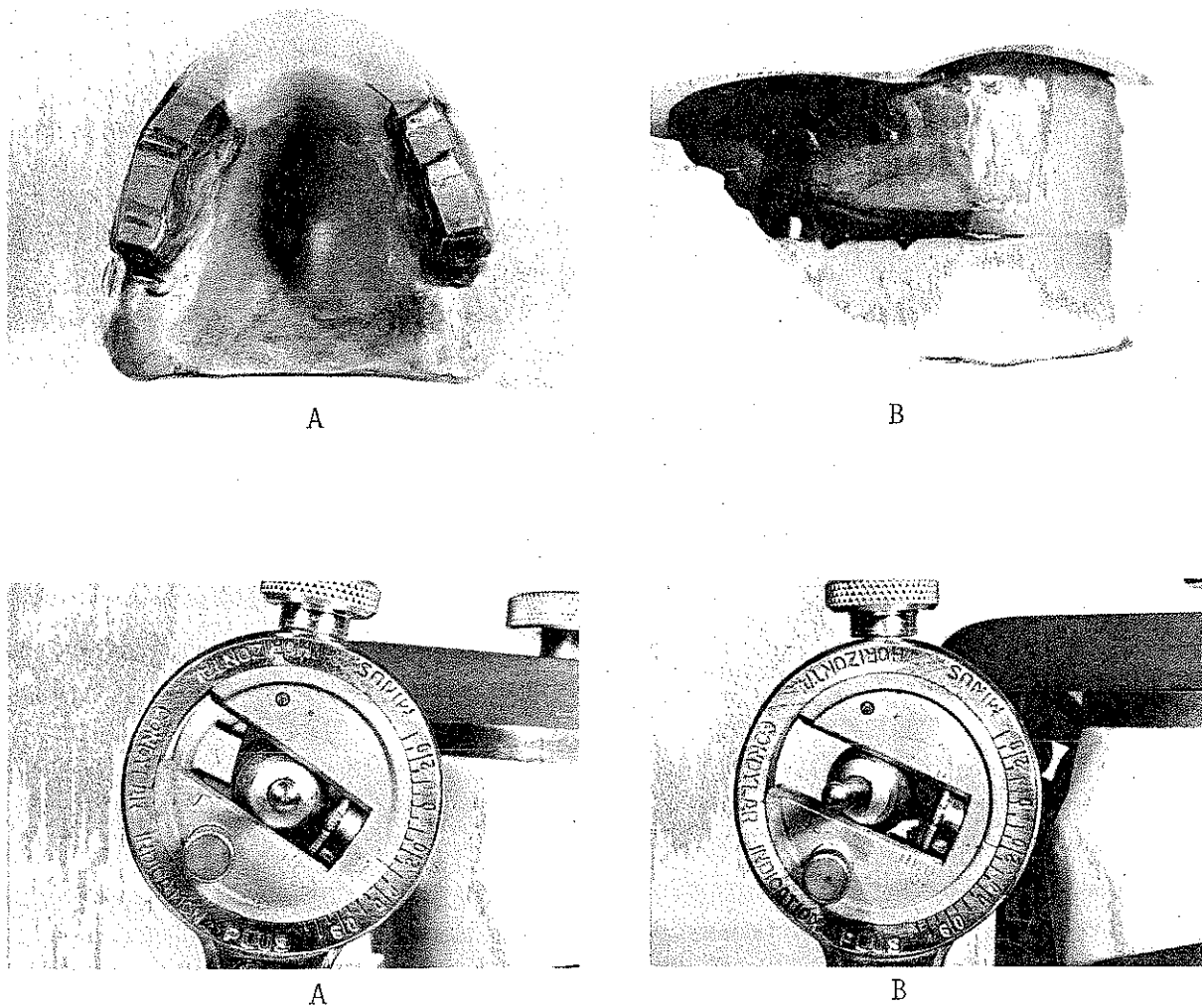


Figure 3:29. A) The Second Centric Relation Record is Seated on the Master Cast and B) Interdigitated with the Mandibular Wax Occlusal Rim. C) The Condylar Ball Must Remain Flush with the Anterior Metal Stop. D) If Space is Observed, a Third Registration is Required and if the Error Remains the Mandibular Cast Should be Remounted.

If the relationship within the condylar mechanism is not such that the balls return flush to their stops, there is an error in the jaw relation registration or in the mounting of the mandibular master cast. When condylar discrepancy is present, repeat the centric jaw relation bite registration on the patient. If the third registration produces a condylar discrepancy, remount the mandibular master cast. Following the remounting of the mandibular cast repeat the centric jaw relation registration until accurate registration and mounting are assured (Figure 3:29).

25. Now clean the mountings, the articulator, the baseplates, and the wax occlusal rims, and prepare them for the protrusive interocclusal registration.

STEPS IN RECORDING AND TRANSFERRING THE PROTRUSIVE INTEROCCLUSAL REGISTRATION

1. Following verification of the centric jaw relation registration and mounting, make the protrusive record.
2. Always make the protrusive registration at a jaw opening that is greater than the occlusal vertical dimension.
3. Attach additional bite wax to the maxillary wax occlusal rim covering the posterior sections.
4. Properly heat the bite wax so that it is soft and insert both the maxillary and mandibular baseplates into the patient's mouth.
5. Using your index fingers and thumbs of both hands, stabilize the mandibular baseplate and retrude the mandible. Now, ask the patient to protrude his jaw 5 to 6 mms. and then guide the mandible closed to a position greater than the established vertical dimension of occlusion (Figure 3:30).
6. Remove and chill the baseplates, and trim off any excess wax with a sharp blade (Figure 3:31).
7. Position the baseplates on their respective master casts in preparation for setting the articulator. Loosen the condylar mechanisms, protrude the instrument, and interdigitate the protrusive interocclusal registration (Figure 3:32).
8. Adjust the horizontal condylar adjustments of the articulator until interdigitation takes place on the wax occlusal rims.
9. Lock the condylar mechanisms and record the protrusive mechanical equivalents in degrees (Figure 3:33).

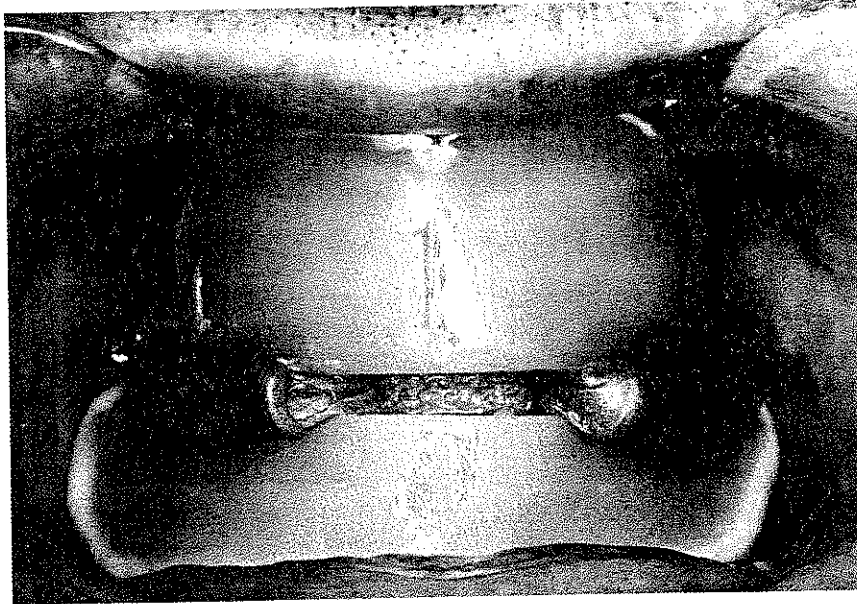


Figure 3:30. The Protrusive Registration is Made 5-6 mms. Forward from Centric Relation at an Open Vertical Dimension of Occlusion.

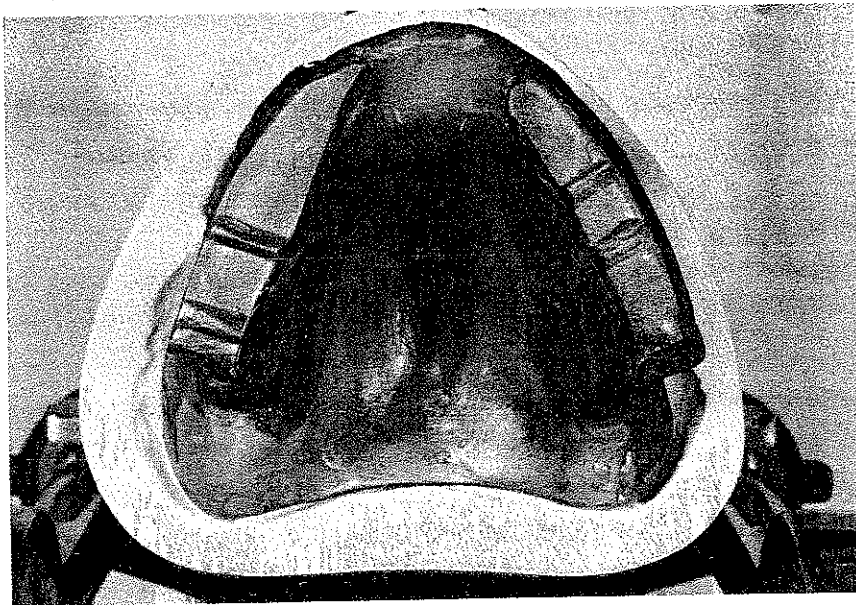


Figure 3:31. The Protrusive Registration is Trimmed of Excess Wax and Seated on the Master Cast.




Figure 3:32. The Horizontal Condylar Adjustment is Rotated Until the Protrusive Interocclusal Registration Interdigitates.






Figure 3:33. The Condylar Mechanisms are Adjusted and the Protrusive Mechanical Equivalents in Degrees Recorded.

10. Adjust the lateral condylar guidance or Bennett's Angle to the average setting of 15 degrees mechanical equivalent (Figure 3:34).
11. Remove the bite registration wax from the maxillary baseplate and replace it with pink wax. Fill the grooves in the mandibular posterior wax occlusal rims with pink wax in preparation for setting of the artificial teeth.
12. Remove the mandibular mounting from the articulator. Make a second mix of impression plaster, and fill in any voids between the mounting ring and the base of the master cast. Both the maxillary and mandibular mountings must be neat and clean in preparation for the setting of the teeth (Figure 3:34).



A



B

Figure 3:34. A) The Lateral Condylar Guidance is Set at 15 Degrees and B) the Mountings are Made Neat and Clean in Preparation for the Setting of the Teeth.

CRITERIA - MAXILLOMANDIBULAR JAW RELATIONS

<u>Face-bow Transfer</u>	<u>Meets Criteria</u>	<u>Does not meet Criteria</u>	<u>Comments</u>
1. The maxillary master cast is well united to the mounting ring with smooth impression plaster.	<input type="checkbox"/>	<input type="checkbox"/>	
2. The master cast is mounted in space within the confines of the articulator in the same relationship as the maxilla is to the arbitrary axis of the mandible.	<input type="checkbox"/>	<input type="checkbox"/>	

[The face-bow should be evaluated after mounting the master cast. The face-bow should be returned to the patient for verification.]

Occlusal Vertical Dimension

- | | | | |
|--|--------------------------|--------------------------|--|
| 1. The patient demonstrates an acceptable interocclusal distance upon closing from physiologic rest position to vertical dimension of occlusion. | <input type="checkbox"/> | <input type="checkbox"/> | |
|--|--------------------------|--------------------------|--|

[Evaluation of physiologic rest position and vertical dimension is made with the patient in an upright position. After instructing the patient to open the mouth widely and then close to light lip contact, the facial tissues should appear relaxed as an observation that the patient's mandible is at physiologic rest position. The patient is then instructed to close until the occlusal rims contact. Speech is another test for the interocclusal distance.]

<u>Centric Relation</u>	<u>Meets Criteria</u>	<u>Does not meet Criteria</u>	<u>Comments</u>
1. In centric relation, the keying indices and the interocclusal registration material interdigitate accurately.	<input type="checkbox"/>	<input type="checkbox"/>	
<p>[Evaluation is made with the operator stabilizing the mandibular baseplate against the residual ridge, with the index fingers against the buccal flanges and the thumbs supporting against the inferior border of the mandible in the first molar areas. The mandible is guided to the retruded position until it hinges. The contact relationship can be evaluated visually.]</p>			
2. On the articulator the indices of the second interocclusal registration interdigitate accurately.	<input type="checkbox"/>	<input type="checkbox"/>	
<p>[The condylar mechanism should be free with the ball remaining flush against the condylar stop.]</p>			
<p><u>Protrusive</u></p>			
1. The horizontal condylar guidances are adjusted from eccentric records.	<input type="checkbox"/>	<input type="checkbox"/>	

SELF TEST 3

FACE-BOW TRANSFER AND MAXILLOMANDIBULAR JAW RELATIONS

(Circle correct response(s) or write brief answers. For correct answers, consult the Answer Key.)

1. The two types of face-bow are:
 - a. _____.
 - b. _____.
2. The error which has been committed in Figure T3:1 is:
 - a. The bitefork stem of the face-bow is not parallel to the eyes.
 - b. The bitefork stem of the face-bow is too far to the lingual.
 - c. The bitefork of the face-bow is not perpendicular to the long axis of the face.
 - d. The bitefork stem of the face-bow is not parallel to the occlusal plane of the patient.

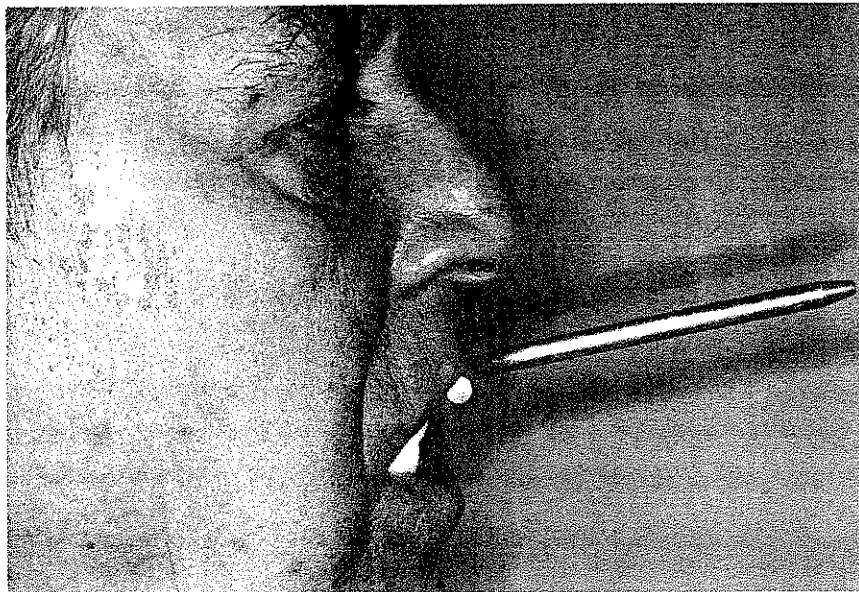

Figure T3:1

- T F 3. A face-bow must be taken in order to establish the patient's centric occlusion.
- T F 4. The Vertical Dimension of the jaws at Physiologic Rest Position should be greater than the Occlusal Vertical Dimension.
- T F 5. $OVD = PRP - ID$.
6. After interdigitating the second centric relation wax registration on the articulator, the condylar mechanism was observed in the relationship illustrated in Figure T3:2. There has been an error in:
- Setting Bennett's angle.
 - Registering the maxillomandibular jaw relation.
 - Mounting the mandibular master cast.
 - Determining the Occlusal Vertical Dimension.




Figure T3:2

- T F 7. When making the protrusive registration, the amount of closure you permit the patient must be more than the established vertical dimension.
8. In Figure T3:3 an error was introduced in articulation. What was that error? _____




Figure T3:3

9. In Figure T3:4 the error in question 8 has been arbitrarily corrected. The attempted correction will result in which of the following?
- a. An insufficient free-way space.
 - b. An excessive vertical dimension of occlusion.
 - c. An alteration in the horizontal condylar guidance.
 - d. An alteration in centric relation.
 - e. Centric occlusion no longer coincidental with centric relation.




Figure T3:4

10. Figure T3:5 illustrates a centric relation inter-occlusal record used to verify the original centric relation record and the mounting of the mandibular master cast. The notches in the wax rim are _____ . This error has the potential to cause which of the following:

- a. Inability to confirm the centric relation recording.
- b. Displacement of condyles bilaterally during closure.
- c. Shifting of the baseplates upon closure.
- d. Displacement of the condyle unilaterally during closure.

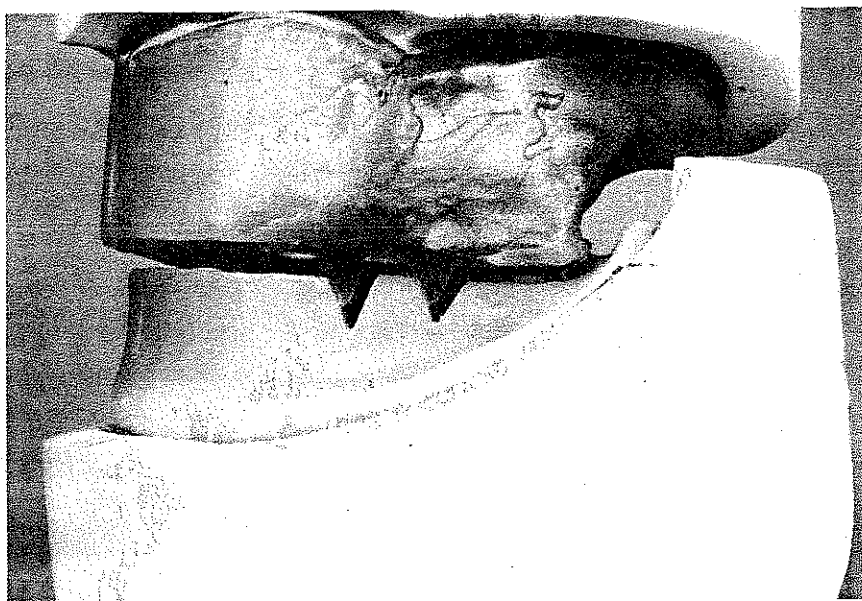


Figure T3:5

11. In Figure T3:6 a potential error exists in mounting the mandibular casts. What is that error?




Figure T3:6

COMPUTER-GENERATED SECTION TEST 3

You are now ready to take Computer-Generated Section Test 3, which will cover:

1. The Face-bow Transfer.
2. Maxillomandibular Jaw Relations.

When you have completed the laboratory procedures which this Section Test covers and are ready to take this test, go to the Caident Center. All Section Tests are on the computer. The proctor in the Caident Center will instruct you on how to take the test. As you take the test, the computer will inform you of your incorrect answers and tell you the correct answer. As soon as you have completed the test, the computer will display your score. Call the proctor to record your score on the Clinic Progress Card.

There are 8 items in this test. The criterion level (the required correct score) is 75%.

ARTICULATION AND ARRANGING THE TEETH

OBJECTIVES

Knowledge. Upon completion of this Section you will be able to:

1. Describe the criteria for properly arranged anterior and posterior denture teeth.
2. Define the types of posterior teeth available to the operator.
3. Explain the relationship between the various factors that influence articulation.
4. Define and describe a balanced occlusion.
5. Name the two materials from which denture teeth are made.
6. Name the four goals of complete denture construction.
7. State the purpose of the "try-in appointment".
8. Define anatomic, nonanatomic, and zero degree teeth, and state the purpose or main advantage of each.
9. Define balanced occlusion, Monson's spherical theory of occlusion, and the anti-Monson curve, and the pleasure curve.
10. Describe the method for establishing the incisal guidance on the articulator.

Skill. The student will develop the skills necessary to complete Procedures #9, 10, and 11.

ANTERIOR DENTURE TEETH

Denture teeth are made of porcelain and acrylic resin. The selection of teeth (regarding material, color, and shape) is the responsibility of the dentist; selection should never be delegated to a laboratory technician.

Although the goals of complete denture occlusion are generally agreed upon, there is little agreement within the Profession about the occlusal concept to be used. Dentists strive to construct complete dentures that, 1) function well, 2) allow their patients to speak normally, 3) are esthetically pleasing, and 4) will not abuse the residual ridges. The methods for accomplishing these occlusal goals, however, range from use of a flat occlusal plane with zero degree teeth to a curve configuration which allows anatomic teeth to glide and pass over each

other in close harmony with mandibular movements. Some authorities advocate "balancing" denture occlusion while others feel that there is no need to balance the occlusion for complete dentures.

The occlusal scheme (denture "setup") taught in Procedures 9 through 11 is not necessarily the same as that used in the clinical treatment of patients during the next two years. The purpose of performing these procedures is to familiarize you with the fundamentals of arrangements and articulation of denture teeth.

Anterior denture teeth are available in many shapes (molds), colors, and shades. The choice of satisfactory anterior teeth is a subject which will be discussed at length during a subsequent course.

Although setting denture teeth in wax is a laboratory procedure, the use of accurate baseplates allows the dentist to place the teeth in the patient's mouth for a final determination of acceptable esthetics and of correct maxillomandibular jaw relationships. This step is performed during what is termed the "try-in appointment."

POSTERIOR DENTURE TEETH

There is very little agreement about ideal complete denture occlusion within the dental profession. Only after the later part of the 19th century were dentists interested in placing posterior denture teeth in relation to a patient's jaw movements. Manufactured teeth at this time approximated the form of natural teeth. It was not until 1858 that an articulator (Bonwill) contained an adjustment other than a simple hinge action. Bonwill's articulator had horizontal condylar guides. Until the middle 1920's, most denture teeth were "anatomic teeth":

Anatomic Teeth. Anatomic teeth are defined as artificial teeth which more or less duplicate the anatomic forms of natural teeth.¹

At this time, dentists began to experiment with tooth forms designed for a specific functional purpose rather than merely reproducing natural forms. Thus the emergence of "nonanatomic denture teeth":

Nonanatomic Teeth. The nonanatomic teeth are defined as artificial teeth so designed that the occlusal surfaces are not copies from natural form, but rather, are given forms which in the opinion of the designer seem more nearly to fulfill the requirements of mastication, tissue tolerance, etc.¹

Some denture teeth were designed completely without cusps. Because of their flat occlusal surface, they were termed zero degree teeth.

Zero Degree Teeth. Zero degree teeth are prosthetic teeth having no cusp angles in relation to the horizontal.¹

THEORIES OF OCCLUSION

Several early theories of occlusion dealt with edentulous patients and the construction of complete dentures. Monson², using Bonwill's³ earlier writings, determined that when a sphere of 8-inch diameter was placed on the occlusal surfaces of the mandibular teeth, the surface would touch the cusp tips of the teeth and also continue through the condyles. An articulator with two centers of rotation (the condyles and the center of the 8-inch sphere) was actually developed and used, based on this theory (Monson's Spherical Theory of Occlusion).

Another theory, developed from observations of the worn teeth in human skulls, advocated a reverse pitch occlusal form for masticating efficiency and greater mandibular denture stability.⁴ This is commonly referred to as the "anti-Monson" curve, or "Pleasure Curve", although there are significant differences between these two theories.

Even today, competent prosthodontists are still widely divided about the fundamentals that should be followed in developing the occlusion for complete dentures.

Balanced Occlusion. Balanced occlusion is an occlusion of the teeth which presents a harmonious relation of the occluding surfaces in centric and eccentric positions within the functional range.¹

Dr. Clyde Schuyler⁵ advocated the use of anatomic teeth arranged with the careful use of the end controlling factors (condylar and incisal guidance) and post-processing adjustments to attain balanced occlusion.

Dr. Leroy Kurth⁶ advocated a monoplane occlusion with little regard to balance.

CHEWING EFFICIENCY

Studies of chewing efficiency have produced conflicting findings. One of the later, well-designed, studies showed no statistically significant difference in the efficiency of the various degree teeth.⁷

PATIENT PREFERENCE

Controversy about the selection of posterior teeth continues. A recent study was undertaken to determine the preference of patients for zero degree or anatomic teeth using duplicate dentures.⁸ The two types of dentures were interchanged several times without the patient's knowledge, and the patient's preferences were recorded. Only two out of 23 subjects were able to tell the difference.

BALANCING THE POSTERIOR TEETH

For this course, we will use the Hanau H-2 articulator and simulate lateral and protrusive movements. The articulator will be set to a 30° horizontal condylar guidance, and a Bennett Angle of 15°.

The teeth are set so that they will glide evenly over each other from the central incisor on through the second molar, on the working side of the arch. No single tooth must interfere and cause the others to lift out of articulation.

Contacts on the balancing side should exist, but must not interfere with the smooth gliding movement on the working side.

Posterior contacts must exist simultaneously with contacts on the anterior teeth for protrusive movements.

Occlusal refinements, after the dentures are processed, using a "selective grinding" technique will be accomplished as a separate Procedure.

When the denture occlusion is balanced on the articulator, it is correctly termed "mechanically balanced occlusion"¹ as opposed to "physiologically balanced occlusion"¹, which can exist only when the occlusion is balanced during movements of the jaws within the functional range.

REFERENCES AND SUGGESTED READINGS

1. Glossary of Prosthodontic Terms, 3rd Edition, J. Pros. Dent., 20:444-480, 1968.
2. Monson, G.W. Applied Mechanics for the Theory of Mandibular Movements. D. Cosmos, 1932. 74:1039-1053.
3. Bonwill, W. Scientific Articulation of the Human Teeth as Founded on Geometric, Mathematical, and Mechanical Laws. D. Items of Interest, 1899. 21:617-636, 873-880.
4. Boswell, J.V. Practical Occlusion in Relation to Complete Dentures. J. Pros. Dent., 1951. 1:307-321.
5. Schuyler, C.H. Full Denture Service as Influenced by Tooth Forms and Materials. J. Pros. Dent., 1951. 1:33-37.
6. Kurth, L.E. The Monoplane Concept of Occlusion. D. Clinics of N. America. Philadelphia: W. B. Saunders Co., March, 1962.
7. Masr, M.F., George, W.A., Travaglini, E.A., and Scott, R.H. The Relative Efficiency of Different Types of Posterior Teeth. J. Pros. Dent., 1967. 13:3-11.
8. Brewer, A.A., Reibel, P.R., and Nassif, N.J. Comparison of Zero Degree Teeth and Anatomic Teeth on Complete Dentures. J. Pros. Dent., 1967. 17:28-35.
9. Lytle, R.B., Atwood, D.A., Beck, H.O. Minimum Standards of Adequate Prosthodontic Service. J. Pros. Dent., 1968, pp. 108-110.

10. Payne, H.S. The Try-In. Dental Clinics of North America. St. Louis: C.V. Mosby Co., July, 1960. pp. 333-343.
11. Sharry, J.J. Complete Denture Prosthodontics, Second Ed., New York: McGraw-Hill Book Company, Inc., 1968. pp. 235-238.

OBJECTIVES

Knowledge. Upon completion of this Procedure, you will be able to:

1. State the steps in mounting the maxillary and mandibular master casts.
2. State, for the maxillary and mandibular anterior teeth:
 - a. In sequential order, the steps in setting the teeth.
 - b. The tooth upon which arrangement of all other teeth in the arch depends.
 - c. The criteria for properly arranged teeth.
3. Describe the method for locating the incisive papilla when the baseplate is on the master cast.
4. Describe the method for setting the incisal guidance.

Skill. Upon completion of this Procedure, you will be able to:

1. Modify the supplied baseplates for addition of wax occlusal rims.
2. Add wax occlusal rims to the supplied maxillary and mandibular baseplates.
3. Set the six maxillary anterior teeth.
4. Set the six mandibular anterior teeth.
5. Set the incisal guidance on the articulator.

VIDEOTAPES

1. Mandibular Wax Occlusal Rim.
2. Setting Maxillary Anterior Teeth.
3. Setting Mandibular Anterior Teeth.

MATERIALS NEEDED FOR PROCEDURE #9

1. Bunsen burner.
2. #7 spatula.
3. Pink baseplate wax.
4. 1 x 6 - 22E porcelain, shade 112 maxillary anterior teeth.
5. 1 x 6 - H, porcelain, shade 112, mandibular anterior teeth.
6. Maxillary and mandibular vinyl baseplates (supplied).
7. Maxillary master casts mounted on Hanau H-2 articulator.

8. Red-handled knife and #25 blade.
9. Kerr handpiece and vulcanite bur.
10. Mandibular master cast.

STEPS IN MOUNTING THE MASTER CASTS

1. So that all articulator setups will be similar, you will be issued a new maxillary master cast that has already been attached to a mounting ring using the face-bow and a new mandibular master cast. Special vinyl baseplates for use in the procedures that follow will also be issued. A mounting guide will be provided that will orient the mandibular master cast on the articulator in such a manner as to allow the proper setting of the technic teeth (Figure 4:1).






Figure 4:1. Mounted Maxillary Master Cast and the Mounting Guide.

2. Place the already mounted maxillary master cast and ring on the articulator. Lock the instrument condylar mechanism forward.
3. Place and fully seat the mounting guide on the maxillary master cast.
4. Use the Faskut stone on the lathe to cut the keyways in the base of the mandibular master cast. These keyways are essential for a later Procedure. Position the mandibular master cast in the mounting guide (Figure 4:2).



A



B

Figure 4:2. A) Grooves are Cut in the Base of the Mandibular Master Cast and B) the Cast is Positioned in the Mounting Guide.

5. Fasten the mandibular master cast to the mounting ring with impression plaster and allow the plaster to set. Be sure to place an adequate amount of plaster into the retentive areas of the mounting ring. Failure to do so usually results in separation of the master cast from the mounting ring (Figure 4:3).





Figure 4:3. Mounting the Mandibular Master Cast. Be Sure to Place Impression Plaster in Mounting Ring Retentive Areas.

6. After the plaster has set, remove the mounting ring and mandibular master cast from the articulator and add a second mix of impression plaster to the mounting to reinforce and dress-up the master cast. Wet-dry Carborundum paper may be used to smooth the plaster (Figure 4:4).







Figure 4:4. The Mandibular Master Cast is Mounted Using the Mounting Stand and the Mounting is Made Smooth Using the Wet-Dry Carborundum Paper.

STEPS IN MODIFYING THE MAXILLARY AND MANDIBULAR BASEPLATES FOR
ADDITION OF WAX OCCLUSAL RIMS

1. Prior to fabricating the maxillary and mandibular wax occlusal rims, the supplied baseplates require some modification (Figure 4:5). Using the lathe-mounted arbor band and the vulcanite bur reduce the length of the flanges for both the maxillary and mandibular baseplates until they satisfy the criteria for baseplates and flange length.

The crest of the ridge area and the labial flanges for both the mandibular and maxillary baseplates must be thinned.

Grinding away the baseplate and even removal of the stabilizing material is sometimes necessary with your clinic patients to properly position the artificial teeth. After adjustment, these baseplates should satisfy the criteria for acceptable baseplates (Figure 4:6).

2. The wax occlusal rims are contoured at a patient appointment in order to: 1) establish the proper occlusal plane (OP), and 2) determine the support for the upper lip. The wax occlusal rim then can act as a guide when setting the anterior teeth. For this Procedure, we will build the wax occlusal rims to the interarch distance already established on the articulator.

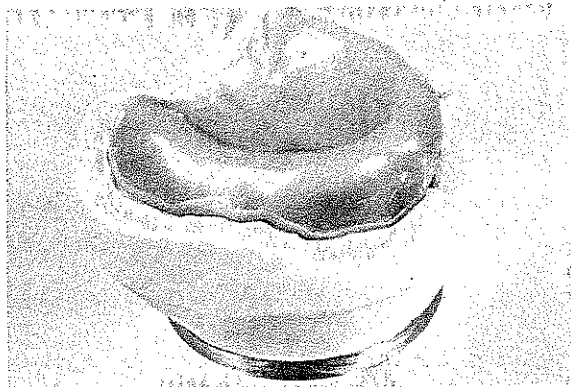
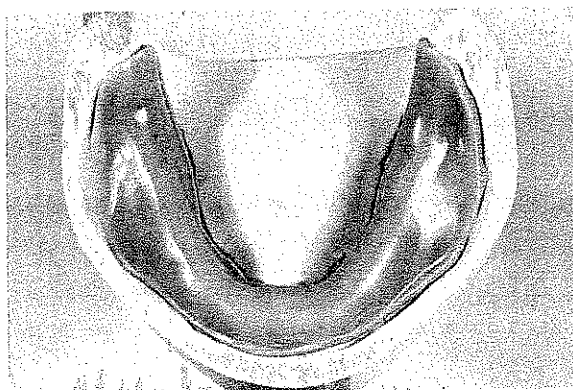

Figure 4:5. The Supplied Vinyl Baseplates will Need Some Modification before the Wax Occlusal Rims are Formed.

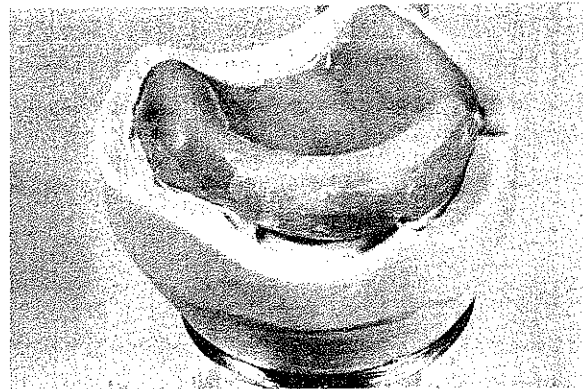
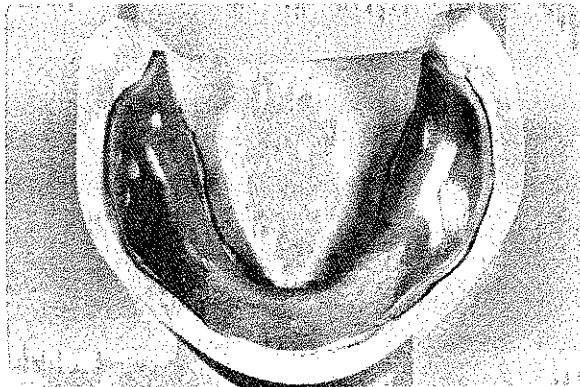
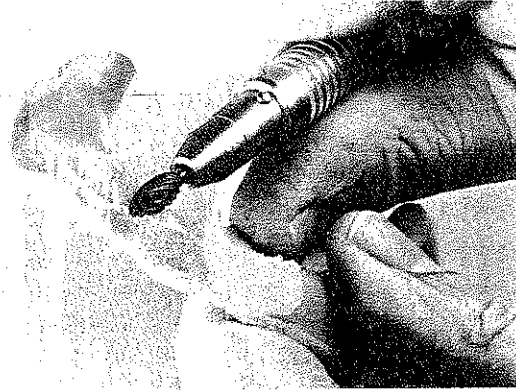
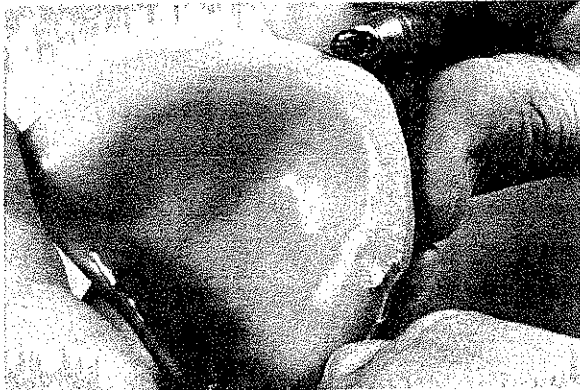

Figure 4:6. It Will Be Necessary to Thin the Vinyl Baseplates Using the Vulcanite Bur and Shorten the Peripheries Until the Criteria of an Acceptable Baseplate are Met.

STEPS IN ADDING WAX OCCLUSAL RIMS TO THE MANDIBULAR AND MAXIL-LARY BASEPLATES

1. Apply sticky wax on several parts of the ridge areas on the top of the mandibular baseplate.
2. Heat one sheet of baseplate wax, and roll it into a cylinder to form the wax occlusal rim.
3. While the rim is still soft, form and adapt it to the baseplate with your fingers.
4. Seal the wax rim to the vinyl baseplate with the large end of a #7 spatula.
5. Modify the occlusal rim to its proper form, cut and shape it with the red-handled knife and with a hot wax spatula to meet the criteria (Figure 4:7).


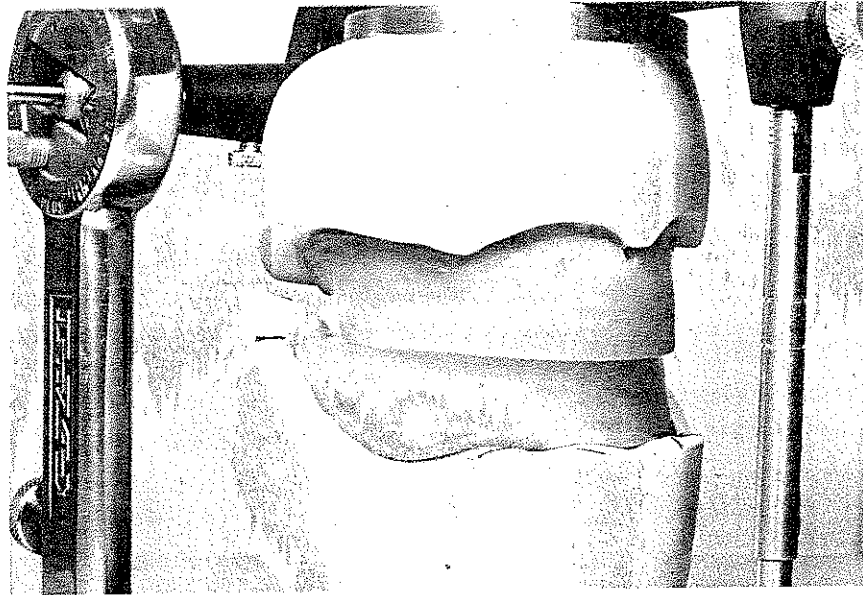



Figure 4:7. The Mandibular Wax Occlusal Rim is Formed According to the Established Criteria.

6. Set the incisal pin flush with the top arm of the articulator.
7. Place the mounted mandibular master cast and baseplate with its occlusal rim on the articulator.
8. Lubricate the top of the mandibular wax occlusal rim with Vaseline.
9. Apply sticky wax on several parts of the ridge areas on the outer surface of the maxillary baseplate.
10. Heat one sheet of baseplate wax, and roll it into a cylinder to form the wax occlusal rim.
11. While the rim is still soft, form and adapt it to the baseplate with your fingers.
12. Seal the wax rim to the vinyl baseplate with the large end of a #7 spatula.
13. Close the articulator until the maxillary wax occlusal rim contacts the mandibular occlusal rim equally in all areas and the incisal pin touches the incisal table.
14. Modify the occlusal rim to its proper form, cut and shape it with the red-handled knife or with a hot wax spatula to meet the criteria. The labial contour of the maxillary occlusal rim is labially oriented and has a horizontal overlap of approximately 2 mms. (Figure 4:8).



A



B

Figure 4:8. A) The Maxillary Wax Occlusal Rim is Formed According to the Established Criteria and B) There Should Be a 2 mm. Horizontal Overlap.

CRITERIA - MANDIBULAR AND MAXILLARY WAX OCCLUSAL RIMS

Evaluate your product using the criteria listed and check the appropriate boxes. After filling in the boxes, take your products and this Study Guide to an instructor for evaluation.

<u>Mandibular Wax Occlusal Rim</u>	<u>Meets Criteria</u>	<u>Does not Meet Criteria</u>	<u>Comments</u>
------------------------------------	-----------------------	-------------------------------	-----------------

Position

1. Centered buccal-lingually over the line drawn along the length of the residual ridge.	<input type="checkbox"/>	<input type="checkbox"/>	
2. 1-2 mms. below the top of the retromolar pad.	<input type="checkbox"/>	<input type="checkbox"/>	
3. Parallel to the residual ridge.	<input type="checkbox"/>	<input type="checkbox"/>	
4. Labially oriented.	<input type="checkbox"/>	<input type="checkbox"/>	

Dimension

1. Width of rim in posterior region approximately 10 mms..	<input type="checkbox"/>	<input type="checkbox"/>	
2. Width of rim anterior region 7-10 mms. (slightly less than in posterior region).	<input type="checkbox"/>	<input type="checkbox"/>	
3. Flat occlusal surface.	<input type="checkbox"/>	<input type="checkbox"/>	

Finish

1. Wax sealed to baseplate.	<input type="checkbox"/>	<input type="checkbox"/>	
2. No wax voids.	<input type="checkbox"/>	<input type="checkbox"/>	
3. Wax surface smooth.	<input type="checkbox"/>	<input type="checkbox"/>	

Maxillary Wax Occlusal Rim


Position

1. Centered buccal-lingually over the line drawn along the length of the residual ridge.	<input type="checkbox"/>	<input type="checkbox"/>	
--	--------------------------	--------------------------	--

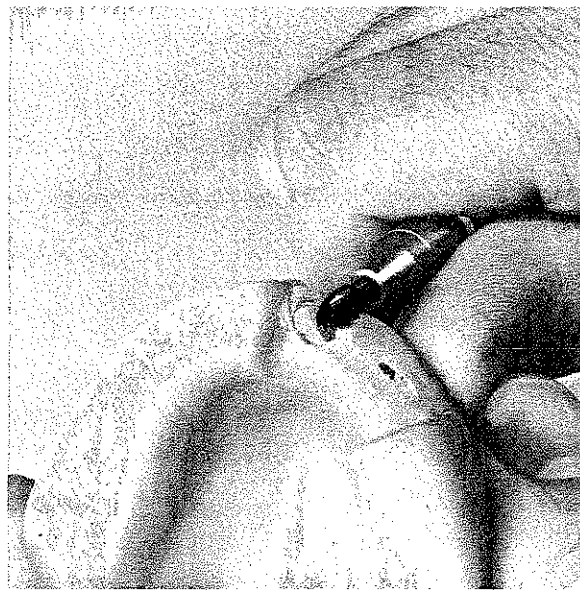
	<u>Meets Criteria</u>	<u>Does not meet Criteria</u>	<u>Comments</u>
2. 1-2 mms. below the top of the retromolar pad.	<input type="checkbox"/>	<input type="checkbox"/>	
3. Parallel to the residual ridge.	<input type="checkbox"/>	<input type="checkbox"/>	
4. Labially oriented.	<input type="checkbox"/>	<input type="checkbox"/>	
<u>Dimension</u>			
1. Width of rim in posterior region approximately 10 mms.	<input type="checkbox"/>	<input type="checkbox"/>	
2. Flat occlusal surface.	<input type="checkbox"/>	<input type="checkbox"/>	
<u>Relationship to Mandibular Wax Occlusal Rim</u>			
1. Has horizontal overlap of 2 mms. in the anterior region.	<input type="checkbox"/>	<input type="checkbox"/>	

STEPS IN SETTING THE MAXILLARY ANTERIOR TEETH

1. Record the midline by scribing a vertical line on the base of the maxillary master cast (Figure 4:9). For this technic procedure, raise and turn the incisal pin and extend the edge of the incisal pin to the master cast base and draw the vertical line representing the midline. Other guides are used to mark the midline of your clinic patients. Remove the occlusal rim on one side from the midline to the approximate area of the first bicuspid. To set the maxillary anterior teeth with the appropriate labial orientation, it will be necessary to grind through the baseplate. Do not be concerned about this hole, because it will be covered with wax in setting the anterior teeth.



A



B

Figure 4:9. A) The Midline is Marked on the Master Cast, and B) a Hole is Cut Through the Baseplate to Facilitate Setting the Central Incisors with the Needed Orientation.

2. Maxillary Central Incisor

Place a small portion of soft baseplate wax on the back of the maxillary central incisor and attach the tooth to the baseplate over the anterior region of the residual ridge. Make certain that the long axis of the tooth is perpendicular to the horizontal, with the incisal edge 1 mm. below the wax occlusal rim. Seal the tooth into position with heated pink baseplate wax (Figure 4:10).




Figure 4:10. The Maxillary Central Incisor is Positioned to Form the Midline and the Appropriate Vertical Overlap.

Make every attempt to use only the amount of wax needed for securely attaching the teeth to the baseplate. All excessive amounts of wax should be removed from the teeth.

NOTE: The maxillary central incisor is the most difficult tooth to set because it establishes the midline and the esthetic support of the patient's lip. For this technic denture, we have used an arbitrary midline, namely the incisal pin. For the clinic patient, the midface is scribed on the maxillary wax occlusal rim by visual inspection. Another valuable guide used clinically to assist in establishing the midline is the incisive papillae. With the baseplate removed from the maxillary master cast, draw a line from the mid-palatal raphe through the papillae to the anterior landing area. Draw a second line to intersect the first at 90° and extend this line bilaterally to the landing areas. When the baseplate is in position, these three lines on the landing areas assist you in positioning the maxillary central incisor. The anterior line forms the midline with the mesial surface of the central incisor. Place the central incisor so that the lingual surface of the tooth is just anterior to a line connecting the two lateral visual guides. These are guides only, and are not infallible when used for your clinic patients (Figure 4:11). Often it is helpful to set both central incisors and thus establish the midline prior to setting the lateral and cuspid.

The proper arrangement of the maxillary and mandibular anterior and posterior teeth relies on the setting of the maxillary central incisors. The required relationship of the maxillary central incisor to the baseplate and to the residual ridge can be seen on the cutaway illustrated in Figure 4:11.

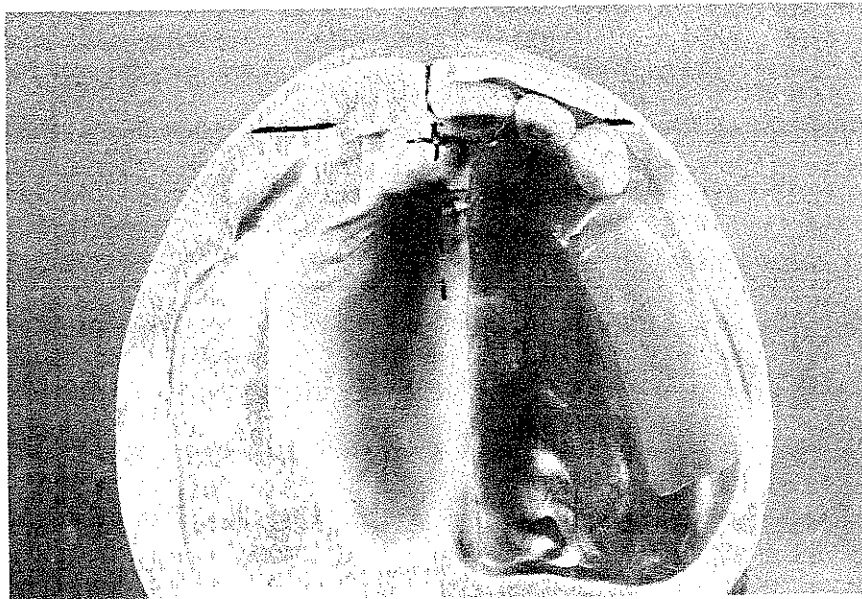


Figure 4:11. The Incisive Papillae can be a Valuable Guide in Positioning the Anterior Teeth.

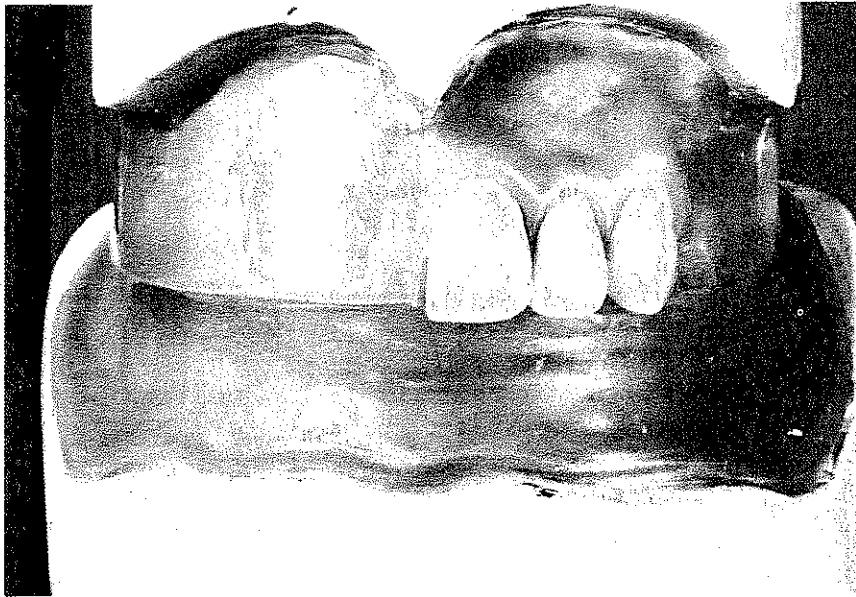


Figure 4:12. The Maxillary Anterior Teeth Set on the Baseplates.

3. Maxillary Lateral Incisor

Place the maxillary lateral incisor next to the central, with the neck slightly depressed. Arrange the incisal edge in symmetry with the central incisor and with the remaining anterior occlusal rim. This incisal edge is even with the remaining maxillary wax occlusal rim, and the incisal edge is parallel with the mandibular wax occlusal rim (Figures 4:11 and 4:12).

4. Maxillary Cuspid

Place the maxillary cuspid so that the anterior one-half of the incisal edge is in symmetry with the lateral and central incisors (Figures 4:11 and 4:12).

The neck of the tooth must be prominent, and the tooth tilted slightly to the distal. Like the central incisor, the incisal tip of the cuspid must be 1 mm. below the maxillary wax occlusal rim.

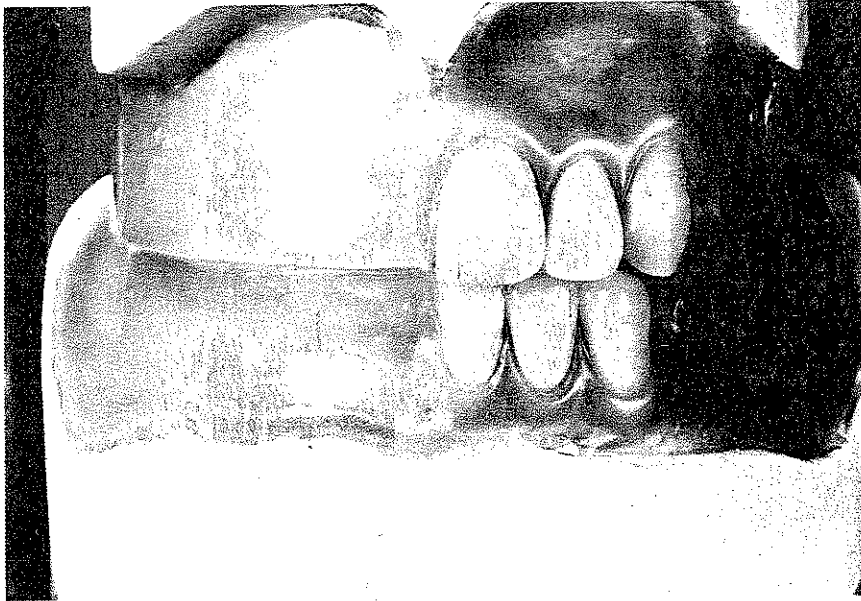


Figure 4:14. Maxillary and Mandibular Anterior Teeth Set on Baseplate.

3. Mandibular Lateral Incisor

Position the lateral incisor next to the central, with the long axis of the tooth directed towards the residual ridge. The incisal edge should be at the height of the wax occlusal rim. The 2 mms. of horizontal overlap between the maxillary and mandibular anterior teeth should be continued.

4. Mandibular Cuspid

Place the mandibular cuspid with the anterior one-half of the incisal edge in symmetry with the lateral and central incisors. Place the incisal tip at or slightly above the mandibular wax occlusal rim. The neck of the tooth is slightly prominent and tilted to the distal (Figure 4:14).

STEPS IN ARRANGING THE REMAINING ANTERIOR TEETH

1. Arrange the remaining anterior teeth on the other sides of the arches to complete the anterior "Set-up" (Figure 4:15).

STEPS IN SETTING THE MANDIBULAR ANTERIOR TEETH

1. Remove the wax on one side from the midline to the approximate area of the first bicuspid. This is similar to the procedure you performed on the maxillary wax occlusal rim when the maxillary anterior teeth were set.
2. Mandibular Central Incisor

Position the central incisor next to the midline and tip it slightly to the labial. Direct the axis of the tooth toward the residual ridge. Be certain that the necks of the teeth are depressed so that they are in from the edge of the baseplate.

The incisal edges of these teeth must be at the height of the mandibular wax occlusal rim. This will result in a 1 mm. vertical overlap ("over-bite") with the maxillary central and cuspid teeth.

A 2 mm. horizontal overlap ("over-jet") must exist between the maxillary and mandibular anterior teeth (Figures 4:13 and 4:14).

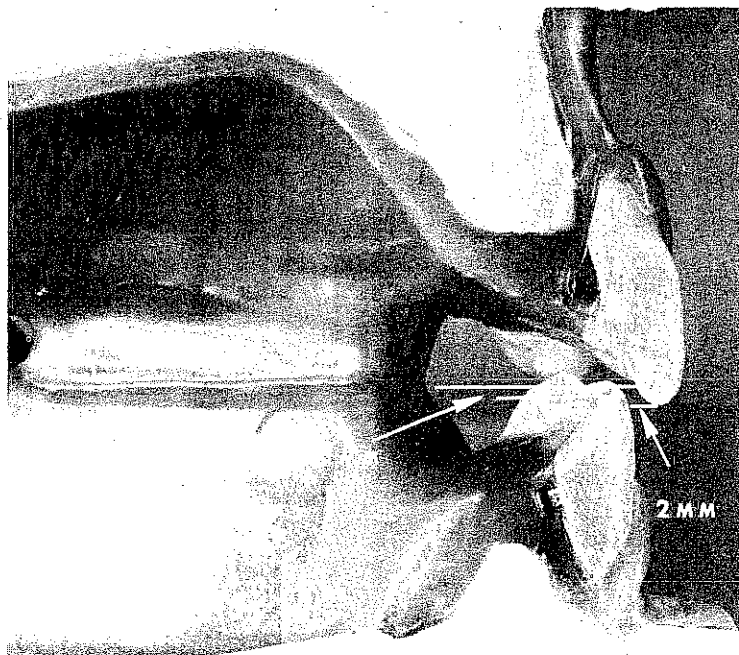


Figure 4:13. The Saggital View Illustrates the Required Relationship of the Maxillary and Mandibular Central Incisors to the Baseplate and the Residual Ridges.

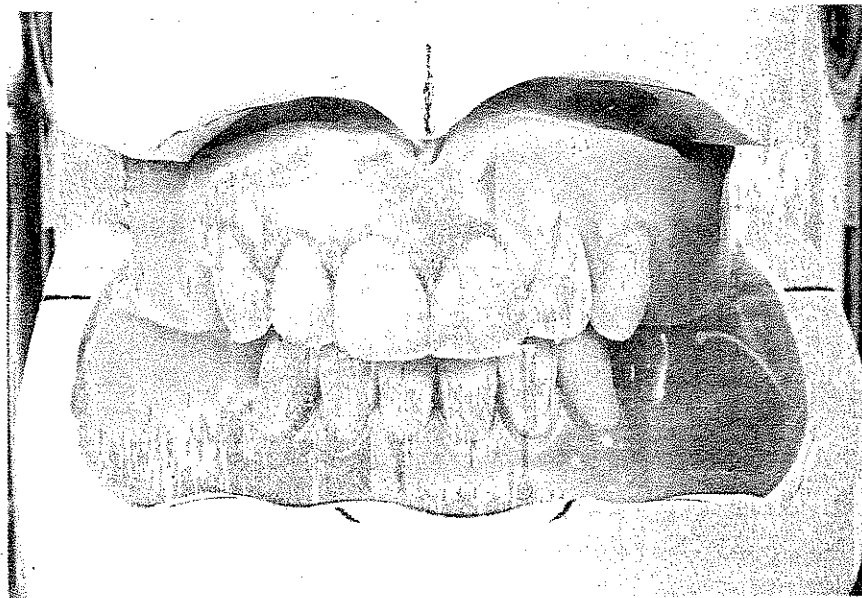


Figure 4:15. Arrange the Remaining Anterior Teeth to Complete the Anterior "Set-up".

2. In order to maintain the set teeth in position, the wax supporting the teeth must be heated and sealed both to the teeth and to the baseplates.
3. It is at this point in the clinical management of a patient that you would evaluate the esthetics of the anterior set-up by a "try-in" appointment with the patient (Figure 4:16).
4. Evaluate your technic anterior set-up to see if the criteria have been met.

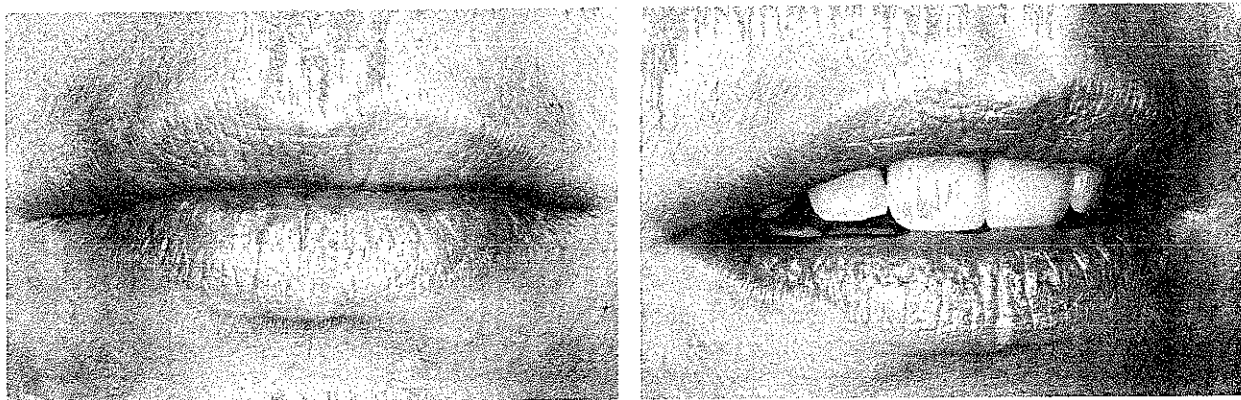


Figure 4:16. Support of the Lips and Face and Tooth Arrangement can be Evaluated at the "Try-In" Appointment.

CRITERIA - SETTING ANTERIOR MAXILLARY AND MANDIBULAR TEETH

Evaluate your product using the criteria listed and check the appropriate boxes. After filling in the boxes, take your products and this Study Guide to an instructor for evaluation.

<u>Maxillary Central Incisors</u>	<u>Meets Criteria</u>	<u>Does not meet Criteria</u>	<u>Comments</u>
1. Labial surface is perpendicular to the horizontal and midline is correct.	<input type="checkbox"/>	<input type="checkbox"/>	
2. Incisal edge 1 mm. below wax occlusal rim.	<input type="checkbox"/>	<input type="checkbox"/>	
3. Sealed in position, no excess wax.	<input type="checkbox"/>	<input type="checkbox"/>	
<u>Maxillary Lateral Incisors</u>			
1. Neck slightly depressed.	<input type="checkbox"/>	<input type="checkbox"/>	
2. In symmetry with central incisors and remaining wax rim.	<input type="checkbox"/>	<input type="checkbox"/>	
3. Incisal edge even with remaining maxillary wax occlusal rim.	<input type="checkbox"/>	<input type="checkbox"/>	
<u>Maxillary Cuspids</u>			
1. Anterior half of incisal edge is in symmetry with lateral and central incisors.	<input type="checkbox"/>	<input type="checkbox"/>	
2. Neck of cuspid prominent and tilted slightly to distal.	<input type="checkbox"/>	<input type="checkbox"/>	
3. Incisal edge 1 mm. below wax maxillary occlusal rim.	<input type="checkbox"/>	<input type="checkbox"/>	
<u>Mandibular Central and Lateral Incisors</u>			
1. Tipped slightly to the labial.	<input type="checkbox"/>	<input type="checkbox"/>	
2. Long axis directed toward the residual ridge.	<input type="checkbox"/>	<input type="checkbox"/>	

	<u>Meets Criteria</u>	<u>Does not meet Criteria</u>	<u>Comments</u>
3. Incisal edges at height of mandibular wax occlusal rim and parallel.	<input type="checkbox"/>	<input type="checkbox"/>	
4. <u>One</u> mm. vertical overlap with the maxillary central and cuspid teeth.	<input type="checkbox"/>	<input type="checkbox"/>	
5. <u>Two</u> mms. horizontal overlap between maxillary and mandibular anterior teeth.	<input type="checkbox"/>	<input type="checkbox"/>	

Mandibular Cuspids

1. Anterior half of incisal edge is in symmetry with lateral and central incisors.	<input type="checkbox"/>	<input type="checkbox"/>	
2. Incisal tip is at or slightly above the mandibular wax occlusal rim.	<input type="checkbox"/>	<input type="checkbox"/>	
3. Neck is slightly prominent.	<input type="checkbox"/>	<input type="checkbox"/>	
4. Neck is tilted <u>slightly</u> to the distal.	<input type="checkbox"/>	<input type="checkbox"/>	
5. Posterior incisal edge is directed over the posterior residual ridge.	<input type="checkbox"/>	<input type="checkbox"/>	

OBJECTIVES

Knowledge. Upon completion of this Procedure, you will be able to:

1. State in sequential order, the steps in setting the:
 - a. Horizontal, lateral, and incisal guidance.
 - b. Lateral condylar guidance.
 - c. Horizontal condylar guidance.
2. State, for the mandibular and maxillary posterior teeth:
 - a. In sequential order, the steps in arranging the teeth.
 - b. The criteria for properly arranged teeth.
3. Identify criteria not met.

Skill. Upon completion of this Procedure, you will be able to:

1. Set the mechanical equivalents of the condylar and incisal guidance on the articulator.
2. Set the mandibular posterior teeth.
3. Set the maxillary posterior teeth.

VIDEOTAPES

1. Mechanical Articulator.

STEPS IN SETTING THE ARTICULATORThe Horizontal and Lateral Condylar Guidance

1. The horizontal condylar guidance is registered from the patient and transferred to the articulator by the patient's protrusive interocclusal registration.
2. For this technic denture, we will arbitrarily set the horizontal condylar guidance bilaterally at 30° mechanical equivalents (Figure 4:17).
3. Set bilaterally the Bennett's angle or lateral condylar guidance at 15° mechanical equivalents (Figure 4:17).


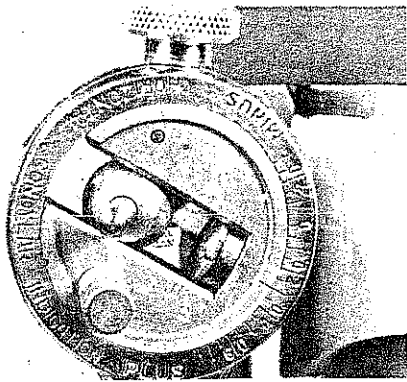


Figure 4:17. The Articulator will be Set Arbitrarily for this Technic Denture as Illustrated.

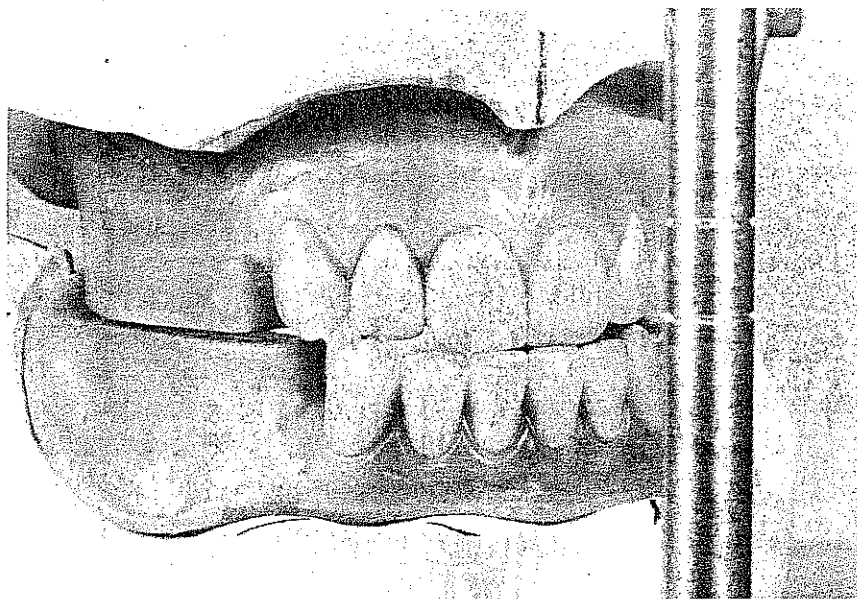
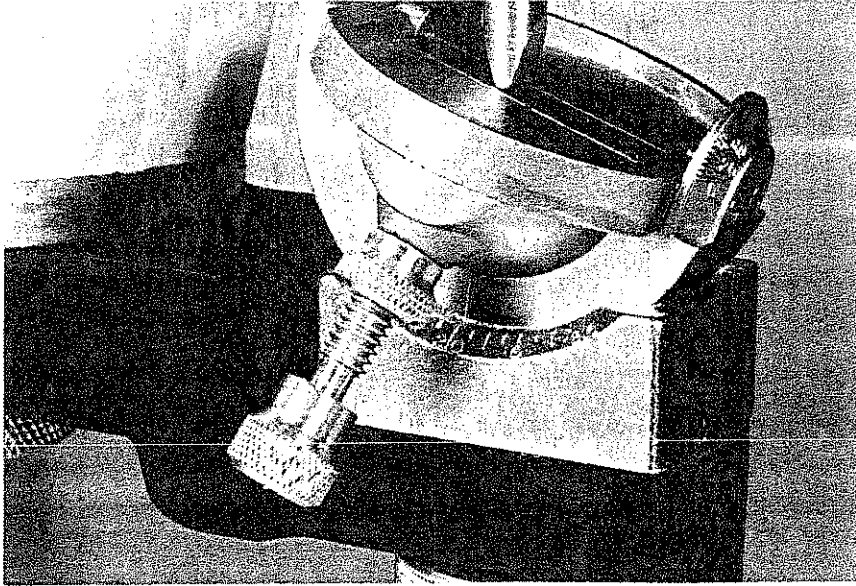


Figure 4:18. The Articulator Condylar Mechanism is Loosened and the Anterior Teeth are Positioned in an Edge-to-Edge Relationship.




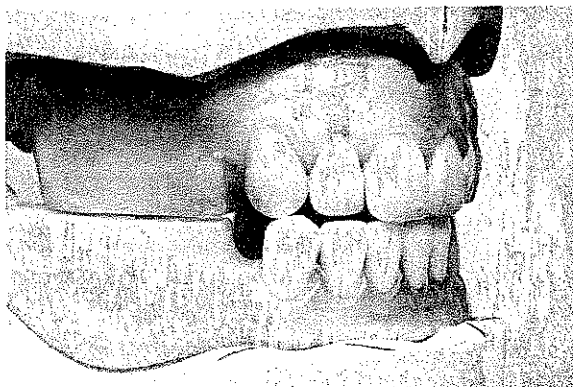


Figure 4:21. The Incisal Pin for this Technic Denture Should Remain in Contact with the Incisal Guide Table in the Lateral Movement.

FACTORS TO CONSIDER IN SETTING MANDIBULAR AND MAXILLARY POSTERIOR TEETH

1. Alignment.

- a. The mandibular posterior teeth are set in a straight line from the cuspid posteriorly.
- b. The central fossae of the mandibular posterior teeth, and therefore, the lingual cusps of the maxillary teeth ~~will~~ ^{should} be placed over the center of the stress-bearing area of the mandibular residual ridge. ~~In this technic Procedure, the center is along the top of the well formed residual ridge.~~
- c. The guides for setting the mandibular posterior teeth are the same lines that were drawn on the landing areas to assist in positioning the mandibular wax occlusal rim.

2. Occlusal Plane.

- a. The buccal and lingual cusp tips of the mandibular posterior teeth are set at the same height in order to establish the proper occlusal plane. The cusp tips are positioned level with the wax occlusal rim which is 1-2 mms. below the top of the retromolar pad.

- b. The long axes of the teeth are arranged perpendicular to the occlusal plane as viewed from the buccal.

STEPS IN ARRANGING THE MANDIBULAR POSTERIOR TEETH

1. Remove the remaining mandibular wax occlusal rim from the cuspid posterior on one side.
2. Mandibular Bicuspid.

The bicuspid are the first teeth to be set. Place the cusp tips level with the established plane of occlusion using the posterior reference line and the mandibular cuspid (Figure 4:22).

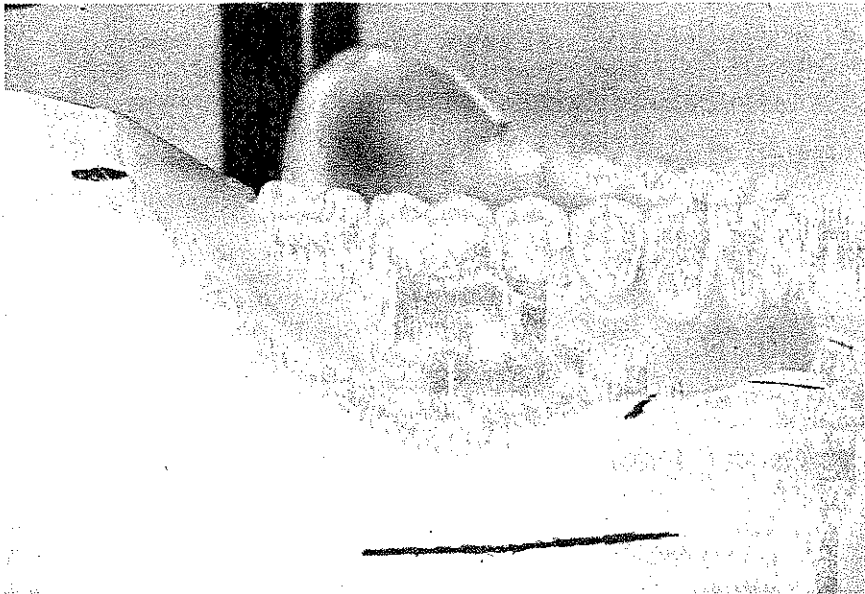


Figure 4:22. The Buccal and Lingual Cusp Tips are at the Same Height in Order to Establish the Occlusal Plane. The Height of the Mandibular Cusp Tips is 1-2 mms. below the Top of the Retromolar Pads.

The central grooves of the first and second bicuspids should be in line with the distal incisal line angle of the lower cuspid and should be directed posteriorly, intersecting with the center of the retromolar pad and the posterior reference line. This normally positions the tooth over the stress bearing area of the mandibular residual ridge (Figure 4:23).

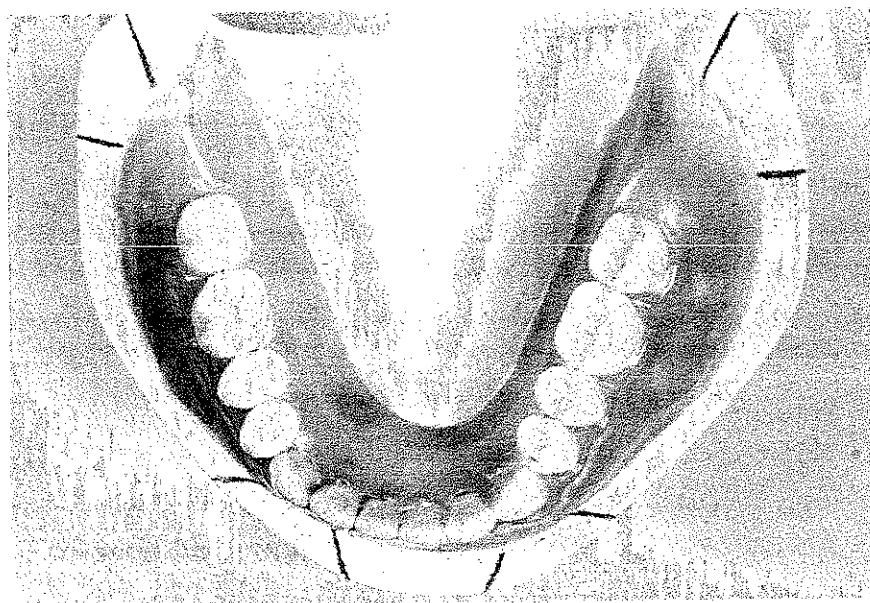


Figure 4:23. The Center of the Stress Bearing Area of the Mandibular Residual Ridge is Extended as a Line Drawn onto the Boxing Edge and Helps position the Posterior Teeth.

As you set the teeth, make sure the cusp tips of the mandibular teeth align with the wax occlusal rim. Use the mandibular wax occlusal rim on the opposite side of the arch, the maxillary wax occlusal rim, and also the anterior teeth as guides.

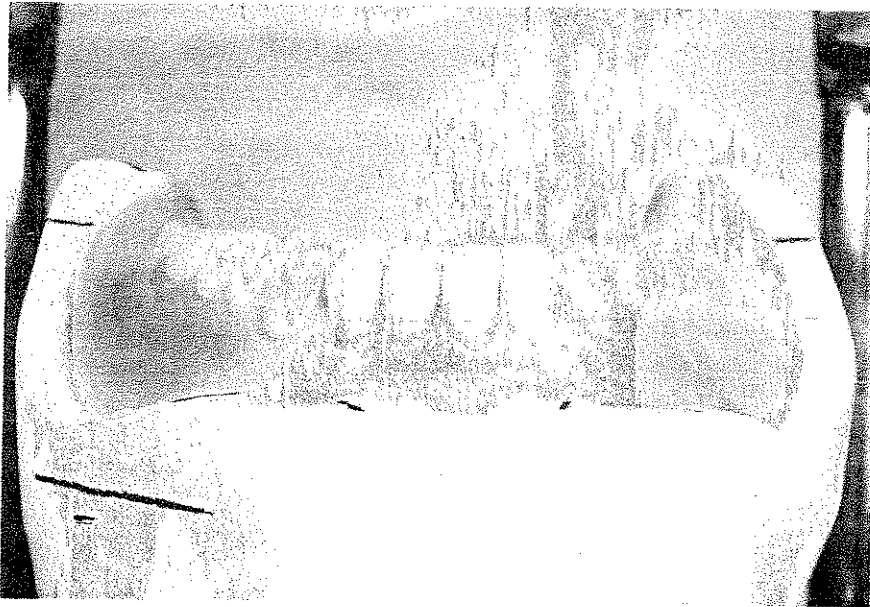


Figure 4:24. The Anterior Teeth, Posterior Reference Lines and the Maxillary Wax Occlusal Rim are Used as Guides to set the Posterior Teeth.

3. Mandibular Molars.

Place the mesial marginal ridge of the first molar even with the distal marginal ridge of the second bicuspid and perpendicular to the occlusal plane. The central groove of the first molar should also be located along the line from the cuspid tip to the center of the retromolar pad and the posterior reference line (Figure 4:22 and 4:23).

Position the second mandibular molar using the available references and the remaining wax occlusal rim. The mandibular posterior teeth should be 1-2 mms. below the top of the retromolar pad and the long axes of the teeth perpendicular with the occlusal plane (Figure 4:22).

4. Remaining Mandibular Posteriors.

The posterior teeth on the opposite side of the mandibular arch are now arranged.

STEPS IN ARRANGING THE MAXILLARY POSTERIOR TEETH

1. The Maxillary Molars.

The first molar should be set in a Class I molar relationship with the mandibular first molar.

The maxillary first molar is positioned, supported by a softened piece of pink baseplate wax, and the articulator is closed. The mesial lingual cusp is seated into the central fossa of the mandibular first molar. Be certain that the lingual cusp of the maxillary first molar interdigitates perfectly with the central fossae and marginal ridges of the mandibular tooth. This will assure the proper buccal horizontal overlap (overjet) of the maxillary buccal cusps (Figures 4:25 and 4:26).

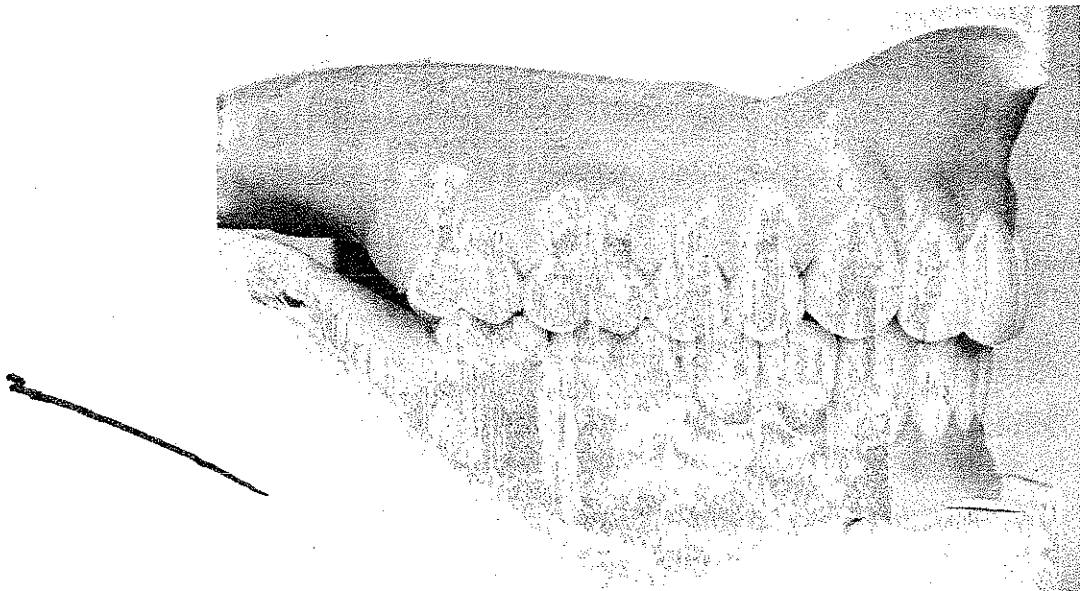


Figure 4:25. The Maxillary Posterior Teeth Should be Set in a Class I Molar Relationship.

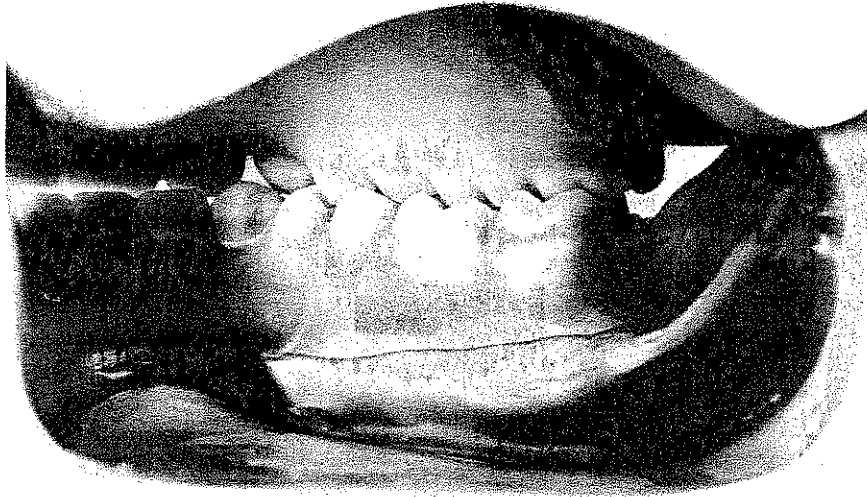


Figure 4:26. The Lingual Cusps Must Interdigitate Perfectly with the Central Fossae and Marginal Ridges of the Mandibular Posterior Teeth.

2. Maxillary Bicuspid(s).

In setting the maxillary bicuspid(s) the lingual cusp contact and the buccal horizontal overlap are emphasized. Position each bicuspid individually supported by a softened piece of pink baseplate wax and close the articulator. Manipulate each tooth until correct positive seating is observed (Figure 4:25 and 4:26).

3. Maxillary Second Molars.

When both the first and second maxillary bicuspid(s) are properly oriented, position the maxillary second molars. Be certain the lingual cusp of this molar interdigitates properly with the mandibular antagonist (Figures 4:25 and 4:26).

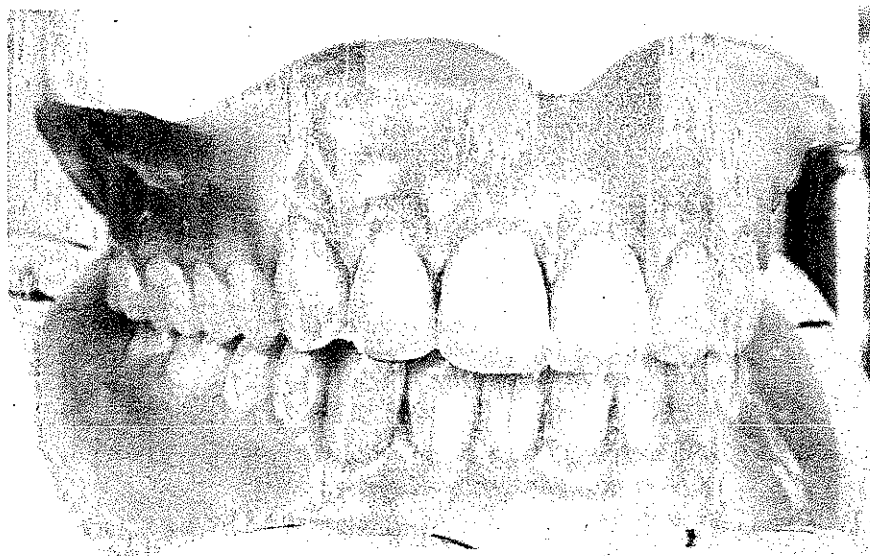


Figure 4:27. The Remaining Posterior Teeth are Set. Positive Interdigitation of the Maxillary Lingual Cusps with the Posterior Mandibular Teeth is Emphasized.

4. Remaining Maxillary Posteriors.

The posterior teeth on the opposite side of the maxillary arch are now arranged (Figure 4:27).

5. When the teeth are all arranged and supported by pink baseplate wax, evaluate your set-up using the criteria listed.

CRITERIA - SETTING MANDIBULAR AND
MAXILLARY POSTERIOR TEETH

Evaluate your product using the criteria listed. After filling in the sheet, take your products and this Study Guide to an instructor for evaluation.

	<u>Meets Criteria</u>	<u>Does not meet Criteria</u>	<u>Comments</u>
1. Mandibular posterior teeth arranged in straight line from cuspid tip posteriorly.	<input type="checkbox"/>	<input type="checkbox"/>	
2. Central fossae of mandibular posterior teeth are over the center of the stress-bearing area of the mandibular residual ridge.	<input type="checkbox"/>	<input type="checkbox"/>	
3. Buccal and lingual cusp tips of mandibular posterior teeth are at the same height.	<input type="checkbox"/>	<input type="checkbox"/>	
4. Mandibular posterior buccal and lingual cusp tips are 1-2 mms. below the top of the retro-molar pads.	<input type="checkbox"/>	<input type="checkbox"/>	
5. Lingual cusps of the maxillary teeth interdigitate with the central fossae and the marginal ridges of the mandibular teeth.	<input type="checkbox"/>	<input type="checkbox"/>	

OBJECTIVES

Knowledge. Upon completion of this Procedure, you will be able to:

1. State in sequential order, the steps in:
 - a. Verifying the relationships of the maxillary and mandibular anterior teeth.
 - b. Aligning the occlusal plane.
 - c. Balancing the occlusion of the maxillary and mandibular posterior teeth.
2. Describe for a, b, and c the methods for making adjustments.
3. Name the criteria for properly balanced occlusion for all teeth in lateral and protrusive excursions.

Skill. Upon completion of this Procedure, you will be able to:

1. Balance the occlusion of the maxillary and mandibular anterior and posterior teeth.

VIDEOTAPES

1. Types of Posterior Artificial Teeth.
2. Interdigitation of the Pilkington-Turner Tooth.
3. Posterior Teeth - Balanced Occlusion.

MATERIALS NEEDED FOR PROCEDURE #11

1. Bunsen burner.
2. #7 spatula.
3. Pink baseplate wax.
4. Occluded set-up.

STEPS IN BALANCING THE OCCLUSION OF THE MAXILLARY AND MANDIBULAR POSTERIOR TEETH

1. Verify Relationships of the Anterior Teeth. Remove all the maxillary posterior teeth. The horizontal condylar guidance should be set bilaterally at 30° mechanical equivalents. The lateral condylar guidances should be 15° mechanical equivalents.

When you have the articulator properly set, loosen the condylar elements and move the articulator into lateral and protrusive excursions. This will allow you to check the horizontal incisal guidance set on the articulator.

The maxillary centrals and cuspids must pass over the incisal edges of the lower anterior teeth with only a slight contact when the incisal pin is in contact with the incisal guide table. The range of movement at the incisal table used to examine the occlusion for balance is approximately 2 mms. or 1/2 the width of the incisal pin (Figure 4:28).

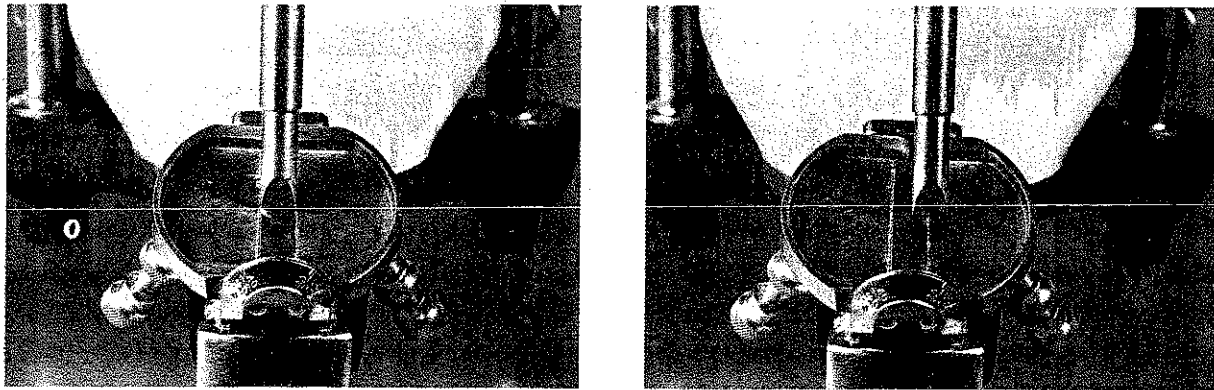


Figure 4:28. The Range of Movement at the Incisal Table is Approximately 2 mms. or 1/2 the Width of the Incisal Pin.

If the incisal pin is coming off the incisal guide table and the degrees mechanical equivalents is already 30° , the occlusion between the maxillary and the mandibular anteriors must be altered. The changes required are to increase the horizontal overlap or decrease the vertical overlap relationships. Adjustment is usually made by moving the maxillary teeth up and slightly forward.

Cuspid interference can be corrected by changing the maxillary cuspid position slightly or depressing the incisal edge of the mandibular cuspid. Reset the incisal guide table if these changes are necessary.

2. Align the Occlusal Plane. The mandibular posterior teeth are arranged in a straight line from the cuspid posteriorly to the reference line on the landing edge.

The central fossae of the mandibular posterior teeth are placed over the center of the mandibular residual ridge, as viewed from the occlusal.

The buccal and lingual cusp tips of the mandibular posterior teeth are at the same height. The cusp tips form the occlusal plane which should be level with the incisal plane of the anteriors. The occlusal plane extends posteriorly 1-2 mms. below the top of the retromolar pads.

To achieve these relationships, the posterior teeth can be tipped or tilted slightly in the buccal-lingual direction. The teeth should not be tipped or tilted in the anteroposterior direction since the long axes of the teeth should remain vertical or perpendicular to the occlusal plane (Figures 4:29 and 4:30).

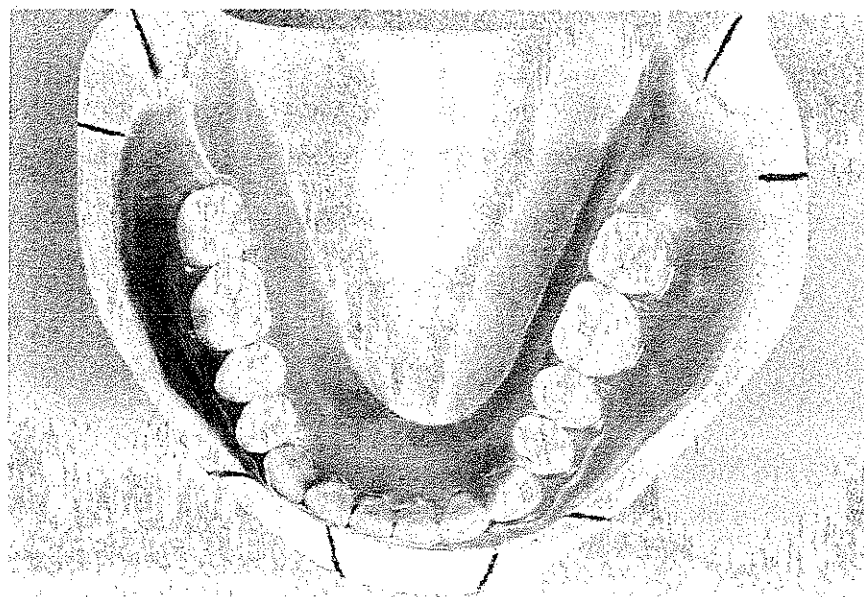


Figure 4:29. The Alignment of the Mandibular Posterior Teeth are in a Straight Line from the Cuspid to the Posterior Reference Line.

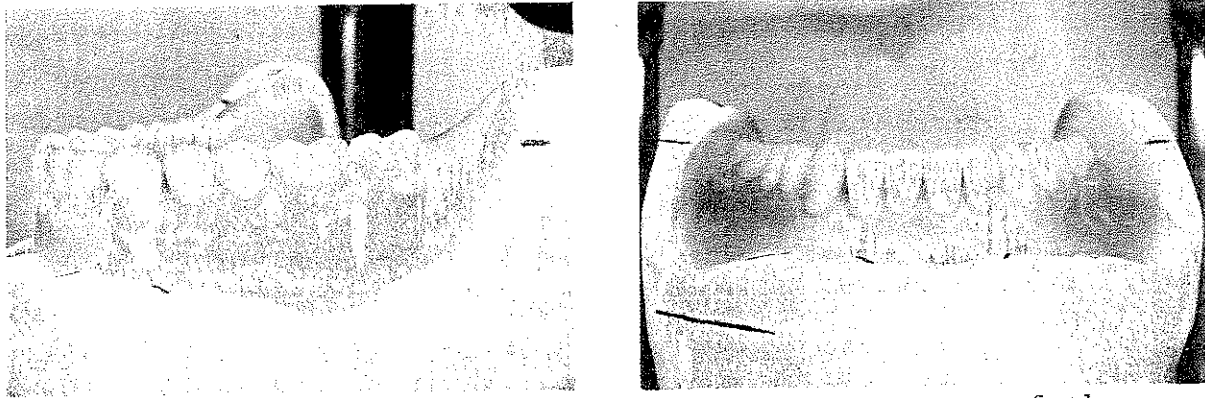


Figure 4:30. The Relationship of the Long Axes of the Teeth and the Buccal and Lingual Cusp Height are Also Verified.

3. Balance the Occlusion. The concept of occlusion presented requires centric occlusion being established at centric relation. From this maximum intercuspal position opposing teeth should be able to glide over each other in nonrestrictive lateral and protrusive movements. This area around centric occlusion laterally and anteriorly should allow at least 2 mms. of unrestricted movement in any excursion from centric occlusion.

One can come quite close to developing the concept of balanced posterior occlusion with a light contact of the anterior teeth in all excursions by arranging the selected posterior teeth and following specific guidelines.

The articulation of supplied teeth was designed for specific cusps of maxillary teeth and mandibular to travel specific pathways of their anatagonists. Careful consideration must be given to this contact relationship when setting the teeth to establish occlusal balance. When these gliding relationships cannot be attained, selective grinding will be required to develop a balanced tooth contact during movements. The selective grinding usually follows the processing of the complete dentures presented in Section Five.

CENTRIC OCCLUSION

1. Position the maxillary posterior teeth one at a time in centric occlusion. Maximum interdigitation is again essential (Figures 4:31 and 4:32).

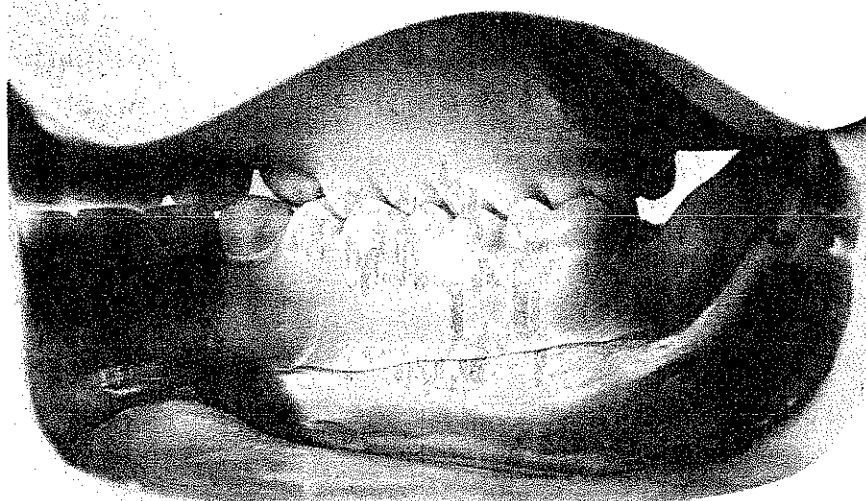
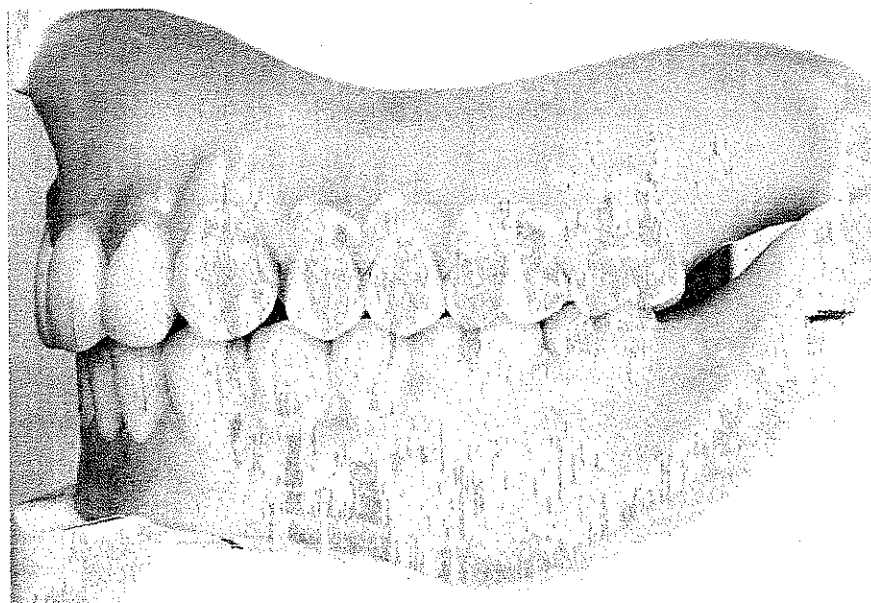


Figure 4:31. The Maxillary Posterior Teeth are Positioned Using the Criteria. Maximum Lingual Cusp Interdigitation is Essential.

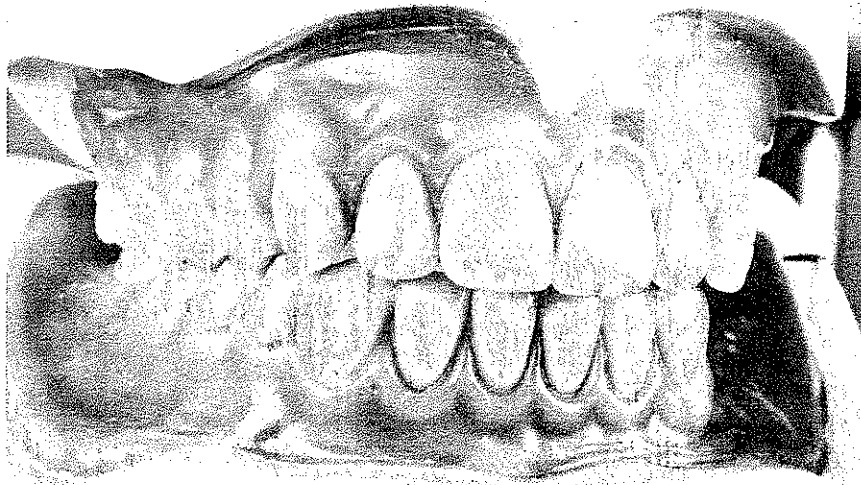


Figure 4:32. The Occlusal Plane and the Buccal Overlap of the Posterior Teeth Should be Evaluated Against the Established Criteria.

LATERAL MOVEMENTS

1. Develop working contacts between all maxillary buccal cusps as they pass through the embrasures of all mandibular cusps (Figure 4:33). At the same time, balancing contacts must exist on the other side of the arch between the maxillary lingual cusps and the mandibular buccal cusp occlusal inclines (Figures 4:33 and 4:34).
2. Move the articulator through lateral excursions and develop the working and balancing relationship for each tooth as it glides over the occlusal surface of its mandibular anatagonists.
3. These occlusal contacts must occur for a movement of at least 2 mms. of the incisal pin. The incisal pin must remain in contact with the incisal table during the lateral excursions.
4. Teeth that contact prematurely or too heavily in either working or balancing may be moved by heating the pink baseplate wax with the hot #7 wax spatula and adjusting the maxillary tooth.
5. When you return to centric occlusion, the maxillary lingual cusps must remain seated in the mandibular fossae or in contact with the appropriate marginal ridges.

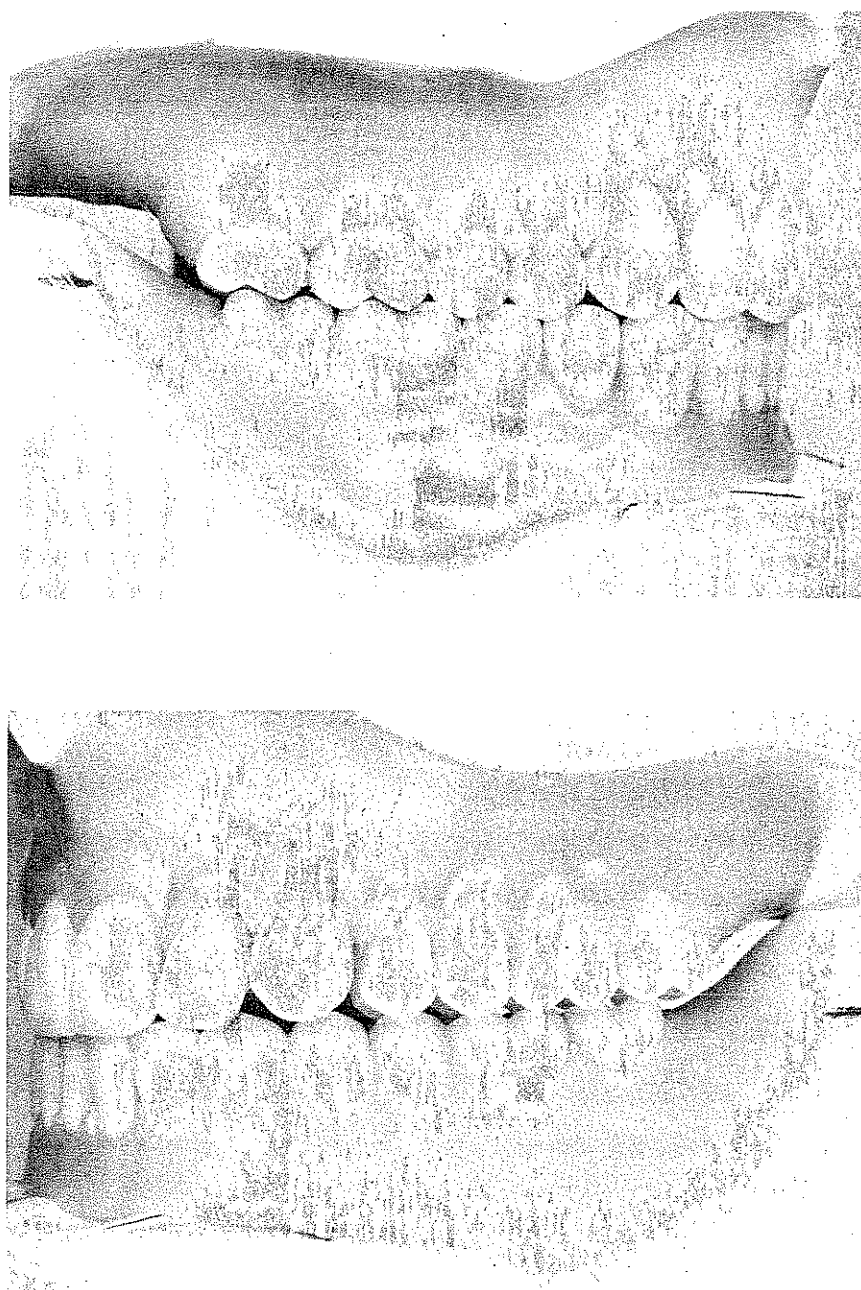


Figure 4:33. Right Lateral Movement and the Contact Relationships Required.

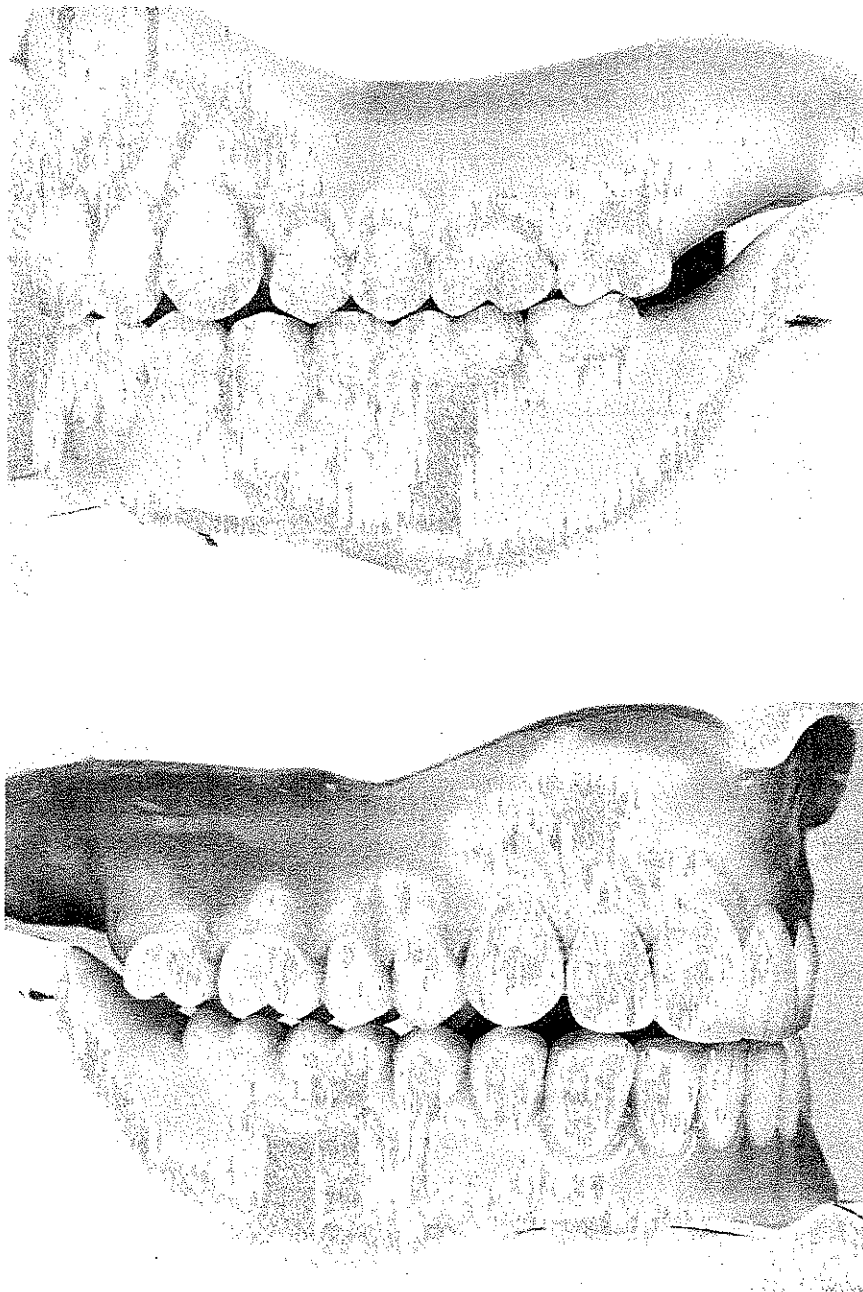


Figure 4:34. Left Lateral Movement and the Contact Relationships Required.

PROTRUSIVE MOVEMENT

1. Move the articulator into a protrusive movement. Posterior protrusive contacts must occur between the maxillary buccal cusps (distal inclines) and the mandibular buccal cusps (mesial inclines) (Figure 4:35).
2. Contacts may also occur between the maxillary lingual cusps and the marginal ridges and distal inclines of the lingual cusps of the mandibular posterior teeth. The protrusive contacts must occur during a 2 mm. protrusive movement as observed at the incisal table.
3. As each posterior tooth is set, one should evaluate the working, balancing, and protrusive contacts and make the necessary adjustments by softening the pink baseplate wax and manipulating the tooth.
4. After you complete one side of the maxillary arch, continue setting teeth on the other side while adjusting the working, balancing, and protrusive contacts on these remaining teeth. Be sure also to adjust and evaluate the cross-arch working, balancing, and protrusive contacts.

In other words, bilateral balanced occlusion requires the establishment of a good working balance on one side of the arch, while similarly balancing contacts are present on the other side of the arch. In the protrusive movement, bilateral contact also must be observed.

5. After balancing the occlusion, evaluate your set-up using the criteria listed.

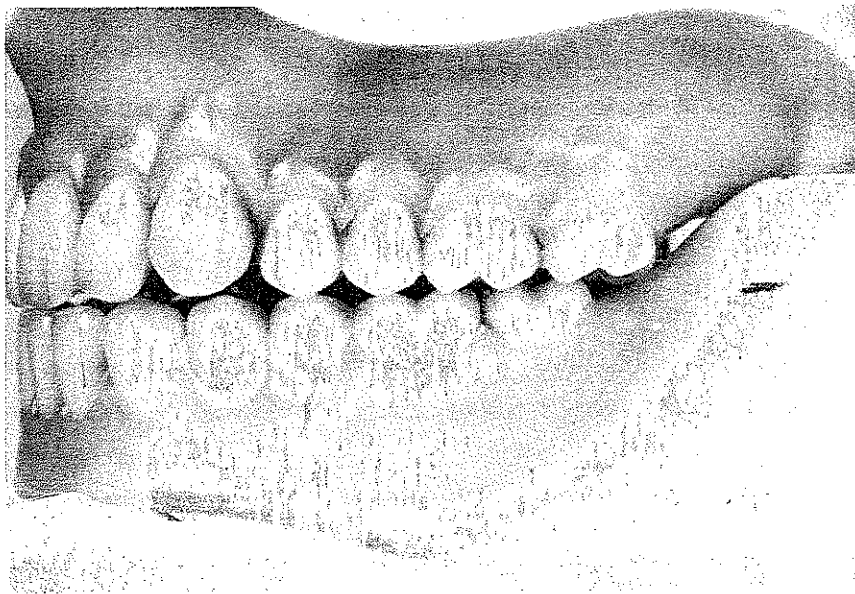
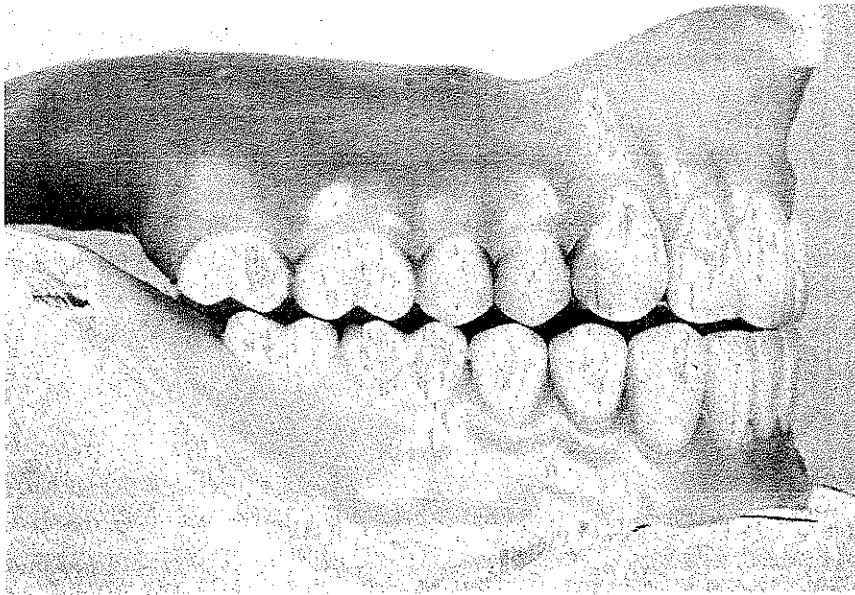


Figure 4:35. Protrusive Movement and the Contact Relationships Required.

CRITERIA - BALANCING THE MAXILLARY AND MANDIBULAR TEETH

Evaluate your product using the criteria listed. After filling in the sheet, take your products and this Study Guide to an instructor for evaluation.

<u>Articulator</u>	<u>Meets Criteria</u>	<u>Does not meet Criteria</u>	<u>Comments</u>
1. Articulator set bilaterally with 30° horizontal condylar guidance. Bennett angle is 15° bilaterally. Horizontal incisal guidance is no greater than 30° with lateral wings set flat.	<input type="checkbox"/>	<input type="checkbox"/>	
<u>Anterior Teeth</u>			
1. With movement of articulator through lateral and protrusive excursions, maxillary centrals and cuspids will pass over incisal edges of lower anterior teeth with only slight contact when the incisal pin is in contact with the incisal table.	<input type="checkbox"/>	<input type="checkbox"/>	
<u>Posterior Teeth</u>			
1. Mandibular posterior teeth are arranged in a straight line.	<input type="checkbox"/>	<input type="checkbox"/>	
2. The central fossae of the mandibular posterior teeth are placed over the center of the mandibular residual ridge.	<input type="checkbox"/>	<input type="checkbox"/>	
3. When viewed from the buccal: The buccal and lingual cusp tips of the mandibular posterior teeth are even.	<input type="checkbox"/>	<input type="checkbox"/>	

	<u>Meets Criteria</u>	<u>Does not meet Criteria</u>	<u>Comments</u>
4. The occlusal plane should extend posteriorly 1 to 2 mm. below the top of the retro-molar pad.	<input type="checkbox"/>	<input type="checkbox"/>	
5. The long axes of the posterior teeth are vertical.	<input type="checkbox"/>	<input type="checkbox"/>	
6. In centric occlusion, all maxillary lingual cusps are seated in the mandibular fossae.	<input type="checkbox"/>	<input type="checkbox"/>	

Occlusal Balance. (Evaluate occlusion while a movement of 2 mms. of the incisal pin on the incisal table is being made.)

1. Working contacts are present between the maxillary buccal cusps as they pass through the embrasures of the mandibular teeth.	<input type="checkbox"/>	<input type="checkbox"/>	
2. There are balancing contacts between the maxillary lingual cusps and the mandibular buccal cusps.	<input type="checkbox"/>	<input type="checkbox"/>	
3. There are protrusive contacts between the maxillary buccal cusps and the mandibular buccal cusps.	<input type="checkbox"/>	<input type="checkbox"/>	

SELF TEST 4
ARRANGING ANTERIOR TEETH,
ARRANGING POSTERIOR TEETH, BALANCING THE OCCLUSION

(Circle correct response(s) or write brief answers. For correct answers, consult the Answer Key.)

- T F 1. The anterior teeth in a complete denture setup should always have 1 mm. of vertical overlap and 2 mms. horizontal overlap.
2. The mistake(s) shown in the maxillary anterior tooth setup in Figure T4:1 is (are):
- a. Incorrect overlap of maxillary anteriors.
 - b. Maxillary central incisors tilted to mesial.
 - c. Necks of maxillary lateral incisors not depressed.
 - d. Maxillary cuspid neck depressed.

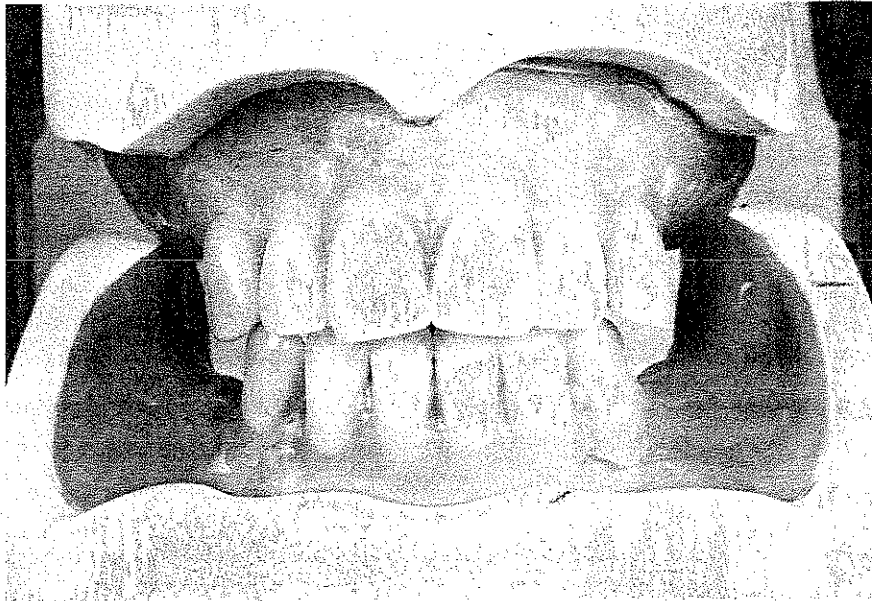


Figure T4:1

- T F 3. It is important to remember when the denture teeth are in working relationship on one side they are in balancing relationship on the other side.
- T F 4. When balancing the denture teeth for a patient, the condylar guidance of the articulator should always be set at 30°.
5. The mistake(s) shown in the mandibular anterior tooth setup in Figure T4:2 is (are):
- The mandibular anterior teeth are not placed parallel to the occlusal plane.
 - The mandibular anterior teeth are placed too far to the labial in relation to the residual ridge.
 - The necks of the mandibular anterior teeth are too depressed.
 - The mandibular anterior teeth are above the height of the retromolar pads.

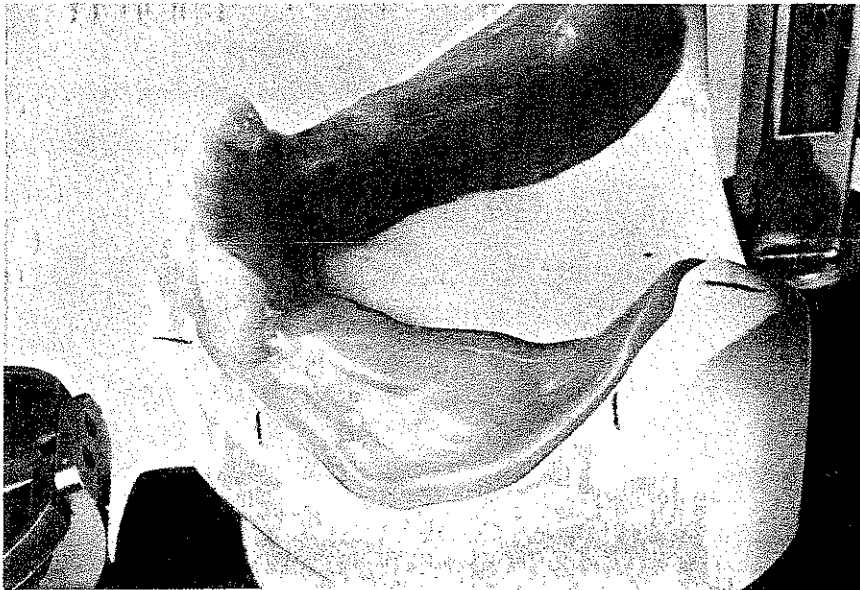

Figure T4:2

- T F 6. The central fossae of the maxillary posterior teeth must be positioned so that they are over the buccal shelf area of the mandible.
- T F 7. During the setting of the posterior denture teeth, it is important to remember that we are establishing centric relation at this time.
8. The major mistake(s) in the denture setup illustrated in Figure T4:3 is (are):
- a. The teeth used in the setup are too long.
 - b. The occlusal plane is not parallel to the mean of the residual ridge.
 - c. The anterior teeth are too far forward.
 - d. Posterior teeth are above the retromolar pad.

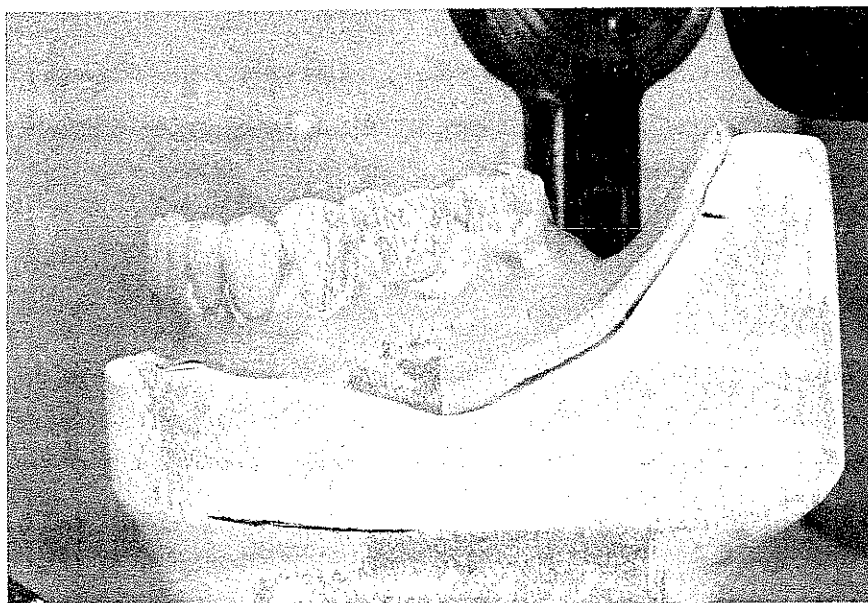
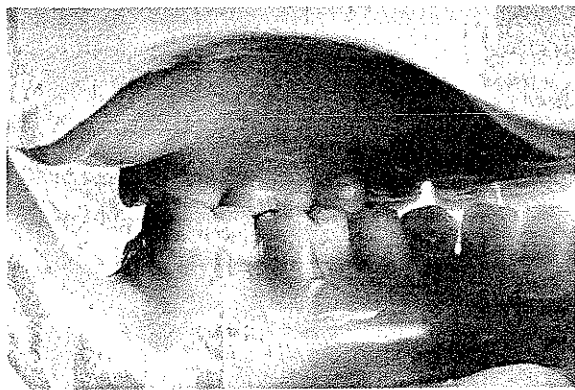
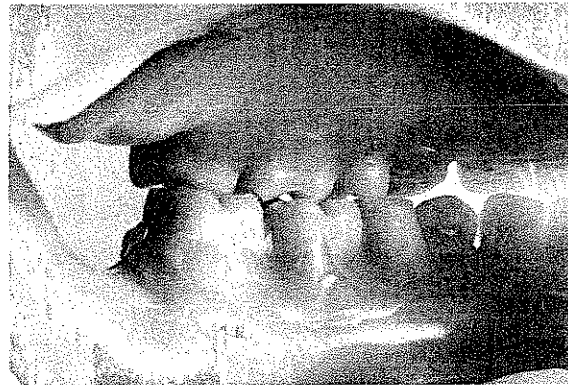


Figure T4:3

9. When balancing the complete denture setup, the occlusion should be evaluated with the incisal pin moving:
- 0 mms.
 - 2 mms.
 - 4 mms.
 - 10 mms.
10. The major fault of the posterior denture tooth setup shown in Figure T4:4 is (are):
- Occlusal plane high.
 - Lack of lingual interdigitation.
 - Denture teeth too short.
 - Excessive compensating curve.



A



B

Figure T4:4

11. The major error illustrated in Figure T4:5 shows the mandibular posterior teeth:
-

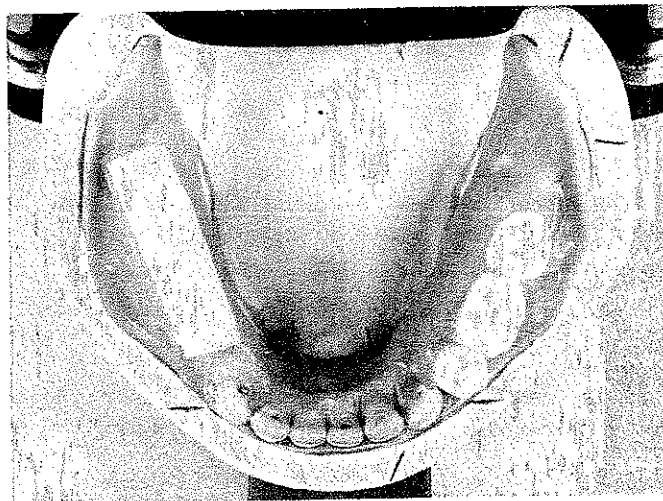


Figure T4:5

12. In Figure T4:6 the major error in the maxillary anterior tooth arrangement is:
-

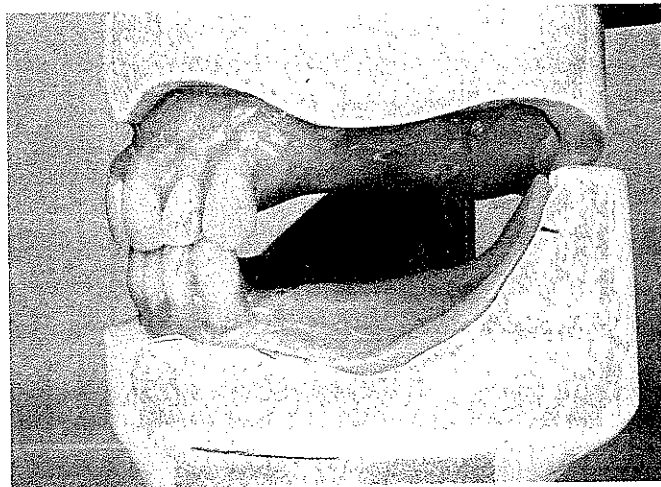


Figure T4:6

COMPUTER-GENERATED SECTION TEST 4

You are now ready to take Computer-Generated Section Test 4, which will cover:

1. Setting the anterior teeth.
2. Setting the posterior teeth.
3. Balancing the occlusion.

When you have completed the laboratory procedures which this Section Test covers and are ready to take this test, go to the Caident Center. All Section Tests are on the computer. The proctor in the Caident Center will instruct you on how to take the test. As you take the test, the computer will inform you of your incorrect answers and tell you the correct answer. As soon as you have completed the test, the computer will display your score. Call the proctor to record your score on the Clinic Progress Card.

There are 10 items in this test. The criterion level (the required correct score) is 80%.

WAXING THE COMPLETE DENTURES, MAKING
THE OCCLUSAL INDEX, FLASKING THE
COMPLETE DENTURES, MIXING ACRYLIC
RESIN AND PACKING THE COMPLETE DENTURES

SECTION

5

OBJECTIVES

Knowledge. Upon completion of this Section, you will be able to:

1. Describe the relationship of the contoured wax dentures to the finished prosthesis.
2. State the criteria required in waxing the dentures.
3. Properly fill out a Laboratory Work Authorization Order, using the University of Michigan Standard Laboratory Form.
4. Name and describe the two kinds of reactions that take place during the processing of powder-liquid types of dental resins.
5. State the consequences of exceeding the boiling point of methyl methacrylate monomer.

Skill. You will develop the skills necessary to complete Procedure 12, and although you will not perform Procedures 13 and 14 in the Preclinical course, you should know how they are done in order to understand their significance in the overall management of the complete denture patient.

WAXING THE COMPLETE DENTURE

This procedure is as important as any other procedure in the construction of complete dentures. Establishing the proper contours and thickness of the denture base aids in the successful functioning of the dentures, as well as providing desirable esthetics. Careless waxing may cause difficulty when preparing the dentures for delivery. In order to learn to wax a denture properly, ". . .one should first polish a processed denture which has been improperly waxed. The difficulties encountered would emphasize the need for more careful waxing."¹

For a discussion of base thickness, degree of softness of the wax used, and effects of the contours on the movements of the oral structures, read the short references listed.

OCCLUSAL INDEX

Great care was taken to record the relationship of the maxillary arch to the opening axis of the jaws and to orient the maxillary master cast in this same relationship to the opening axis of the articulator when we used the face-bow. The vertical and horizontal maxillomandibular jaw relationships were also recorded with as much accuracy as possible. Try as we may to be accurate in our clinic and laboratory procedures some errors will be present in the finished restorations. Correction of these errors usually takes place following the processing of the dentures. The processing of the dentures in acrylic resin may alter the horizontal and vertical tooth to tooth relationships. Procedures to correct the laboratory discrepancies will be discussed later. The occlusal index is a necessary item to aid in correction of the clinically introduced discrepancies.

Following processing, new interocclusal records must be obtained from the patient, and the operator must remount the dentures on the articulator to correct these occlusal changes. Unless some method is used to preserve the original mounting of the maxillary cast on the articulator, the original settings of the articulator will no longer be valid. Therefore, an occlusal index is obtained before the dentures are sent to the laboratory.

PREPARING THE WORK AUTHORIZATION ORDER

The dentist must communicate clearly with the dental laboratory technician if he expects to obtain satisfactory service from the dental laboratory. Complete instructions must be written legibly on a laboratory form and must be signed by a licensed dentist (Figure 5:1).

For this technic procedure:

1. Fill out the standard laboratory form in triplicate.
2. Obtain the instructor's signature.
3. Take the waxed dentures on the master casts to the School's Dental Laboratory on the first floor, along with the laboratory copy (white copy) of the standard laboratory form. (Keep the other copies.) Pick up the finished denture on the date specified by the laboratory when they will be done.

LABORATORY COPY

The U. of M. School of Dentistry
 1011 North University
 Ann Arbor, Michigan 48104

Lab. Case No.:

Patient Name Soph. Tech. C.D. Age: _____
 Sex: _____

PATIENT REG. NO. <u>623</u>						CLINICAL DEPARTMENT <u>COMP. DENT AREA</u>								
<u>9</u>	<u>9</u>	<u>9</u>	<u>9</u>	<u>9</u>	<u>9</u>	S1 CD	S2 CR	S8 OCCL	S9 OP	61 ODC	65 ORTHO	66 PD	67 PEDO	80 MIS

Date: Present Finish Date: will specify

Material
 Gold Acrylic
 Chrome Alloy Porcelain

Mould
 Shade
 Make

Instructions _____ Type and Description of Case
 Please Give Complete Instructions

1. Process dentures in heat-activated acrylic resin.
2. Return processed dentures on master casts for split-cast remount.
3. Do not finish.

Student: Your Name Bench _____ Cubical No: Your No.

FURTHER INSTRUCTIONS AND DESIGN ON BACK OF FORM

Dentist's Signature Your Instructor D.D.S.

Commercial Laboratory: I.L.M. license No: Instructor

This form approved by the Michigan State Board of Dentistry in compliance with Michigan Act No. 198, 1961.

Figure 5:1. Properly Completed Laboratory Work Authorization Order.

PROPERTIES OF DENTURE BASE ACRYLIC RESINS

Denture base acrylic resin materials are available as, 1) heat activated, and 2) chemically activated acrylic resins. Two types of reactions take place during the processing of the powder-liquid type of dental resins. The first reaction is physical in nature. A liquid monomer is imbibed into polymer powder and is characterized by some solution of the polymer into the monomer and by wetting of the polymer by the monomer. You may follow the course of this physical reaction by observing the changes in consistency of the polymer-monomer mixture. Four distinct stages of consistency can be recognized: 1) sandy, 2) sticky, 3) doughy, and 4) stiff. No polymerization takes place during these consistency changes in the heat accelerated acrylic resins. The second or polymerization reaction is initiated by free radicals produced by the decomposition of a peroxide catalyst.

Heat is used to accelerate the decomposition of the peroxide when a heat-activated resin is used. Chemicals are used to speed up the peroxide decomposition in the case of chemically activated acrylic resins. In either case, the reaction is accompanied by the liberation of heat. During polymerization, the heat activated acrylic resins reach a higher temperature than the chemically activated materials because the heat of polymerization is added to the ambient processing temperature, 74°C. for the heat activated type and room temperature for the chemically activated type. Since the boiling point of the methyl methacrylate monomer is 100°C., temperature in excess of this value must be avoided during processing because porosity will result from vaporization of the monomer.

REFERENCES

1. Boucher, C.O. Swenson's Complete Dentures, 6th Edition. St. Louis: The C.V. Mosby Company, 1970. pp. 377-383.
2. Sharry, J.J. Complete Denture Prosthodontics, 2nd Edition. New York: McGraw-Hill Book Company, Inc., pp. 260-261.
3. Craig, R.G. and Peyton, F.A. Restorative Dental Materials, 5th Edition. St. Louis: C.V. Mosby Co., 1975, pp. 382-420.
4. Skinner, E.W. and Phillips, R.W. The Science of Dental Materials, 6th Edition, Philadelphia: W.B. Saunders Co., 1967, pp. 176-213.
5. Boucher, C.O. Swenson's Complete Dentures. St. Louis: C.V. Mosby Co., 1967, pp. 472-481.

OBJECTIVES

Knowledge. Upon completion of this Procedure, you will be able to:

1. Name, for the maxillary and mandibular complete dentures:
 - a. In sequential order, the steps in waxing.
 - b. The precautions needed to avoid potential difficulties, and the consequences of errors.
 - c. The criteria of clinically acceptable products.
2. Identify criteria not met.
3. State the reason for obtaining an occlusal index.
4. Describe the method of making an occlusal index.

Skill. Upon completion of this unit, you will be able to:

1. Wax the maxillary and mandibular complete dentures.
2. Make an occlusal index for the maxillary complete denture.

VIDEOTAPE

1. Waxing the Complete Denture.

MATERIALS NEEDED FOR PROCEDURE #12

1. Bunsen burner.
2. #7 spatula (a second spatula may be helpful in this Procedure, one for applying heated wax, and a second cold spatula for carving the wax).
3. Pink baseplate wax.
4. Alcohol torch.
5. Cotton or gauze.
6. Alcohol (methenol).
7. Small plastic cup.

STEPS FOR WAXING THE COMPLETE DENTURESGeneral.

1. Remove all excess wax from the teeth and smooth the rough wax on the base areas.
2. Seal the baseplate to the master cast! Wax should end at the landing (boxing) edge.

Maxillary Denture.

1. Allow the heated baseplate wax to flow over the labial flange areas from cuspid to cuspid using the #7 spatula.
2. Continue to apply wax up onto the neck or collar portion of the teeth. In your wax applications, follow the outline of the free gingival margin.
3. Supporting bone and mucosa contours are required in the waxed trial dentures. Therefore, continue wax applications in the root support area in order to provide a bulk of wax for carving the simulated contours of these supporting tissues.
4. Carry wax to the distal of the second molars (Figure 5:2).

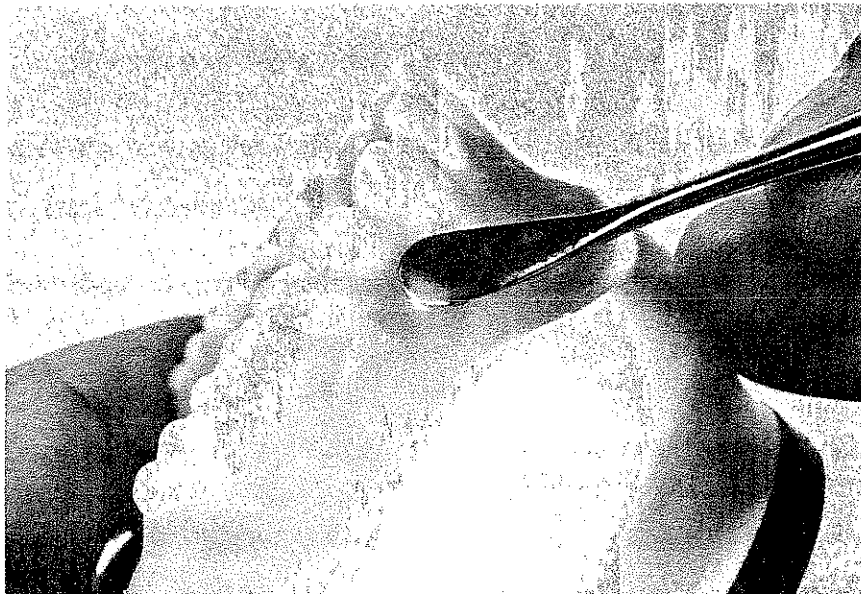

Figure 5:2. Apply Wax up Onto the Necks or Collar Portions of the Teeth Creating the Contours of Supporting Bone and Mucosa.

5. Return now to carving the wax supporting the six maxillary anterior teeth. Because it is now cool, the wax is much easier to carve.
6. Make initial gingival contours around the necks of teeth with the sharp end of the #7 spatula (Figure 5:3).
 - a. Modify wax contours around the necks of the teeth. The contours should be slightly exaggerated to allow for some loss during polishing.
 - b. Fill the interproximal areas with wax to the height of the contact points, this forms the papillae.
 - c. Make a gingival "roll" at each anterior tooth.

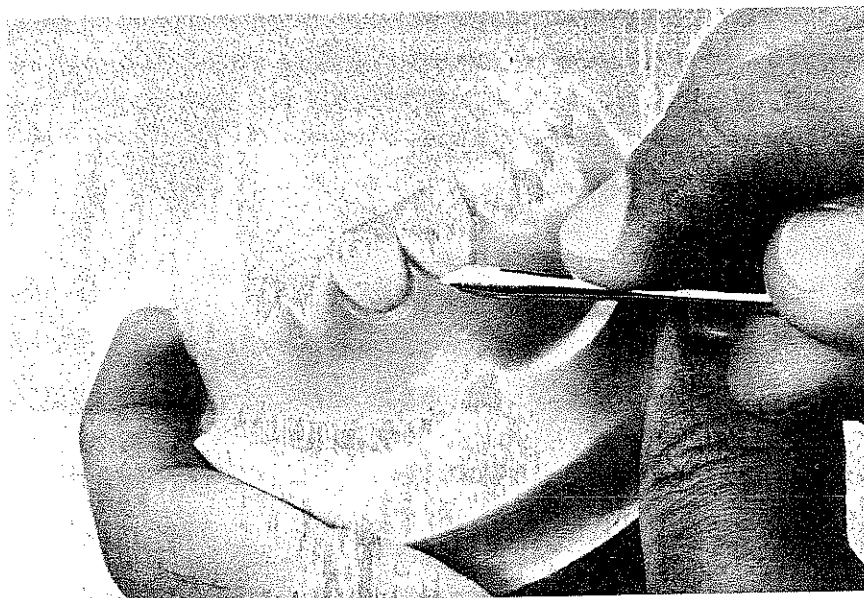


Figure 5:3. Carve the Gingival Contours Around the Necks of the Teeth Using the #7 Spatula.

7. Next carve the gingival contours around the necks of the posterior teeth. Fill the interproximal areas with wax to the height of the contact points.

8. Do not make root forms over the anterior or posterior teeth. Instead, develop a distinct gingival roll around each tooth. Make a concavity from the first bicuspid area to the second molar using the large end of the #7 spatula. Situate the concavity between the "roll" and the periphery of the flange (Figure 5:4).

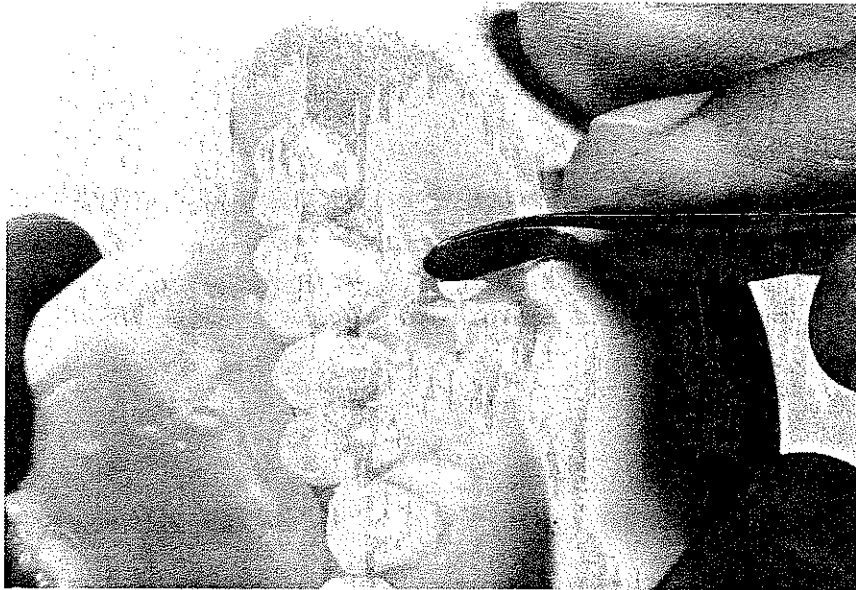


Figure 5:4. Make a Concavity from the First Bicuspid Area to the Second Molar using the Large End of the #7 Spatula.

9. Increase the wax thickness at the periphery to produce a definite border "roll".

Palate.

1. The palatal thickness of a denture must not exceed the thickness of the baseplate plus the stabilization material.

2. The lingual areas of the teeth are sealed to the baseplate so that no rough portions of the teeth project through the wax.
3. The wax must extend onto the lingual surface of the teeth and end in a distinct finish line (Figure 5:5).

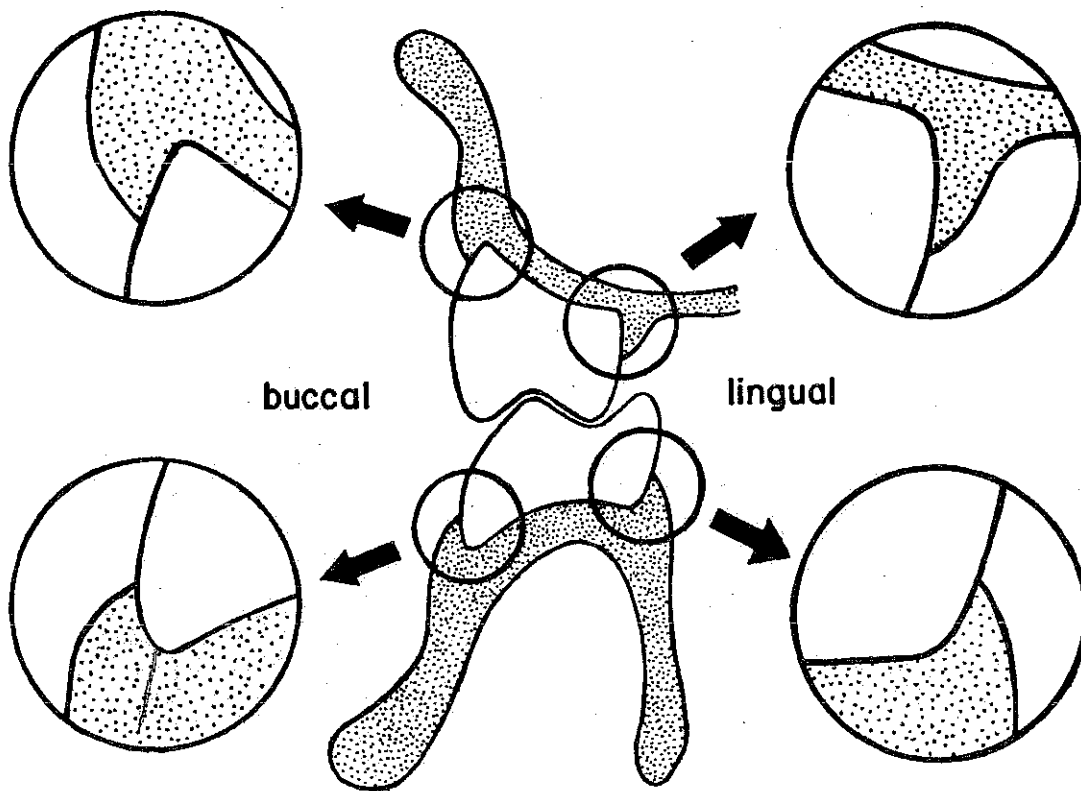


Figure 5:5. Finish Lines on the Palatal and Mandibular Lingual Surfaces of the Teeth are Created.

Mandibular Denture.

1. Follow the same general rules outlined for the maxillary denture.
2. Make sure that the wax around the heels does not interfere with eccentric movements of the articulated dentures.
3. The lingual flange does not have the same degree of concavity as the buccal flange and requires some thickness. Wax should be placed in this area from the finish line on the tooth to the peripheral roll. The thickness of the flange must be the baseplate plus one thickness of pink baseplate wax.
4. Wax must extend onto the lingual surface of the teeth and end in a distinct finish line (Figure 5:6).

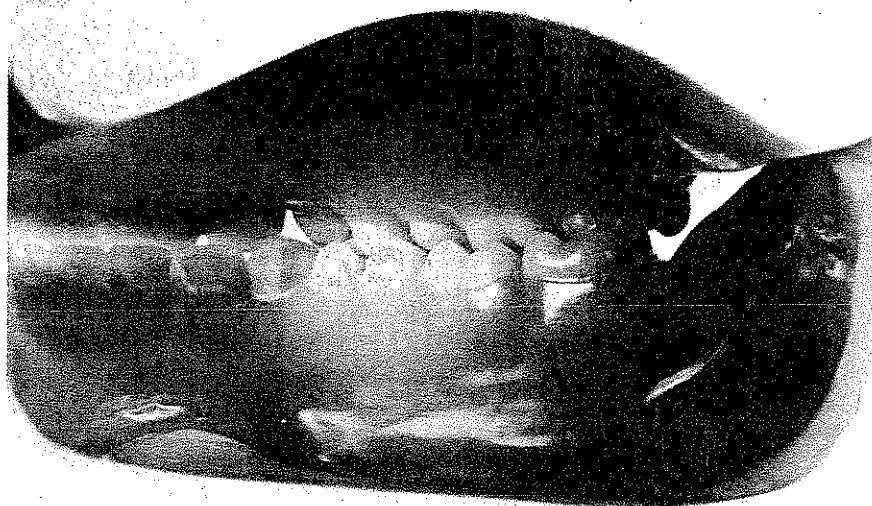


Figure 5:6. Wax Must Extend from the Lingual Finish Line of the Tooth to the Sulcus Depth. Thickness and Contour is Extremely Important so that the Lingual Flange will not be too Thin.

Finishing and Polishing.

1. Final smoothing of the wax surface may be accomplished by "brush-flaming" with the alcohol torch. Caution must be observed as this step can easily ruin the contour so carefully made by earlier carving. Do not destroy highlights created in the carved wax by overheating the wax with the torch and having the entire wax surface flow (Figure 5:7).




Figure 5:7. Use Care When "Brush-Flaming" for Final Smoothing of the Wax Surface.

2. Polish the wax surface by rubbing it with cotton or gauze moistened with cold water.
3. After polishing the wax, check the entire tooth-gingival margin for any wax "flash" which may have been created during the flaming procedure, and remove any flash with the sharp end of a #7 spatula and evaluate the waxed dentures using the listed criteria (Figure 5:8).

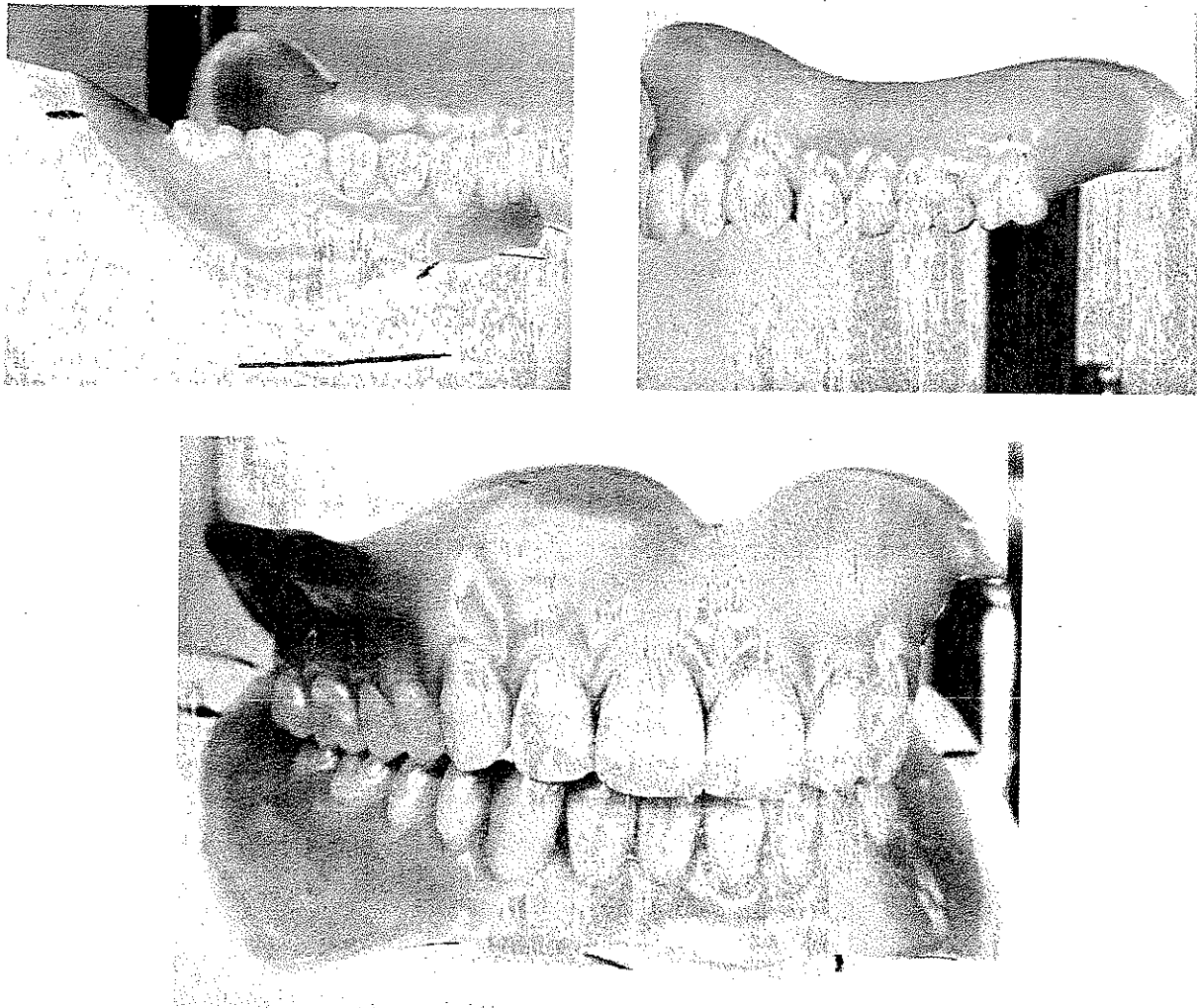


Figure 5:8. Finished Wax Dentures. Be Sure to Remove any Wax "Flash" from the Labial and Buccal Surfaces of the Teeth.

STEPS FOR OBTAINING THE OCCLUSAL INDEX

1. Just before the waxed dentures are sent to the laboratory, remove the mandibular denture from the articulator.
2. Lock the condylar guides in the forward position.
3. Place a new mounting ring on the mandibular portion of the articulator.
4. Remove the bottom from a small plastic drinking cup. Cut only enough material away to allow you to close the articulator when the cup is in position (Figure 5:9).




Figure 5:9. After Preparing the Plastic Cup, form the Impression Plaster Platform and Close the Articulator. Index only the Cusp.

5. Place the cup over the mandibular mounting ring with the bottom side up.
6. Overfill the cup slightly with a mix of impression plaster and build a platform on top of the plastic cup.

7. Close the articulator with the maxillary master cast and denture in place until the incisal pin touches the incisal guide table.
8. Just the cusp tips of the denture teeth should be indexed into the impression plaster. Do not allow the entire tooth to be embedded into the plaster or they will be separated from your wax-up and remain in the hardened impression plaster.
9. Let the plaster harden and separate the denture from the index.
10. Clean the index and check that the denture fits into the index accurately and record the patient's name and the articulator setting. Store the occlusal index for future use (Figure 5:10).



Figure 5:10. The Prepared Occlusal Index with the Appropriate Information Recorded is Stored for Future Use.

CRITERIA - WAXING THE COMPLETE DENTURES
AND OCCLUSAL INDEX

Evaluate your products, using the criteria listed, and check the appropriate boxes. After filling in the boxes, take your products and this Study Guide to an Instructor for evaluation.

	<u>Meets</u> <u>Criteria</u>	<u>Does not</u> <u>meet Criteria</u>	<u>Comments</u>
1. The wax contours around the necks of the teeth are sharp to develop a free gingival margin.			
Maxillary	<input type="checkbox"/>	<input type="checkbox"/>	
Mandibular	<input type="checkbox"/>	<input type="checkbox"/>	
2. The wax is carved to provide a distinct gingival roll around each tooth.			
Maxillary	<input type="checkbox"/>	<input type="checkbox"/>	
Mandibular	<input type="checkbox"/>	<input type="checkbox"/>	
3. A <u>slight</u> concavity exists between the roll and the periphery of the flange.			
Maxillary	<input type="checkbox"/>	<input type="checkbox"/>	
Mandibular	<input type="checkbox"/>	<input type="checkbox"/>	
4. The wax is smooth.			
Maxillary	<input type="checkbox"/>	<input type="checkbox"/>	
Mandibular	<input type="checkbox"/>	<input type="checkbox"/>	
5. Interproximal areas are filled with wax to form papillae.			
Maxillary	<input type="checkbox"/>	<input type="checkbox"/>	
Mandibular	<input type="checkbox"/>	<input type="checkbox"/>	

	<u>Meets Criteria</u>	<u>Does not meet Criteria</u>	<u>Comments</u>
6. The palate is thin with a minimum of baseplate wax.			
Maxillary	<input type="checkbox"/>	<input type="checkbox"/>	
Mandibular	<input type="checkbox"/>	<input type="checkbox"/>	
7. The baseplate is sealed to the master cast and the wax ends at the landing edge.			
Maxillary	<input type="checkbox"/>	<input type="checkbox"/>	
Mandibular	<input type="checkbox"/>	<input type="checkbox"/>	
8. The lingual flange thickness equals the baseplate plus one thickness of pink baseplate wax.			
Maxillary	<input type="checkbox"/>	<input type="checkbox"/>	
Mandibular	<input type="checkbox"/>	<input type="checkbox"/>	
9. The wax extends onto the lingual surfaces of the teeth and ends in a distinct finish line.			
Maxillary	<input type="checkbox"/>	<input type="checkbox"/>	
Mandibular	<input type="checkbox"/>	<input type="checkbox"/>	
10. During articulation no wax heel interferences are present.			
Maxillary	<input type="checkbox"/>	<input type="checkbox"/>	
Mandibular	<input type="checkbox"/>	<input type="checkbox"/>	

<u>Occlusal Index</u>	<u>Meets Criteria</u>	<u>Does not meet Criteria</u>	<u>Comments</u>
11. The maxillary denture teeth fit accurately into the occlusal index.	<input type="checkbox"/>	<input type="checkbox"/>	
12. The occlusal index can be correctly repositioned on the articulator.	<input type="checkbox"/>	<input type="checkbox"/>	

OBJECTIVES

Knowledge. Upon completion of this Procedure, you will be able to:

1. State, for the flasking and for the boiling-out:
 - a. In sequential order, the steps in performing the procedure.
 - b. The precautions to take at certain procedural steps in order to avoid potential difficulties.

Skill. Although you will not perform these Procedures, you should know how they are done in order to have a full understanding of what you are asking the dental laboratory to do. Furthermore, you should know how to perform these procedures in case a dental laboratory is not available to you.

VIDEOTAPES

1. Complete Denture Processing: Part I - Flasking.
2. Complete Denture Processing: Part II - Boil-Out.


MATERIALS NEEDED FOR PROCEDURE #13

1. Maxillary and Mandibular Hanau Denture Flasks.
2. #7 Spatula.
3. Flask press.
4. Rubber bowl.
5. Kerr laboratory spatula.
6. Liquid soap.
7. Laboratory knife.
8. Laboratory facilities.
9. Impression plaster.
10. Dental stone (yellow).


PREPARATION FOR FLASKING THE TRIAL DENTURES

1. Check to make certain the peripheries of the waxed trial dentures are sealed to the master casts. A good seal will prevent the dental stone used in flasking from getting beneath the waxed dentures and destroying the master casts.

2. Soak the impression plaster mountings and the master casts in water for approximately five minutes; this will assist you in separating the mountings from the master casts.
3. Carefully place the blade of the laboratory knife at the junction of the impression plaster and dental stone (yellow), and tap the knife blade firmly with the handle of the laboratory spatula or a tack hammer. The two stones will separate at this junction. Save the impression plaster mountings, because they will be used in remounting the dentures following processing, to correct the occlusion (Figure 5:11).



A



B

Figure 5:11. A) The Impression Plaster Mountings are Separated from both the Maxillary and Mandibular Master Casts. B) The Mountings are Saved for Future Use Following Processing.

3. Before flasking, become familiar with the various parts and sections of the flasks. The mandibular flask base is deeper in one portion. This depth is necessary to provide support to the heels of the mandibular master cast. Both flasks consist of four parts (Figure 5:12):
 - a. the base,
 - b. a small disc,
 - c. the middle section, and
 - d. the cover.




Figure 5:12. A) The Mandibular and B) the Maxillary Flasks for Investing and Processing the Complete Dentures.

5. Before flasking, check the fit of the master casts in the flasks. Place the master casts with the waxed dentures within the base sections of the maxillary and mandibular flasks. The bases of the master casts must seat fully in the flask bases with clearance between the landing areas and the walls of the flasks (Figure 5:13).




Figure 5:13. The Master Casts are Positioned Within the Maxillary and Mandibular Flask Bases.

6. Now place the middle sections of the flasks in position and check that the denture teeth of the maxillary and mandibular dentures will be below the top edges of these sections of the flasks (Figure 5:14).

If a reduction in the thickness of the base of the master cast should be necessary to create clearance and lower the denture teeth below the top edge of the middle section of the flask, the required grinding would destroy the keyways used to remount the finished dentures to the articulator. Post-processing equilibration would be impossible, and you would have to employ other procedures to create the needed occlusion. This problem would be avoided if the requirements for the master cast base thickness were carefully met in the first place. The requirement is that the base of the master cast must not exceed 1/2 inch in thickness.




Figure 5:14. After Positioning the Middle Sections of the Flasks, the Denture Teeth Must be Below the Top Edges of the Flask Sections.

STEPS IN FLASKING THE MAXILLARY AND MANDIBULAR WAXED TRIAL DENTURES

1. Make sure the small discs are properly positioned in the base sections of the flasks (Figure 5:15).
2. Prepare a creamy mixture of impression plaster. Place the mix in the flask bases. Seat the master casts until the boxing edges are even with the tops of the flask bases. With a wet finger smooth the plaster from the edges of the flasks to the boxing




Figure 5:15. The Small Discs are Positioned in the Base Sections of the Flasks. Note the Difference in the Depth of the A) Mandibular Flask Base as Compared to B) the Maxillary.

edges of the master casts. Leave no undercuts. The heels of the mandibular master cast must be adequately supported with the first pour of impression plaster (Figure 5:16).




Figure 5:16. The Impression Plaster is Smooth from the Edges of the Flasks to the Boxing Edges of the Master Cast. The Heels of the Mandibular Master Cast Must be Supported.

3. After the impression plaster hardens, paint all impression plaster, yellow stone, wax and denture teeth with liquid soap (Figure 5:17).



Figure 5:17. Liquid Soap is Painted Over all the Exposed Surfaces before the Second Pour of Impression Plaster-Dental Stone.

4. Place the middle sections of the flasks on the base sections, and check their fit. Remove any areas of stone that interfere with the union of the two sections of the flasks.
5. Prepare a mixture of 1/2 impression plaster and 1/2 dental stone (yellow). Pour the half and half mixture into the assembled flasks covering the teeth and the other exposed areas. As the stone begins to harden, wipe it from the incisal edges and occlusal surfaces of the teeth (Figure 5:18).

Figure 5:18. The Second Pour is Added to the Maxillary and Mandibular Flasks. The Incisal Edges and Occlusal Surfaces Should be Exposed.

6. It is extremely important to contour the tongue space in the second pour for the mandibular denture. Contouring will facilitate easy separation of the sections following processing without breaking the denture.




Figure 5:19. Again Apply the Liquid Soap to the Hardened Impression Plaster-Dental Stone Surfaces.

7. After the second pour hardens, apply the liquid soap to the hardened impression plaster-dental stone surfaces (Figure 5:19).
8. Prepare a creamy mix of dental stone (yellow) and fill the remaining area of the flasks to slight excess. Seat the flask covers. Do not remove the excess stone that comes out of the escape holes or out of the junction between the top and middle sections of the flasks.
9. Allow the flasks to set 30 minutes and then remove the excess stone.
10. Cleanse both the maxillary and mandibular flasks in preparation for the wax elimination (Figure 5:20).






Figure 5:20. A Creamy Mix of Dental Stone (Yellow) is Used to Fill the Remaining Areas of the Flasks. The Flask Covers are Seated and the Excess Stone is not Removed until the Stone has Set.

STEPS IN ELIMINATING THE WAX AND THE BASEPLATES FROM THE FLASKS
BY BOILING-OUT

The equipment used in the dental laboratory for boiling-out consists of a boiling water bath and a rinsing tank.




Figure 5:21. The Boil-Out Equipment Consists of a Boiling Water Bath (left) and a Rinsing Tank.

1. Place the maxillary and mandibular flasks in boiling water for five to seven minutes (Figure 5:22).
2. Remove the flasks from the water and open them using a twisting motion of the knife blade at the junction of the flask bases and the middle sections of the flasks (Figure 5:22).
3. With the flasks open, remove the large pieces of loose wax and the baseplates and stabilizing materials (Figure 5:23).
4. Wash out the remaining wax with boiling water from the rinsing tank. The stone surfaces are brushed with a detergent and thoroughly rinsed free of all debris (Figure 5:24).





Figure 5:22. The Flasks are Boiled for 5 to 7 Minutes, Removed from the Bath and Opened with a Knife Blade.



Figure 5:23. The Wax and Baseplate Materials are Removed from the Flasks.

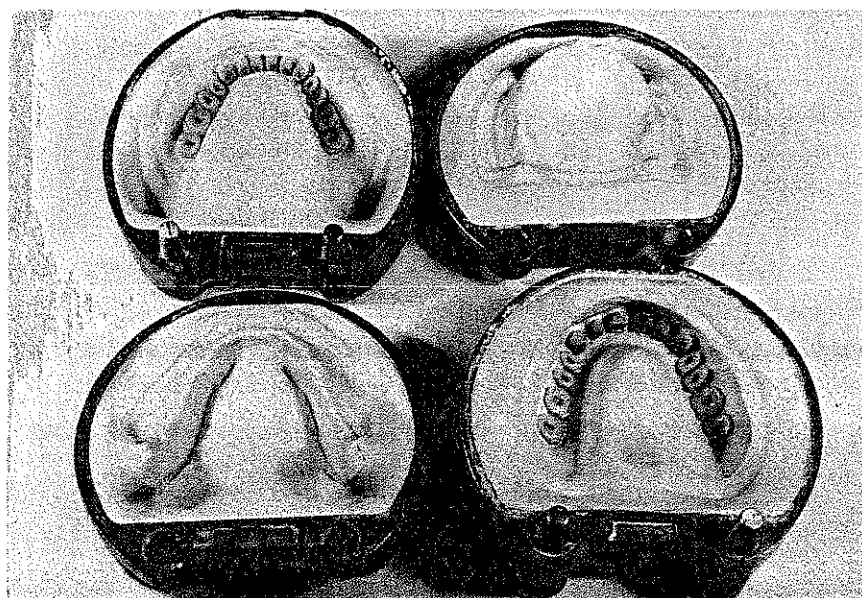



Figure 5:24. The Stone Surfaces are Brushed with a Detergent and Thoroughly Rinsed Free of all Debris in Preparation for Packing the Denture Molds.

STEPS IN PREPARING THE DENTURE MOLDS FOR PROCESSING

1. Dry the stone areas of the flasks with a blast of air and a clean cloth.
2. While the flasks are still warm, apply two coats of a liquid foil substitute to all stone areas of the flasks. Paint carefully around the necks of the teeth and avoid getting the liquid foil substitute on the teeth.
3. Allow the flasks to dry and cool (Figure 5:25).





Figure 5:25. The Liquid Foil Substitute is Painted on all Stone Surfaces for both Halves of the Maxillary and Mandibular Denture Molds.

OBJECTIVES

Knowledge. Upon completion of this Procedure, you will be able to:

1. State for the mixing, packing, processing, and deflasking of mandibular and maxillary complete dentures:
 - a. In sequential order, the steps in performing the procedures.
 - b. The precautions to take at certain procedural steps in order to avoid potential difficulties.

Skill. Although you will not perform these laboratory procedures, you should know how they are done in order to have a full understanding of what you are asking the dental laboratory to do. Furthermore, you should know how to perform these procedures in case a dental laboratory is not available to you.

VIDEOTAPES

1. Complete Denture Processing: Part 3 - Packing the Flask and Curing.
2. Complete Denture Processing: Part 4 - Deflasking.

MATERIALS NEEDED FOR PROCEDURE #14

1. Mixing spatula.
2. Mixing jars.
3. Heat-activated denture base resin (two units).
4. Trial denture invested in processing flask and press.
5. Tinfoil substitute and brush.
6. Cellophane.
7. Rubber bowl.

STEPS IN MIXING HEAT-ACTIVATED ACRYLIC RESIN FOR MANDIBULAR AND MAXILLARY COMPLETE DENTURES

1. Pour 1 unit of liquid monomer into the mixing jar and add 1 unit of powder polymer.
2. Cover the jar and allow it to stand a few minutes before mixing with a spatula (Figure 5:26).




Figure 5:26. Place the Liquid Monomer in the Mixing Jar and Slowly Add the Polymer Powder.

- 3.5 Mix the liquid and powder with the mixing spatula and make certain that all the powder particles are wetted. Close the jar and reopen it only long enough to occasionally check the consistency of the mix (Figure 5:27).

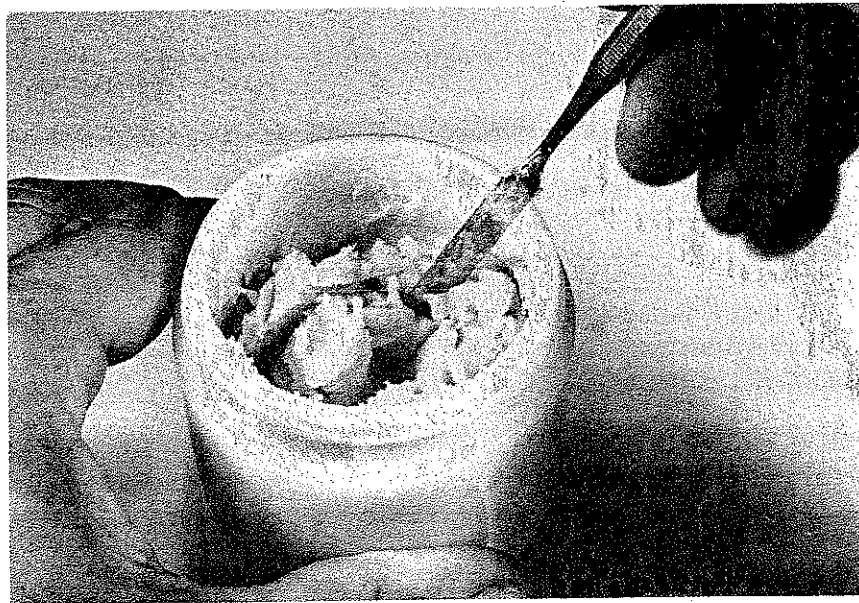


Figure 5:27. The Powder and Liquid are Mixed Wetting all Powder Particles.

4. Packing of the polymer-monomer mixture is easiest when it is in the doughy stage. This stage is reached when the resin mass ceases to adhere to the sides of the mixing jar and when it breaks with a snap as it is quickly pulled apart (approximately 10 minutes following the start of the mix).

STEPS IN PACKING THE MANDIBULAR AND MAXILLARY FLASKS

1. When the doughy stage has been reached, place the mix into half of the molds, cover with a separating sheet (water-wet cellophane) and place the halves of the flasks in position. Apply pressure to the flasks so that excess resin is squeezed out (Figures 5:28 and 5:29).

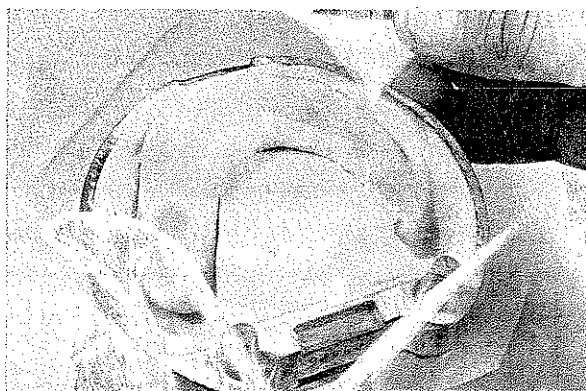
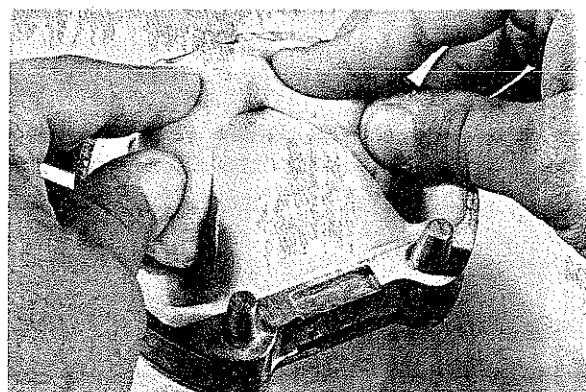
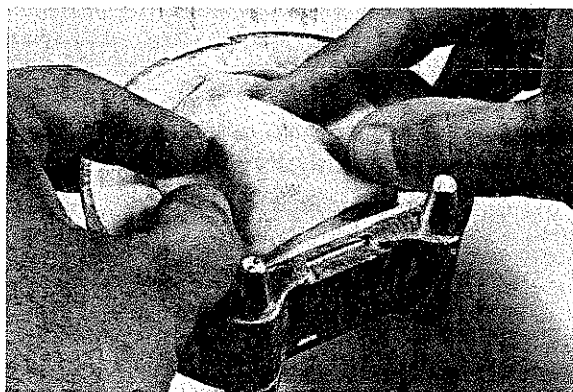


Figure 5:28. The Acrylic Resin is Placed in the Molds When it Reaches the Doughy Stage and Covered with a Cellophane Separating Sheet.




Figure 5:29. The Flask Halves are Closed and the Flask is Placed in the Press Where Pressure is Applied and the Mold Packed.

2. Remove the flasks from the press, open them, remove the cellophane separating sheet, and trim away the excess acrylic resin that appears at the landing edges of the master cast.
3. Continue this packing procedure several times, or until there is little or no flash (excess acrylic resin). Each time, protect the surface of the acrylic resin with a sheet of wet cellophane (Figure 5:30).

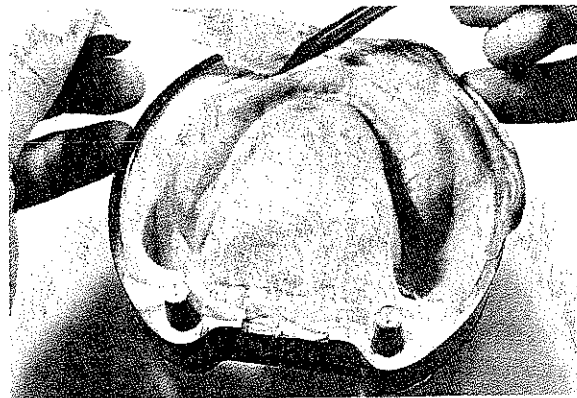
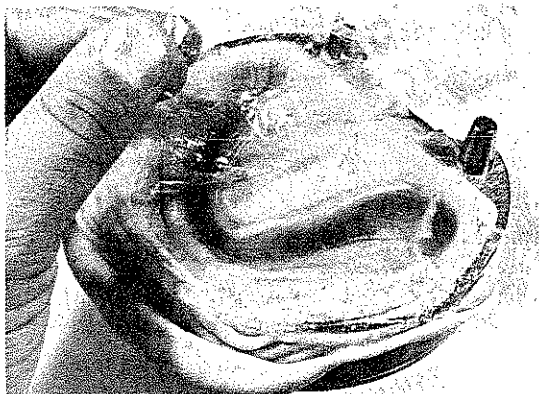


Figure 5:30. The Flask is Opened, the Cellophane Removed and the Excess Acrylic Resin Trimmed. The Packing is Continued until Little or No Acrylic Resin Flash Appears at the Landing Edges.

4. When the molds are fully packed, paint the exposed stone areas again with the liquid foil substitute. Close the flasks for the final press and slowly apply pressure until complete closure is attained. Note: DO NOT place the separating sheets (cellophane) within the flasks at final closure (Figure 5:31).




Figure 5:31. All the Stone Areas of both Halves of Both the Maxillary and Mandibular Molds are Repainted with the Liquid Foil Substitute. Cellophane is not Placed in the Final Closure of the Molds.

CURING THE ACRYLIC RESIN

The acrylic resin is polymerized by heating the material under pressure in flasks.

There are several acceptable methods of curing. The method used in this school is to place both flasks in a curing press. The press and flasks are then placed in the curing bath for 8 to 12 hours at 165°F. (Figure 5:32). A shorter curing method is to place the press and flasks in the curing bath for 1 1/2 hours at 165°F. and then boil the water for 30 minutes. This second method is more likely to cause porosity in the acrylic resin, and is generally not used at this school.

When porosity is found in the denture bases following deflasking, the correction of this problem is both a costly and time consuming procedure. New impressions will need to be made, maxillomandibular jaw records registered and transferred and the dentures reprocessed. In short, the many clinical and laboratory procedures involved in complete denture construction will need to be repeated. The importance of this laboratory step and the required attention to detail cannot be overemphasized.




Figure 5:32. The Flasks are Placed in the Curing Press and Immersed in the Curing Bath. The Acrylic Resin is Processed at 165°F. for 8-12 Hours.

STEPS IN DEFLASKING

1. Remove the curing press from the curing bath and place it on the laboratory bench. Leave the flasks in the press and allow them to cool on the bench for one hour before deflasking.
2. After the flasks have cooled, remove them from the curing press and gently tap the small discs in the bases of each flask. This will separate the base section of the flasks from the molds (Figure 5:33).



Figure 5:33. Gently Tapping with the Hammer will Separate the Flask Bases from the Molds.

3. The flask covers can now be separated from the mold using the knife blade (Figure 5:34).
4. The molds can now be separated from the middle sections of the flasks by again gently tapping with the hammer (Figure 5:34).

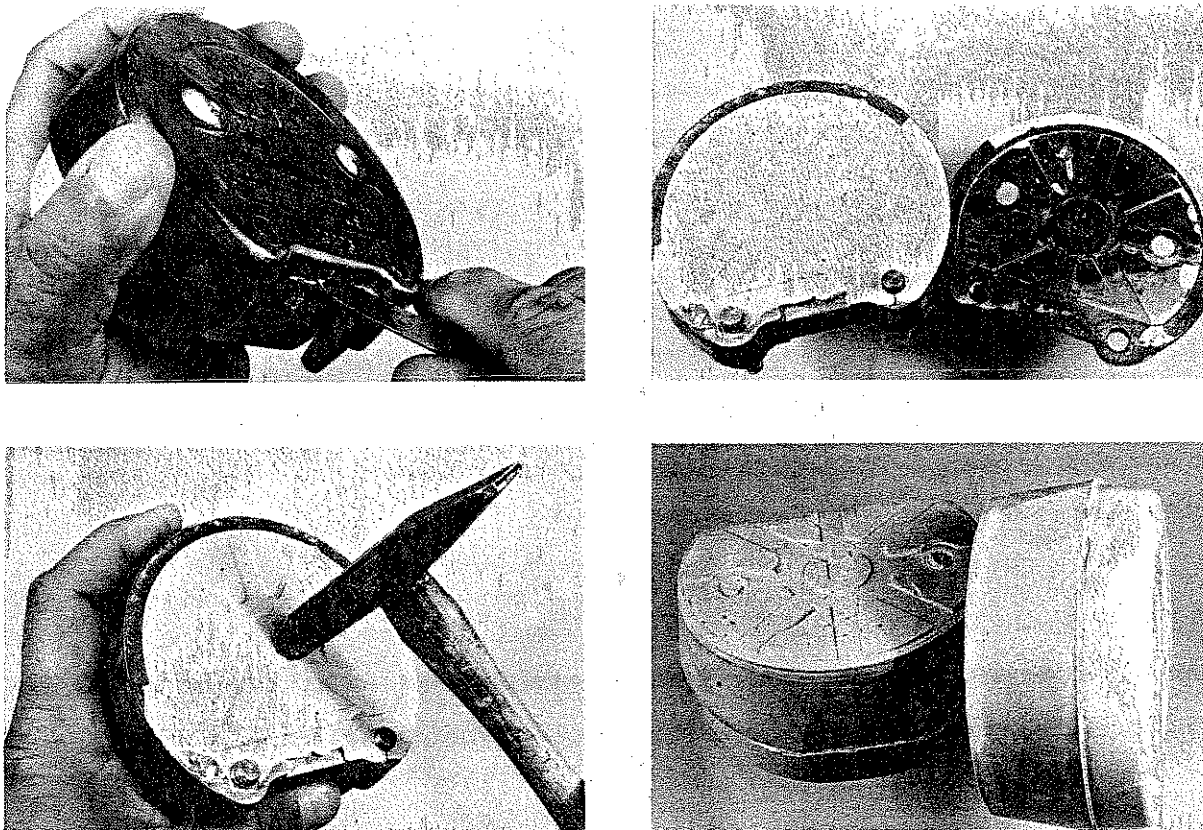


Figure 5:34. The Molds are Carefully Separated from the Flasks.

5. If you gently tap in the junction of the second and third pours of stone, the layers will usually separate. You can also remove the plaster around the master cast by carefully tapping (Figure 5:35).
6. Break away the labial, buccal, and lingual sections of the investment stone from the processed denture. Do this very carefully so that the denture base and the supplied artificial teeth are not damaged (Figure 5:35).




Figure 5:35. The Mold is Separated Between the Second and Third Pours by Gently Tapping with the Hammer. The Impression Plaster is Removed as well as the Second Pour Around the Denture Teeth.

7. What remains are the processed dentures attached to the master casts. The processed dentures must not be removed from the master casts.
8. The master casts with processed dentures are now ready to be remounted on the articulator with impression plaster in preparation for correction of the occlusion (Figure 5:36).

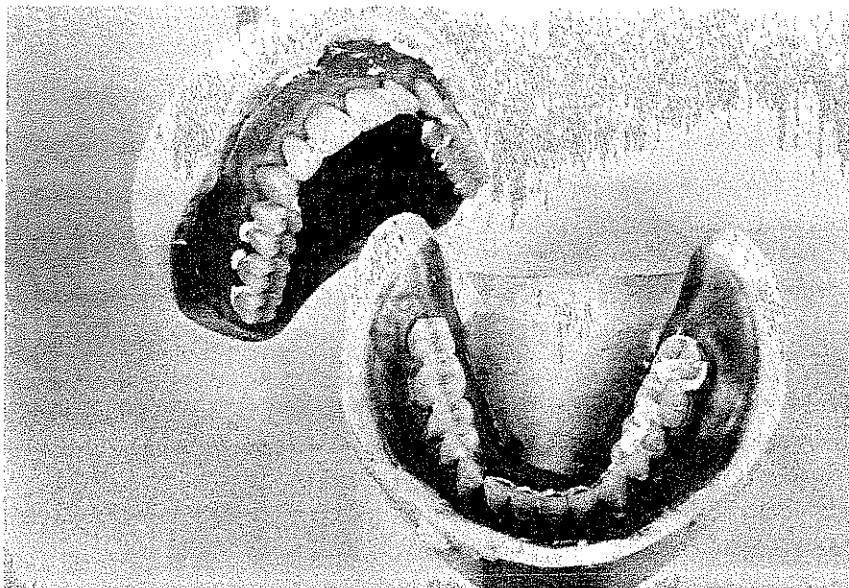


Figure 5:36. The Processed Denture Deflasked Ready for Mounting and Correction of the Occlusion.

SELF TEST 5
WAX THE COMPLETE DENTURE,
OCCLUSAL INDEX, FLASKING, MIX AND PACK

(Circle correct response(s) or write brief answers. For correct answers, consult the Answer Key.)

- T F 1. It is always wise to wax the denture a little thick so that you can contour the denture with acrylic burs after processing.
2. The mistake(s) shown in the waxed-up denture in Figure T5:1 is (are):
- a. Wax covering too much of the mandibular posterior teeth.
 - b. Maxillary gingival rolls are too heavy.
 - c. Interproximal areas are not filled well enough.
 - d. Mandibular gingival rolls are too heavy.
 - e. Maxillary buccal flange is undercontoured.

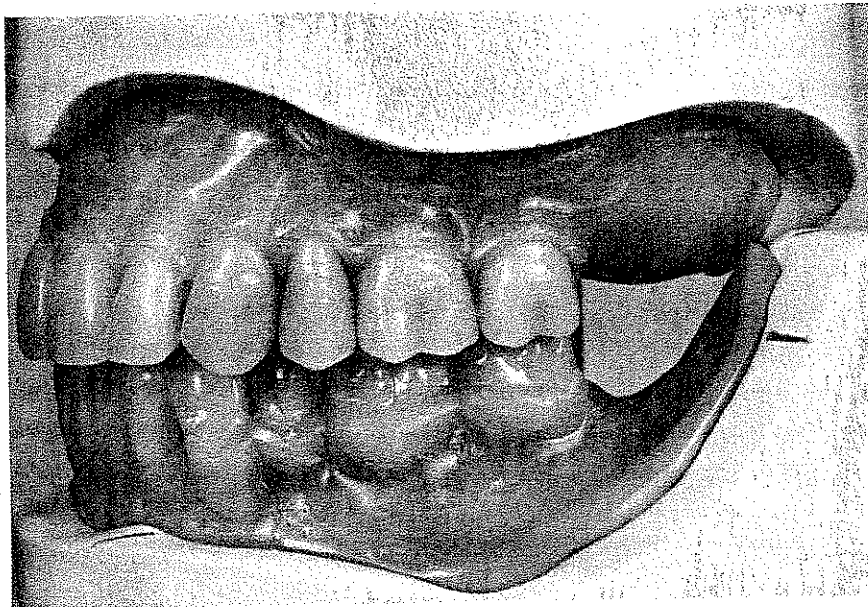


Figure T5:1

3. When waxing the complete denture, the thickness of the plate should be:
 - a. The baseplate plus the stabilizing material.
 - b. The baseplate plus the stabilizing material and one sheet of pink wax.
 - c. The baseplate plus the stabilizing material and two sheets of pink wax.
 - d. The baseplate plus four sheets of pink wax.

- T F 4. Dental stone is used in making the occlusal index because of its strength.

5. The mistake(s) made in making the occlusal index shown in Figure T5:2 is (are):
 - a. Too much of the buccal and lingual surfaces of the supplied teeth were registered.
 - b. The vault segment of the index is too high.
 - c. The index registers too many teeth.
 - d. Not enough of the occlusal anatomy was registered.

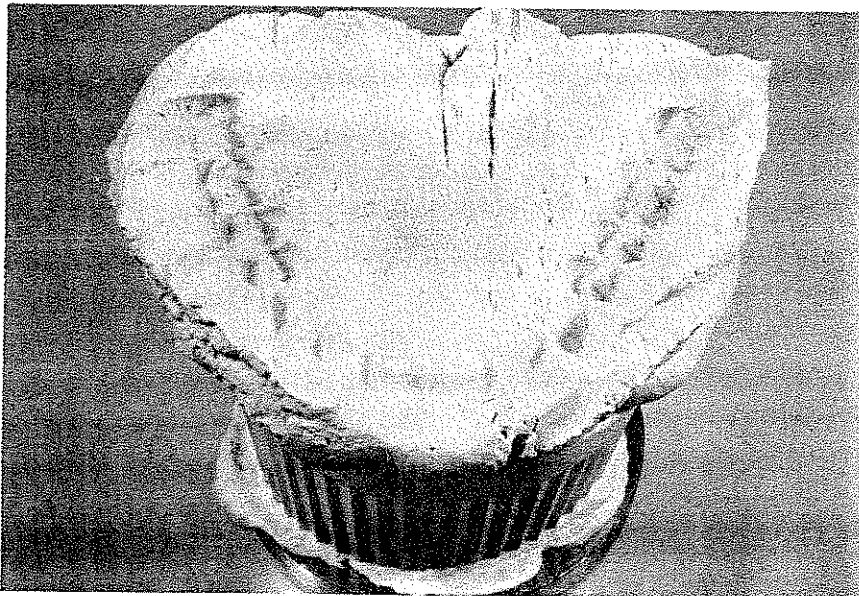


Figure T5:2

6. The four stages of consistency which can be observed when mixing the heat activated acrylic resin are:
- a. _____.
 - b. _____.
 - c. _____.
 - d. _____.
7. To cure heat activated acrylic resin it can be:
- a. Cured in water bath for 8-12 hours at 165°F.
 - b. Cured in water bath 1 1/2 hours at 165°F. and then boiled 30 minutes.
 - c. Cured under heat lamps at 165°F. for 8 hours.
 - d. Bench cured for 24 hours.
- T F 8. Complete dentures are only constructed with heat activated acrylic resins.
9. The separating medium used between the layers of stone and plaster when flasking the complete denture is:
- a. Tin foil.
 - b. Liquid soap.
 - c. Cellophane.
 - d. Varnish.
- T F 10. Excessive heat during the curing of heat activated acrylic resin may result in porosity of the denture base.

COMPUTER-GENERATED SECTION TEST 5

You are now ready to take Computer-Generated Section Test 5, which will cover:

1. Waxing the Complete Dentures.
2. Making the Occlusal Index.
3. Flasking the Complete Dentures.
4. Mixing Acrylic Resin.
5. Packing the Complete Dentures.

When you have completed the laboratory procedures which this Section Test covers and are ready to take this test, go to the Caident Center. All Section Tests are on the computer. The proctor in the Caident Center will instruct you on how to take the test. As you take the test, the computer will inform you of your incorrect answers and tell you the correct answer. As soon as you have completed the test, the computer will display your score. Call the proctor to record your score on the Clinic Progress Card.

There are 8 items in this test. The criterion level (the required correct score) is 75%.

CORRECTING THE OCCLUSION AFTER
PROCESSING, FINISHING, AND POLISHING
THE DENTURES AND DELIVERING THE COMPLETE DENTURES

SECTION

6

OBJECTIVES

Knowledge. Upon completion of this Section, you will be able to:

1. Name the two methods commonly used to correct occlusion after processing and the advantage or disadvantage of each.
2. State the two ways by which the cast may be mounted for the correction of occlusion.
3. Describe the method of selective grinding to correct the occlusion after processing.
4. State the criteria for the corrected occlusion.
5. State the steps in finishing and polishing complete dentures.
6. Describe the delivery appointment sequence and the necessary steps to evaluate the complete dentures and the occlusion.
7. Relate the areas of instruction necessary for patients following the delivery of complete dentures.

Skills. The student will develop the skills necessary to complete Procedures 15 and 16. Although you will not perform Procedure 17 in this Preclinical course, you should understand how it is done in order to be better prepared for your clinical experiences.

DIMENSIONAL CHANGES IN ACRYLIC RESIN DENTURES

During the process of converting the wax trial dentures to acrylic resin, certain dimensional changes occur. These changes result from the dimensional instability of the acrylic resin during and following polymerization and from the very mechanics of the pressure packing technic, the technic used to densely compress the still soft, unpolymerized, acrylic resin into the mold of the denture. Pressure packing, even using very high pressure to approximate the two halves of the denture flask containing the mold, is not adequate to completely and intimately approximate the two flask halves. This lack of approximation of the two mold halves is evidenced by the "flash" of

acrylic resin found on the unfinished denture. The thickness of this flask is related to the increased superior-inferior dimension of the denture.

Two important considerations are apparent from this dimensional change. First, the tissue surface configurations of dentures are dimensionally different from the tissue surface configurations of the impressions from which they were made. Hence, the dentures will no longer fit the patient in the same way the impressions once did. Second, because of the dimensional changes which occur during polymerization and processing, the maxillary and mandibular teeth will not contact each other in the identical points they once did, i.e. during the waxed trial denture stage.

Evidence of dimensional alteration may be noted when the processed dentures are still on the master casts. Lack of intimate contact between the denture base and the cast can often be seen along the peripheries of the dentures, especially at the posterior border of the maxillary denture. Because the maxillary and mandibular dentures have different configurations, contractions occur in different directions. Shrinkage of the acrylic resin toward the center of its mass changes the position of the teeth. The unpleasant result is that the teeth, contacting in a cusp to fossa relationship at the waxed trial denture stage, now contact each other on inclines.

Thus, the changes in the dimensions of the final dentures from those of the wax trial dentures are complex, being a composite of alterations resulting from the chemical polymerization process and from the laboratory technic employed. These dimensional changes must be minimized before the dentures may finally be delivered to the patient.

CORRECTION AND REFINEMENT OF OCCLUSION AFTER PROCESSING DENTURES

Changes in the occlusion that occur during processing must be corrected prior to delivery of the dentures to the patient. REMountING for correction of the occlusion may be accomplished following the processing procedure:

1. By remounting the dentures back on the articulator while they are still on the master casts and doing the split-cast remount.

OR

2. By removing the dentures from the master casts and after finishing and polishing the dentures performing a patient remount.

LIMITATIONS OF THE SPLIT-CAST REMOUNT TECHNIC AS THE ONLY METHOD OF CORRECTING THE OCCLUSION

The split-cast remounting technic has certain limitations that must be considered. Perhaps the greatest limitation is that upon removal of the dentures from the master casts after occlusal correction, further dimensional changes within the denture base and ultimately the occlusal relationships will occur. The result is that the dentures will not fit the patient's residual ridges in the same way they fit the stone master cast on which they were made. The occlusal contact relationships must again be refined after insertion intraorally. In light of these further dimensional changes, it is never reasonable to think that dentures, having been perfectly equilibrated by the split-cast remount technic, will have the same occlusal contacts when delivered to the mouth.

During the initial recording of the maxillomandibular relationships, often even the best of stabilized baseplates do not fit the ridges exactly like the final denture will. To use the split-cast remount technic as the only method of occlusal equilibration at the delivery appointment when the maxillomandibular relationships were recorded with somewhat questionable baseplates may be unwise.

While the split-cast remount technic has certain positive benefits, namely to reestablish the vertical dimension of occlusion used in constructing the dentures, it must be emphasized it can never take the place of the patient remount procedure.

PATIENT REMOUNT PROCEDURE

In this procedure for correcting the occlusion, the patient's new dentures are related directly from the mouth using new maxillomandibular relationship records. With this procedure, the occlusion may be equilibrated with a much

the face-bow transfer has been preserved. In the event that an occlusal index is not available, a new face-bow transfer and a new protrusive interocclusal registration must be made to set the articulator guides. This is required since the face-bow transfer with its arbitrary third point of reference (bite-fork perpendicular to the facial plane) is not consistently reproducible. Any variation in this third point of reference would result in a slightly different angular relationship between the fossae (condylar guides) and the occlusal plane. A new protrusive interocclusal record will establish the proper angle between the mechanical fossae and the occlusal plane. The protrusive record will be made after securing a new centric relation record and verifying the mounting of the patient's mandibular denture.

METHODS OF CORRECTING THE OCCLUSION

There are two methods commonly used for CORRECTING THE OCCLUSION following the remount:

1. Gross reduction with an abrasive paste.
2. Selective grinding - the judicious correction of carefully located interfering surfaces.

The Gross Reduction method must not be used because it will result in indiscriminate reduction of all contacting surfaces. This would result in a decrease in the vertical dimension of the dentures. The buccal cusps of the lower and the lingual cusps of the upper posterior teeth are the supporting cusps - that is, the cusps which maintain the vertical dimension. In order to maintain the carefully determined vertical dimension of the dentures, the occlusal interferences must be corrected by carefully determining the specific areas to be ground to attain a mechanically balanced occlusion¹. This is achieved by selective grinding.

According to Swenson,² "...selective grinding permits the desired factors of both tooth forms and occlusion to be retained".

FINISHING AND POLISHING THE DENTURES

The new dentures must be finished and polished before insertion in the patient's mouth.

After the dentures are removed from the master cast, a thin "flash" of acrylic resin may be noted surrounding the entire denture. This and other areas of excessive resin thickness can best be removed using the Carborundum coated arbor band mounted on a laboratory lathe engine. Where the flange peripheries have incorporated the imprint of the boxing edges or landing areas, the excess resin must be reduced, and the flange smoothed throughout. In certain areas, particularly in the region of the lingual frenum, the arbor band may be too large to be effective. In these areas, the acrylic vulcanite bur may be the instrument of choice. Notches which have not been sufficiently formed by the frenula during the impression procedures can be enhanced at this time using a #702 or #558 fissure bur. No areas of sharpness can be left surrounding these notches. Hard to reach areas may be smoothed using a mounted sulci wheel. The entire tissue surface should be scrutinized for positive imperfections which may have resulted from an imperfect master cast. These projections can often be removed using the large end of a #7 wax spatula, or by a rotating instrument. The gingival contours may be enhanced using rotating instruments. The acrylic resin positives of small imperfections that may have occurred during flasking procedures can also be corrected at this time. It cannot be overemphasized that it is much easier to achieve the desired gingival and peripheral configurations from a superior wax-up than by carving the contours from an excess of acrylic resin.

After all positive imperfections are removed and the peripheries and notches are initially finished, polishing of the entire art portion of the denture is initiated. A thin slurry of pumice in water is applied to the acrylic resin by a slowly turning lathe mounted rag wheel. The flanges are also pumiced until no scratches from the arbor band remain. Care must be taken to prevent heat build-up in the denture, with concomitant potential for distortion, by using plenty of the pumice-water slurry and by continually changing the point of application of the polishing wheel to the denture, i.e. not allowing any particular area a prolonged, continuous exposure to the rag wheel. The pumice-water slurry may be carried to the depths of the palatal vault using a felt cone to polish this area and the lingual finish line of the maxillary teeth. A soft Robinson Bristle brush with pumice slurry will be effective interproximally. Care must be taken not to obliterate the gingival

anatomy or to abrade the acrylic resin teeth when these teeth have been used in the dentures by excessive polishing. Time spent in the waxing endeavor will become more than worthwhile during the polishing sequence.

After all scratches have been removed and the pumice rinsed away, the denture is shined to a high luster, using Bendix on a clean rag wheel turning at high speeds. The peripheries should also be shined, but under no circumstances should the tissue surface of the denture be brought in contact with either the pumice or Bendix rag wheel. Once again, it is imperative to keep the denture moving beneath the rag wheel to prevent excessive build-up of heat in the acrylic resin.

The denture may be stippled to break-up any mirror-like qualities the labial or buccal flange may have. An eccentric #8 bur or a #8 bur with 1/2 of its sphere ground away may be used at low speed with a light, delicate touch to achieve this effect. Carefully stippling of the entire labial surface with the exception of the teeth and peripheries may be accomplished. Following stippling, the denture should again be shined with Bendix. No pumice should be used.

A thorough washing and scrubbing with a detergent, e.g. Tide, and a stiff denture brush will serve to rid the denture of debris, including any Bendix which may have remained in the interproximal areas. The new denture will now be ready for the patient's delivery appointment.

DELIVERY OF THE DENTURES

Before the first insertion of the finished dentures, the tissue surfaces of the denture should again be examined for acrylic resin projections that may have been caused by bubbles in the cast or by scarring of the casts with instruments. The denture should then be inserted and tested for stability and observed for overextension and pressure by the use of pressure indicating paste. All observable discrepancies should be corrected. The perfecting of the occlusion is not deferred until the patient has worn the dentures. New maxillomandibular records of the jaw relations must be made before any errors in occlusion can distort the soft tissues. After the remount and correction of the occlusion, the patient is given instructions on the use and care of the dentures and told to return in 24-48 hours for post delivery management.

Complete denture prosthodontic service does not end with the delivery of dentures to the patient. Rather, post delivery adjustments and management should be considered as an integral part of the treatment sequence.³ The post insertion phase of

denture service can be thought of in two separate categories. The first is the adjustment phase that immediately follows delivery. The other concerns management of problems that can occur after the dentures have been worn for a period of six months, a year or even longer.

INSTRUCTIONS TO THE PATIENT

Specific instructions and reading materials should be given to the patient as soon as treatment begins. The delivery appointment should not be used to "spring on the patient all the excuses for the lack of success." Instead the instructions previously presented should be reviewed.

A booklet, "Facts You Should Know About Your Dentures" has been found to be most helpful in this area. You may wish to present your patient with some typewritten material and an example of such material follows:

DENTURE INSTRUCTIONS

When you start to wear your denture, you will have to learn many new things about your mouth, and about eating. Some people may take longer than others to learn these facts and you must have patience.

When you first begin to wear a new denture, it feels like a big mouthful. This foreign bulk produces an increase in saliva, the same as a mouthful of food. This is a natural condition experienced by most patients for the first few days. Simply swallow more often and nature will quickly adapt itself to the new conditions.

Bear this in mind, success in wearing a denture depends more upon yourself than upon any other thing. If you approach the matter with determination, you will be surprised at the short time it will take you to achieve mastery.

The muscles of the cheeks and lips, and also the tongue, help to keep your lower denture in place. These muscles have to become accustomed to the denture.

No harm will be done by trying to eat with your new denture from the start, provided you do not become discouraged by your first failures. The chances are that you will not eat with your usual satisfaction at the beginning. Very few patients do until they become more experienced.

As a denture wearer, you face two important problems. The first of these is comfort because every new denture, no matter how well fitting, will cause some pain and discomfort. The second is confidence, until you have learned to speak, to laugh, and to eat.

To help you get off to the right start, read the following rules for denture wearers. Read these and follow them with care and patience.

1. Learning to wear a denture takes time. Don't listen to friends who tell you how easy it was for them. They are either bragging, or their memories are poor.
2. A full lower denture usually takes a greater time to master than a full upper denture. Be patient, don't worry if your tongue feels strange or restricted.
3. Take longer for a meal.
4. Don't take large bites at first. Cut all foods into small portions.
5. Eat only soft foods for the first few days, then as you progress to more solid foods, chew slowly and evenly so that you grow accustomed to managing your denture, and to the pressure on the gums when you bite.
6. If you have a tendency to slur your words or your speech seems difficult, practice speaking before a mirror.
7. An unclean denture is never a comfortable one. Clean your denture every morning and night with a safe denture cleanser, and brush the denture with the denture brush you were given.
8. Do not wear your dentures continually. Leave them out for some period each day, or even better, if you can, leave them out all night.
9. You will experience some pain and discomfort. When sore spots develop on the gums, visit your dentist for relief.
10. Remember your gum tissues change, your dentures do not. It is important that you visit your dentist regularly for a complete denture checkup.

Dentures can not be worn indefinitely without adjustment, like clothing or eye glasses they must be altered periodically to fit your changing makeup. The changes in this instance are occurring in your mouth and gum tissues.

After the natural teeth are extracted, you must expect continual change or shrinkage of the gums. This will take place to some extent for the rest of your life.

The result is that after some time, the dentures that originally fitted so well will become loose. This is not your dentist's fault, but he can often help you by relining or rebasing your dentures, thereby prolonging their usefulness. Where the change has been extreme, new dentures may be indicated in order to restore and preserve the normal facial appearance.

Above all things, KEEP YOUR DENTURE CLEAN. The brushes and preparations used to clean natural teeth are not always satisfactory for dentures. Some are ineffective, others ruin them.

Never use scouring powders. They may contain caustic alkali, acid or grit. These may dissolve the denture material or roughen the surface so that food particles and stains cling to it. This makes a denture unsanitary and unsightly, and causes it to have an unpleasant odor.

Your denture, if kept absolutely clean, will fit better and feel much more comfortable. Give your denture the same care and attention you would give your natural teeth.

Always hold a denture over water when cleaning it. If you drop it, the water will cushion the fall and prevent breakage.

GOOD LUCK!

1. Sharry, J. Complete Denture Prosthodontics. New York: 2nd Ed., McGraw-Hill Book Company, Inc., 1968. pp. 256-258.
2. C.O. Boucher, Swenson's Complete Dentures. St. Louis: The C.V. Mosby Company, 1970. pp. 246-255.
3. Kingery, R.H.: The Postinsertion Phase of Denture Treatment. Dental Clinics of North America, July, 1960, pp. 343-358.
4. Wright, C.R., Swartz, W.H., and Godwin, W.C. Facts You Should Know About Your Dentures. Published by Health Care, Inc., P.O. Box 94, Waterville, OH 43566, p. 72.

OBJECTIVES

Knowledge. Upon completion of this Procedure, you will be able to:

1. In sequential order, state the steps in performing selective grinding to correct the occlusion after processing.
2. Describe the method of refining the corrected occlusion.
3. Name the two methods commonly used to correct occlusion after processing and the advantage or disadvantage of each.
4. State the two ways by which the cast may be remounted for the correction of occlusion.
5. State the criteria for the corrected occlusion.

Skill. Upon completion of this Procedure, you will be able to:

1. Perform the split-cast remount technic.
2. Perform selective grinding to correct the occlusion of the maxillary and mandibular dentures after processing.
3. Refine the corrected occlusion by milling.

VIDEOTAPES

1. Split-Cast Remount and Equilibration in centric occlusion.
2. Equilibration in Working and Balancing.
3. Equilibration in Protrusive and Milling.

MATERIALS NEEDED FOR PROCEDURE #15

1. Kerr straight handpiece.
2. Kerr electro-torque.
3. Assorted gem stones and vulcanite burs.
4. Inked ribbon.
5. Dental articulating tape.
6. Milling paste.
7. Round diamond straight handpiece bur.

STEPS IN THE SPLIT-CAST REMOUNT OF THE DENTURES

1. Carefully inspect the maxillary and mandibular master casts and remove any particles of impression plaster that may be attached following the deflasking procedures.
2. Also inspect the impression plaster mounting and remove any projections of plaster. Approximate the base of the keyed master casts with the plaster mounting to be certain that they accurately fit together.

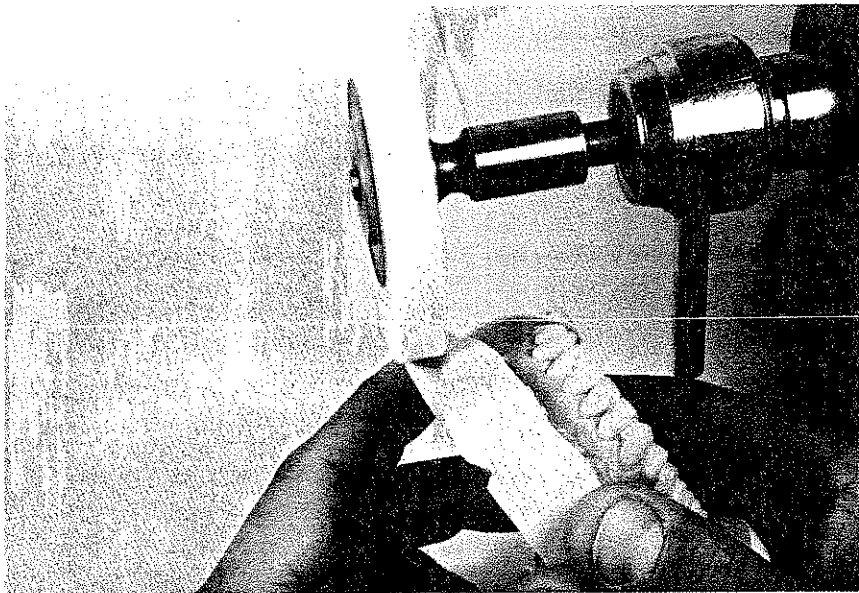


Figure 6:1. Grooves are Cut into the Master Cast Base and the Mounting with the Faskut Stone.

3. With the Faskut stone, cut grooves in the base of the master casts and also the impression plaster mounting (Figure 6:1).
4. Accurately approximate the keyed master cast and its mounting and join them with a thin mix of impression plaster locking the two together by placing the impression plaster over the grooves (Figure 6:2).
5. After the impression plaster has set, place the remounted dentures on the articulator and determine the processing change by the amount the incisal pin is elevated off the incisal guide table (Figure 6:2).

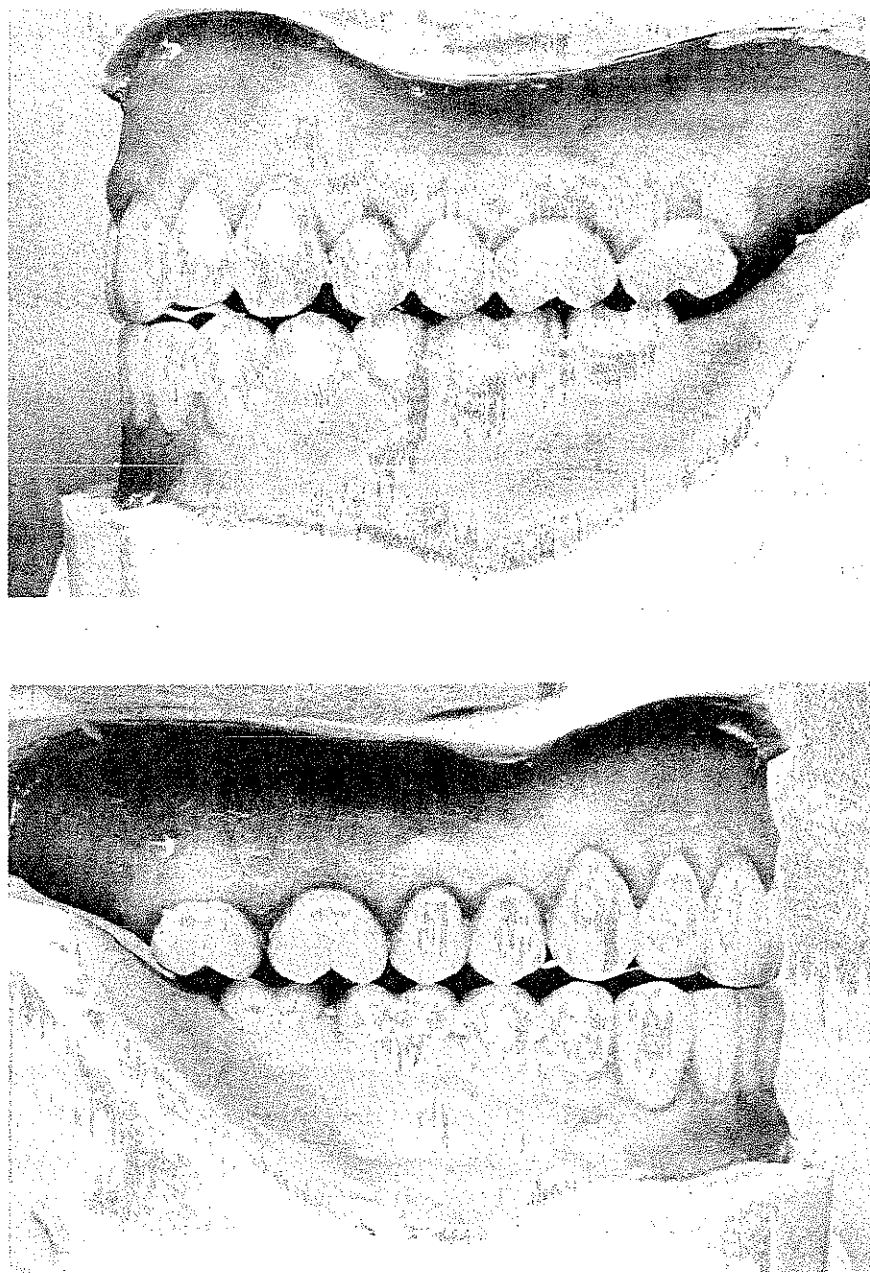


Figure 6:10. Protrusive Occlusion Corrected.

CRITERIA - CORRECTING THE OCCLUSION AFTER PROCESSING

Evaluate your product using the criteria listed. After filling in the sheet, take your product and this Study Guide to an Instructor for evaluation.

	<u>Meets Criteria</u>	<u>Does not meet Criteria</u>	<u>Comments</u>
1. There are no heel interferences at the established occlusal vertical dimension or during excursive movements.	<input type="checkbox"/>	<input type="checkbox"/>	
2. Maximum posterior tooth contacts bilaterally, simultaneously, and antero-posteriorly in centric occlusion.	<input type="checkbox"/>	<input type="checkbox"/>	
3. The anterior teeth are not in contact in centric occlusion.	<input type="checkbox"/>	<input type="checkbox"/>	
4. All contacts occur within movements of 2 mms. of the incisal pin.	<input type="checkbox"/>	<input type="checkbox"/>	
5. The incisal pin remains in contact with the incisal table during movements.	<input type="checkbox"/>	<input type="checkbox"/>	
6. Light contact for the maxillary and mandibular anterior teeth is observed in a protrusive movement.	<input type="checkbox"/>	<input type="checkbox"/>	
7. The occlusion exhibits a maximum degree of balance when the articulator is moved in lateral and protrusive excursions.			
Working	Right	<input type="checkbox"/>	<input type="checkbox"/>
	Left	<input type="checkbox"/>	<input type="checkbox"/>

		<u>Meets</u> <u>Criteria</u>	<u>Does not</u> <u>meet Criteria</u>	<u>Comments</u>
Balancing	Right	<input type="checkbox"/>	<input type="checkbox"/>	
	Left	<input type="checkbox"/>	<input type="checkbox"/>	
Protrusive	Right	<input type="checkbox"/>	<input type="checkbox"/>	
	Left	<input type="checkbox"/>	<input type="checkbox"/>	
8.	Smooth and even working contacts with even balancing contacts on the opposite side.	<input type="checkbox"/>	<input type="checkbox"/>	

OBJECTIVES

Knowledge. Upon completion of this Procedure, you will be able to:

1. State in sequential order the steps in finishing and polishing.
2. State the precautions to take at certain procedural steps in order to avoid difficulties.

Skill. Upon completion of this Procedure, you will be able to:

1. Finish and polish maxillary and mandibular complete dentures.

VIDEOTAPE

1. Finishing and Polishing the Complete Dentures.

MATERIALS NEEDED FOR PROCEDURE #16

1. Kerr straight handpiece and motor.
2. Soft Robinson bristle brush.
3. Selection of acrylic burs (Flame and pear shaped).
4. #558 dentate bur - SSW.
5. A dry 6" rag wheel.
6. A wet 4" rag wheel.
7. Lathe mounted Arbor bands.
8. Bendix polish and pumice.
9. The processed complete dentures as returned from the laboratory.

STEPS IN FINISHING AND POLISHING THE COMPLETE DENTURES

1. Remove the processed dentures from the master casts. Assistance is available in the dental laboratory to remove the stone materials. However, you must allow adequate time for this service.

2. The processed dentures returned from the dental laboratory may have sharp edges of acrylic resin around the entire peripheries. Remove this flash by grinding with the lathe mounted arbor band. This grinding will reestablish the peripheral roll so carefully recorded in the final impressions.

Feel with your finger to judge the smoothness of the denture flanges. Many minor sharp areas are impossible to detect visually (Figure 6:11).

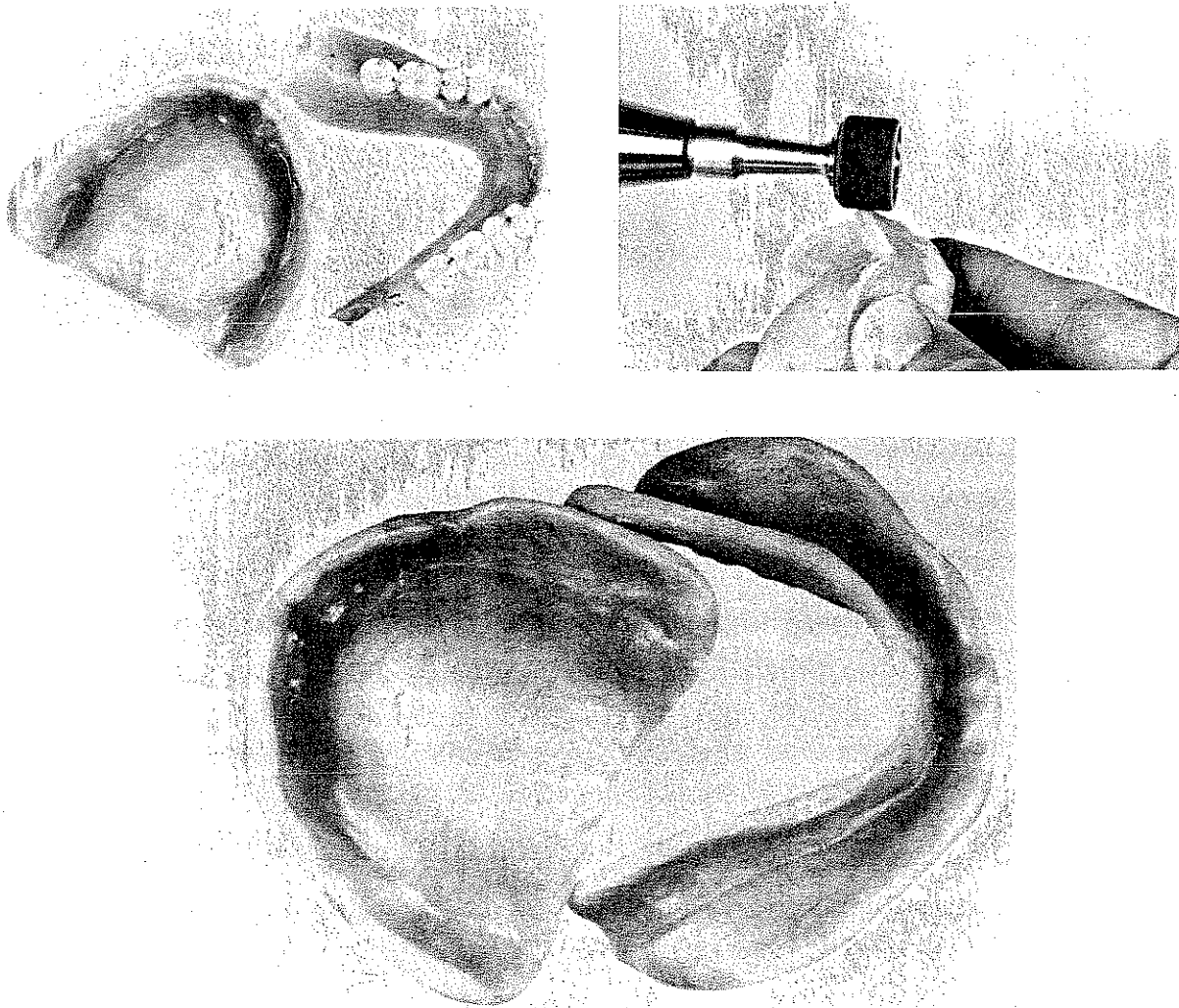


Figure 6:11. The Acrylic Resin "Flash" Around the Entire Periphery of the Dentures Should be Removed by the Lathe Mounted Arbor Band. The Periphery Recorded in the Impression Procedure Should be Rounded and Sharp Edges Should Not Remain.

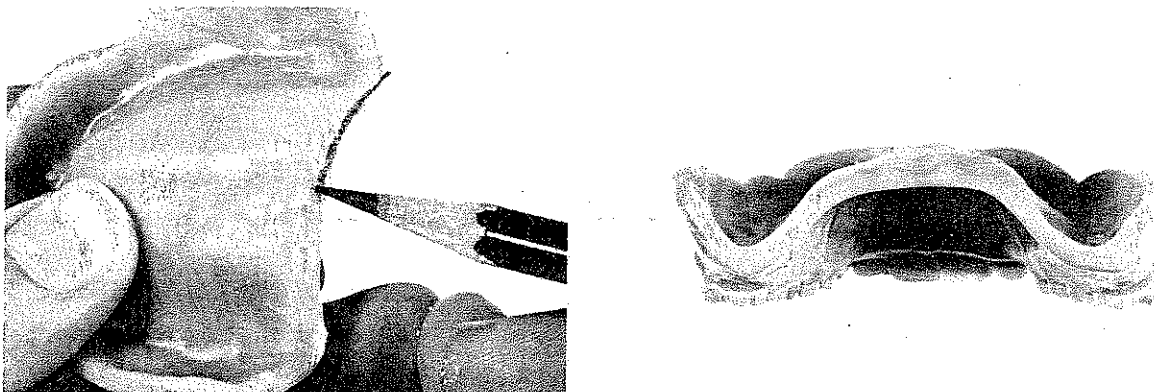


Figure 6:12. Shorten the Posterior Border of the Denture Back to the Length Established in the Impression Procedure. Do not Leave the Imprint of the Landing Area. The Palate Should not be too Thick.

3. Shorten the posterior border of the maxillary denture to the finish line established in the final impression. If the posterior palatal area is thick, thin it to about 1.5 mms. thickness using the arbor band. Do not grind the tissue surface (Figure 6:12).
4. Relieve the labial notch with a #558 dentate bur. The maxillary labial notch must be a straight groove, not a wide "vee". The notch edges are slightly rounded. Also relieve the maxillary buccal notches (Figure 6:13).




Figure 6:13. Relieve the Notches with Fissure Burs.

5. If the mandibular labial and buccal notches are present, relieve them also. For the technic denture, the mandibular labial notch is absent.
6. Use a soft Robinson bristle brush in a straight hand-piece to remove remnants of stone and residual acrylic resin around the teeth. Use extreme care when the denture is constructed with acrylic resin teeth, because the bristle brush can cut and burn the plastic teeth if it is used too vigorously.
7. The art portion of the denture was perfected during the waxing procedure and therefore does not need further definition at this time. However, if modification is needed, it can be accomplished with a selection of acrylic burs. (The importance of a careful wax-up should now be most obvious to you.)
8. Use the large acrylic finishing bur to blend the flange and peripheral areas of the art portion if needed.
9. The lingual notch area of the mandibular denture is often too small for the arbor band. It can best be finished using the acrylic finishing burs.
10. After any deep scratches have been removed with the acrylic burs, use a paste of water and pumice and a 4 inch wet rag wheel to polish the dentures. As you polish the peripheries, turn them continually so as not to polish the acrylic resin to a knife edge. Remember, the pumice does the polishing, not the wheel. Use a tapered felt cone and pumice to polish the maxillary palatal surface.
11. Thoroughly dry and inspect the dentures for any scratches that have not been removed. It is easier to see scratches when the dentures are dry.
12. Use a dry clean rag wheel with a small amount of Bendix polish to shine the acrylic surface. Bendix will not remove scratches. Do not use a rag wheel that has been used for polishing metal because it would leave the acrylic resin surface black.
13. Stippling can be performed if desired. Stippling is a technique that utilizes a #8 round bur that has been ground on one side with a heatless stone to remove several of the bur flutes. A stippled surface will break up light as it reflects from the acrylic resin surface leaving a more natural appearance (Figure 6:14).
14. Wash the finished and polished dentures with soap and water in preparation for the delivery appointment (Figure 6:15).
15. Do not polish the tissue surface of the dentures.
16. Evaluate the dentures to see that the criteria listed have been met.

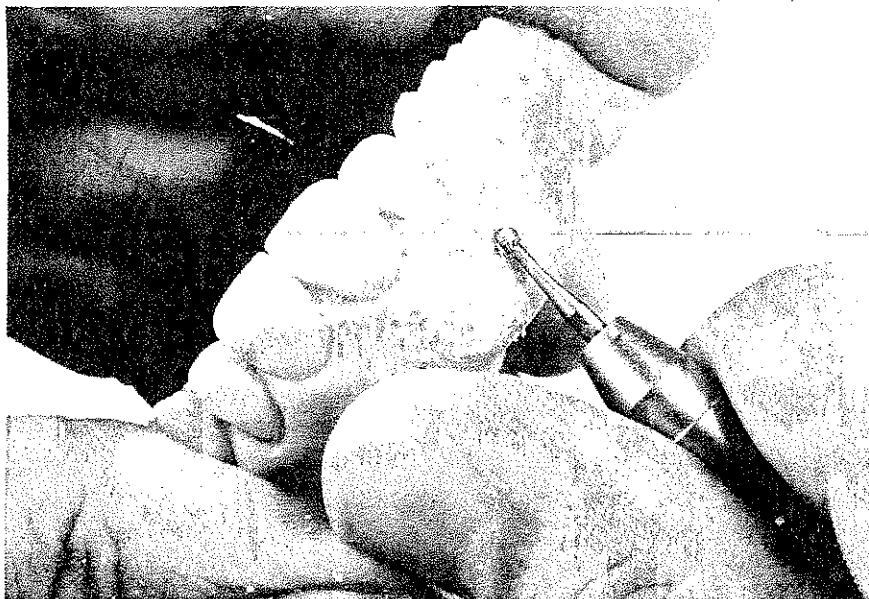


Figure 6:14. The Dentures can be Stippled with a Modified #8 Round Bur.

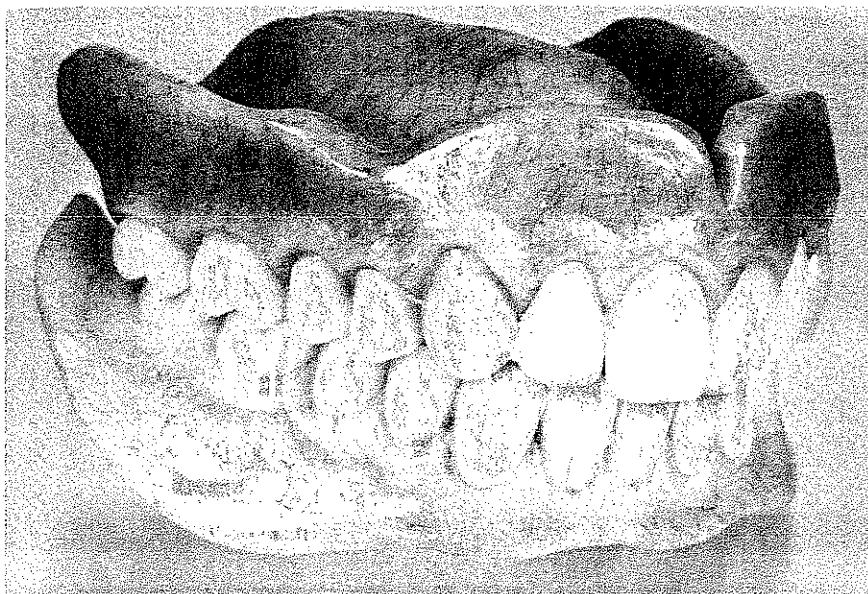


Figure 6:15. The Finished and Polished Dentures.

CRITERIA - FINISHING AND POLISHING THE COMPLETE DENTURES

Evaluate your product using the criteria listed. After filling in the sheet, take your product and this Study Guide to an Instructor for Evaluation.

<u>Maxillary and Mandibular Complete Dentures</u>	<u>Meets Criteria</u>	<u>Does not meet Criteria</u>	<u>Comments</u>
1. The denture flanges are free of scratches and smooth to the eye and touch.			
Maxillary	<input type="checkbox"/>	<input type="checkbox"/>	
Mandibular	<input type="checkbox"/>	<input type="checkbox"/>	
2. The posterior border of the maxillary denture ends at the finish line established in the final impression.			
Maxillary	<input type="checkbox"/>	<input type="checkbox"/>	
Mandibular	<input type="checkbox"/>	<input type="checkbox"/>	
3. The labial and buccal notch are the width of a #558 Bur.			
Maxillary	<input type="checkbox"/>	<input type="checkbox"/>	
Mandibular	<input type="checkbox"/>	<input type="checkbox"/>	
4. There are no remnants of stone around the necks of the teeth.			
Maxillary	<input type="checkbox"/>	<input type="checkbox"/>	
Mandibular	<input type="checkbox"/>	<input type="checkbox"/>	
5. There are no scratches or unfinished areas.			
Maxillary	<input type="checkbox"/>	<input type="checkbox"/>	
Mandibular	<input type="checkbox"/>	<input type="checkbox"/>	

	<u>Meets</u> <u>Criteria</u>	<u>Does not</u> <u>meet Criteria</u>	<u>Comments</u>
6. All areas are clean.			
Maxillary	<input type="checkbox"/>	<input type="checkbox"/>	
Mandibular	<input type="checkbox"/>	<input type="checkbox"/>	
7. No bubbles or sharp edges in the supporting sur- faces of the dentures.	<input type="checkbox"/>	<input type="checkbox"/>	

OBJECTIVES

Knowledge. Upon completion of this Procedure you will be able to:

1. State the steps in delivering the maxillary and mandibular complete dentures.
2. State the steps in performing the patient remount.
3. Discuss the areas of instruction to the patient.

Skill. Although you will not clinically deliver the complete dentures in the Preclinical course, a knowledge of the procedure will help to prepare you for your clinical experiences.

VIDEOTAPES

1. Delivery of Complete Dentures Part 1 - The Use of Pressure Indicating Paste.
2. Delivery of Complete Dentures Part 2 - The Occlusal Equilibration - Stripping Method.
3. Selective Grinding - Patient Remount.

MATERIALS NEEDED FOR PROCEDURE #17

1. The properly finished and polished complete dentures.
2. Kerr straight handpiece and motor.
3. Selection of acrylic burs (flame and pear shaped).
4. #558 dentate bur SSW.
5. Pressure indicating paste and articulating paper.
6. Bunsen burner.
7. Aluwax, indelible pencil.
8. #7 spatula.
9. Impression plaster.
10. Articulator and mounting rings.
11. Occlusal index or face-bow.
12. Rubber bowl and spatula.
13. Sticky wax.

STEPS IN DELIVERING THE COMPLETE DENTURES

1. ALWAYS DELIVER THE MAXILLARY DENTURE FIRST. Carefully seat the maxillary denture and check for sensitive areas.
2. If the denture meets resistance to seating, STOP and begin immediately step #3 using the pressure indicating paste.
3. Dry the denture and place a very thin application of the pressure indicating paste on the entire tissue bearing surface of the maxillary denture.

When using the pressure indicating paste, remove only a small amount of paste with a cotton swab and place the paste on a paper pad. DO NOT contaminate the bulk container. A small amount goes a long way.

4. Again carefully seat the maxillary denture. Remove the denture and inspect for areas of pressure.

Pressure areas are indicated by a "burn-through" of the pressure indicating paste. These areas are relieved slightly with smooth cutting acrylic resin burs.

5. Repeat the placement of pressure indicating paste, seating of the denture, and selected relief until the denture seats fully and contact appears uniform (Figure 6:16).
6. After the pressure areas are adjusted, cleanse the denture of residual pressure indicating paste. An excellent solvent for this purpose is oil of orange.
7. Seat the denture fully; however do not let go until you feel retention. Retention is evaluated by applying moderate pressure with a lateral component to the maxillary cuspid. Be sure to support the opposite tuberosity when applying pressure in case the denture loses its retention.
8. Once the denture is seated and the retention is found to be satisfactory, check the denture peripheries for overextensions by carefully manipulating the tissues much as you did in border molding the maxillary impression tray. The buccal and labial flanges should fill the sulcus as much as possible without impinging on moving tissues. If, as you move the tissues, the maxillary denture is dislodged, the flanges will need to be adjusted. Use the lathe mounted arbor band or the vulcanite bur.

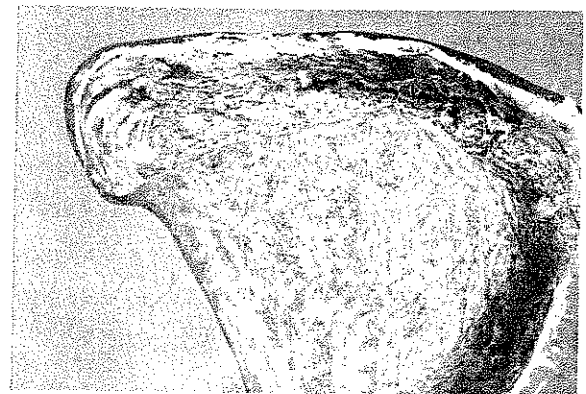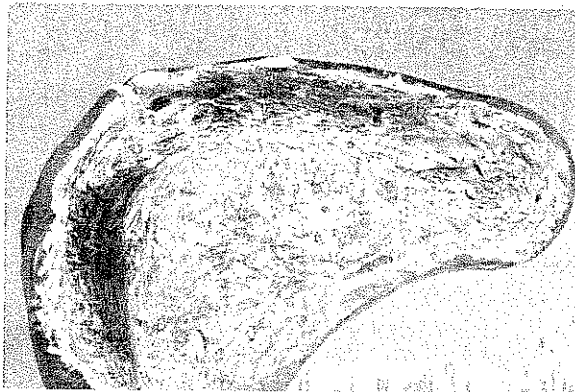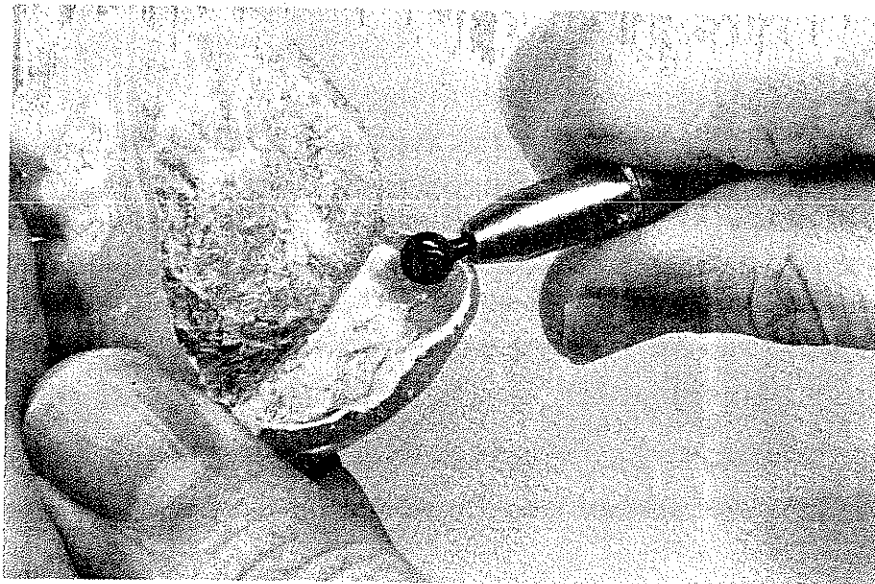
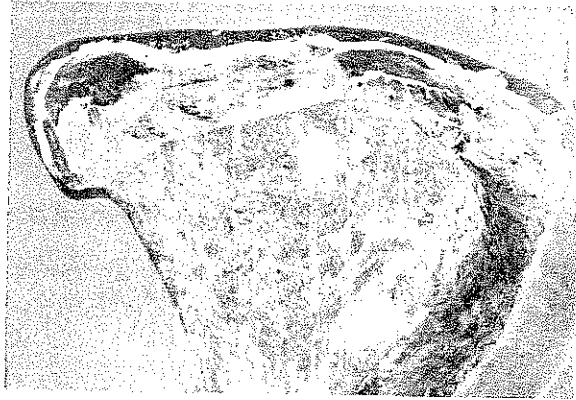


Figure 6:16. Pressure Areas are Relieved Until Uniform Contact of the Maxillary Denture Base is Achieved.

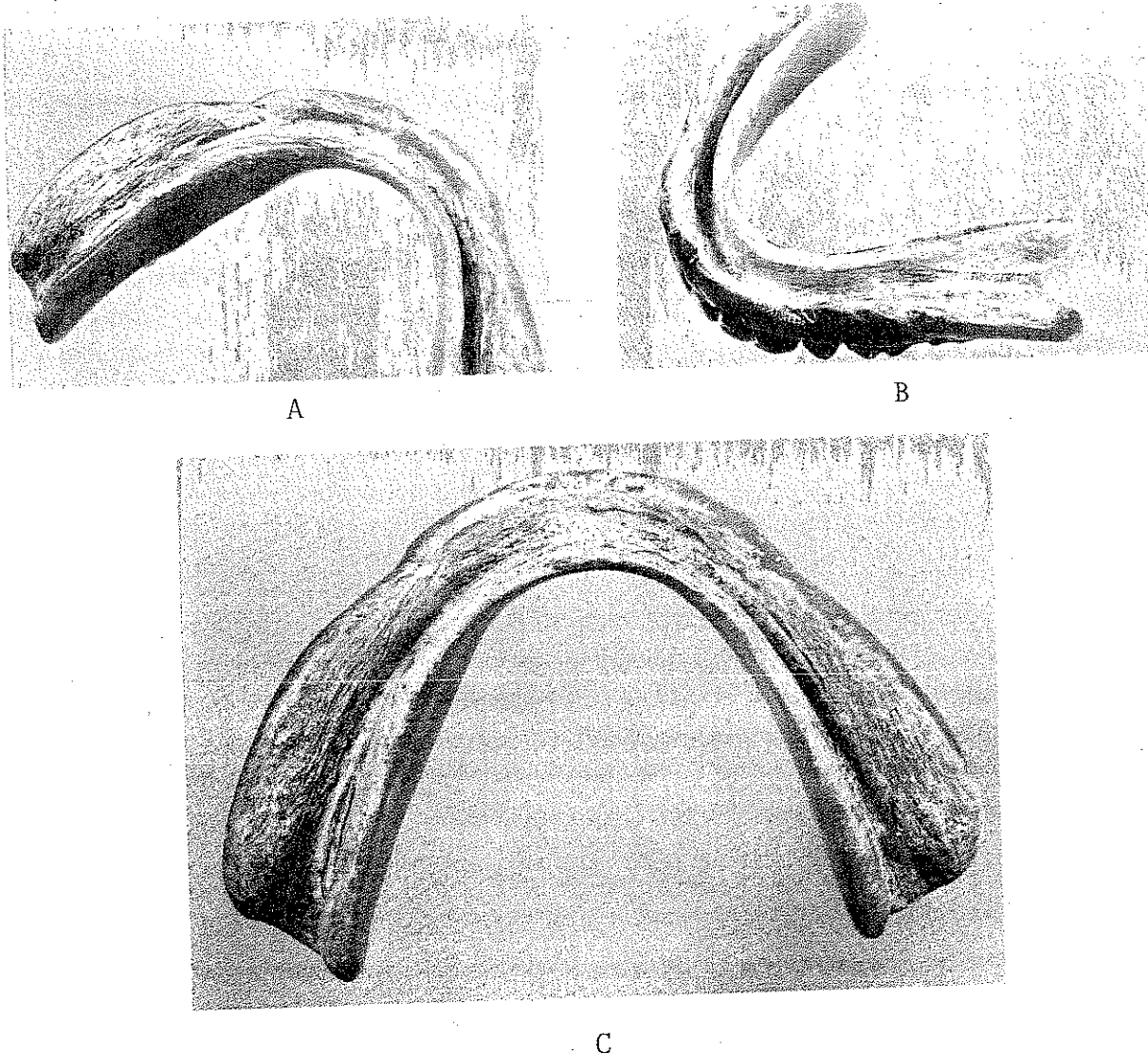


Figure 6:17. A and B illustrates Areas where Pressure is Not too Uncommon. These Areas are Adjusted Until Uniform Contact is Observed.

9. After adjusting the maxillary denture, set it aside, and carefully attempt to seat the mandibular denture in the patient's mouth.
10. If the denture meets resistance, STOP and proceed with the pressure indicating paste.
11. Apply the pressure indicating paste and carefully seat the denture.
12. Adjust the pressure areas using the vulcanite bur until the denture seats fully and contact appears uniform (Figure 6:17).

13. After the maxillary and mandibular dentures are adjusted to seat properly the notch areas of both dentures should be carefully inspected. The dentures should not impinge on any frenula. If impingement is observed, it must be eliminated by adjusting the notch with the fissure burs (Figure 6:18).

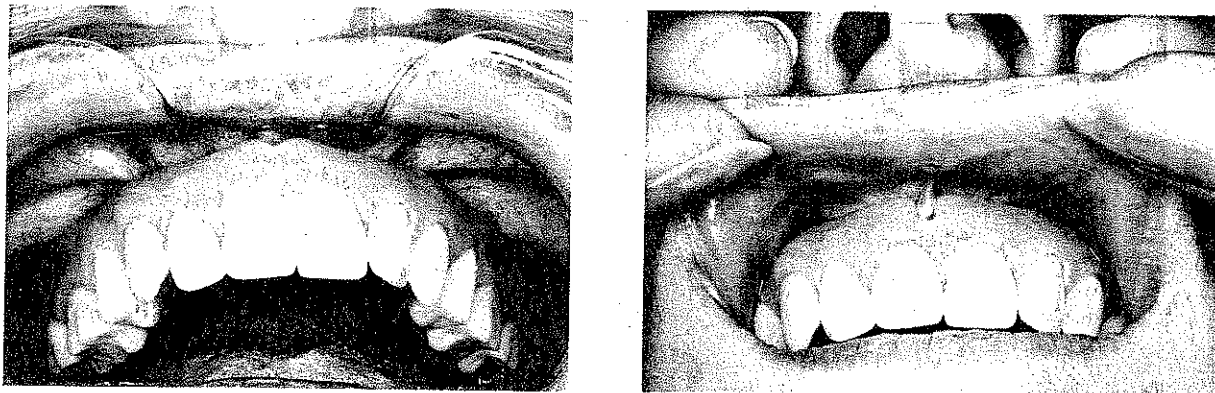


Figure 6:18. The Maxillary Labial Notch is Relieved.
Note: The Notch has been Elongated Rather than Opened into a "Vee".

14. Inspect the posterior border of the maxillary denture to see that it does not extend onto moveable tissue. Dry the denture with gauze and apply the dye from the indelible pencil along the posterior border of the denture. Also dry the posterior palatal tissues with gauze. Inform the patient that you are going to seat the denture fully and then remove it from the mouth. Instruct the patient to keep the mouth open after you remove the denture so as not to wet the palate with the tongue. Carefully seat the denture and then remove it. An indelible line will be transferred to the palate in the region of the moveable and immovable tissues. This line will provide a visual indication of the posterior extension of the maxillary denture.

With the denture removed, ask the patient to say "ah" and observe the relationship of the line to the moving tissues (Figure 6:19). If the line moves, the denture will have to be shortened. Use either the arbor band or the vulcanite bur to shorten the denture.

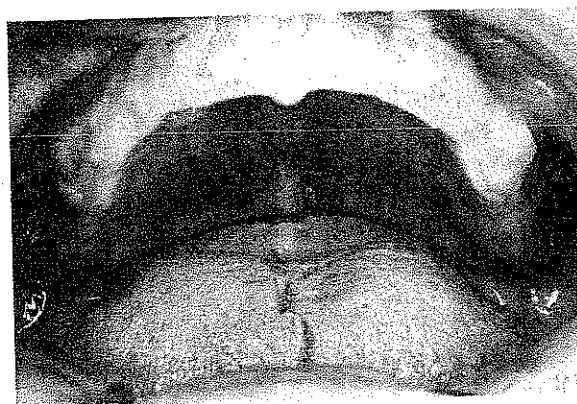
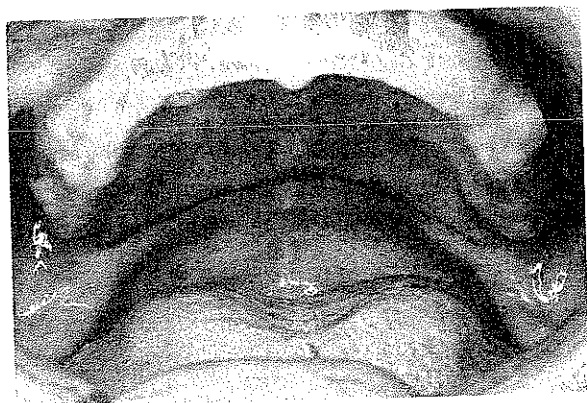
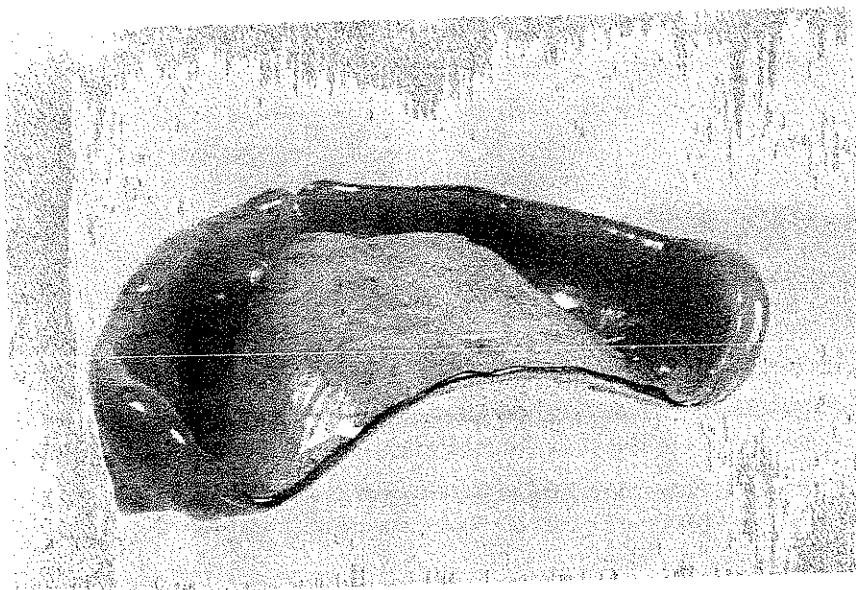


Figure 6:19. Indelible Dye is Placed on the Posterior Border of the Denture and Transferred to the Palatal Tissues. The Posterior Length of the Maxillary Denture Can Thus be Evaluated. If the Line Moves, the Denture Will Have to be Shortened.

15. After reducing the posterior border of the denture, the indelible dye should again be placed on the posterior border of the denture. It may be necessary to repeat this procedure several times until the indelible line is near the junction of the moveable and immovable tissues (Figure 6:20).

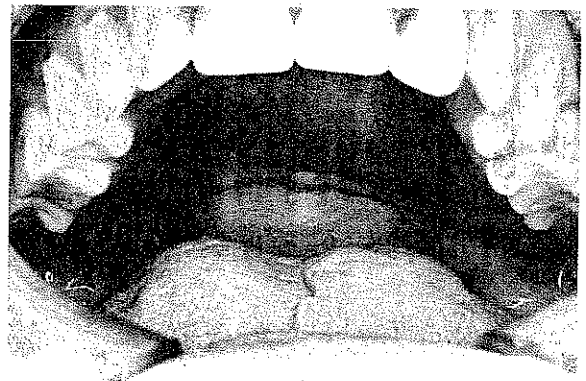
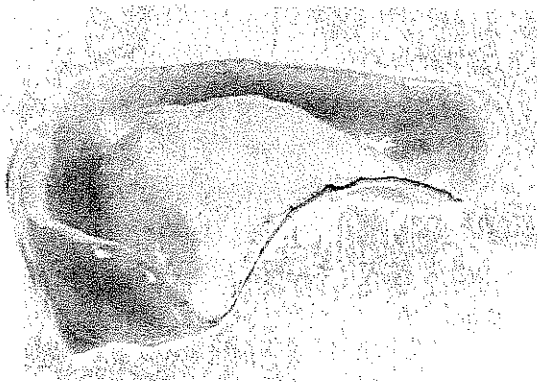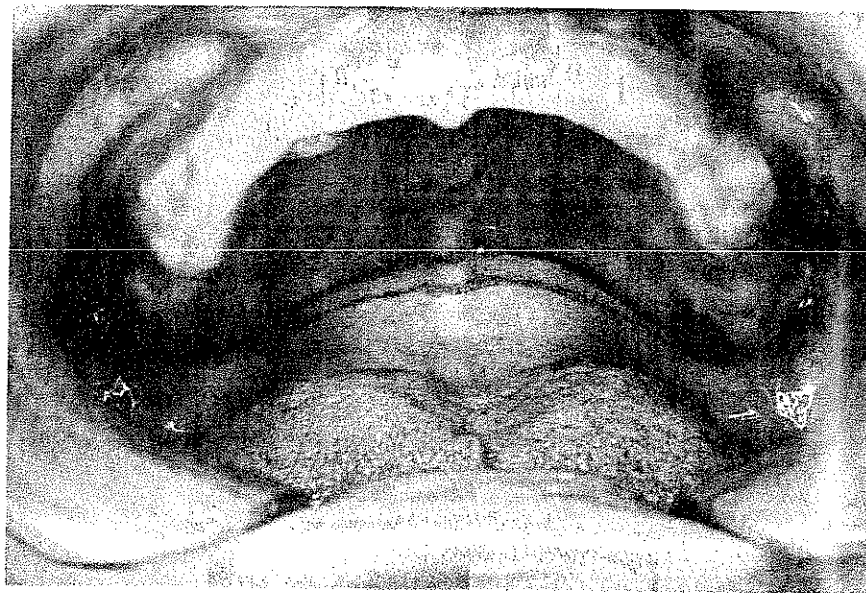


Figure 6:20. The Denture was Shortened and the Posterior Length Reevaluated.

16. After the length of the maxillary denture is adjusted, insert both dentures over the residual ridges. Place the patient's mandible in centric relation, and visually check the occlusion while holding the mandibular denture in place with your index fingers and thumbs.

If the occlusion is grossly open: The heels of the dentures may be contacting prematurely and will need adjustment.

If the occlusion is slightly open in the anterior (premature in the posterior): You are probably seeing discrepancies created by baseplate inaccuracy and processing change.

The dentures must now be remounted on the articulator, and the occlusion adjusted.

STEPS IN PERFORMING THE PATIENT REMOUNT




Figure 6:21. The Occlusal Index.

1. The occlusal index stored since the trial dentures were sent to the dental laboratory is now put to use (Figure 6:21).

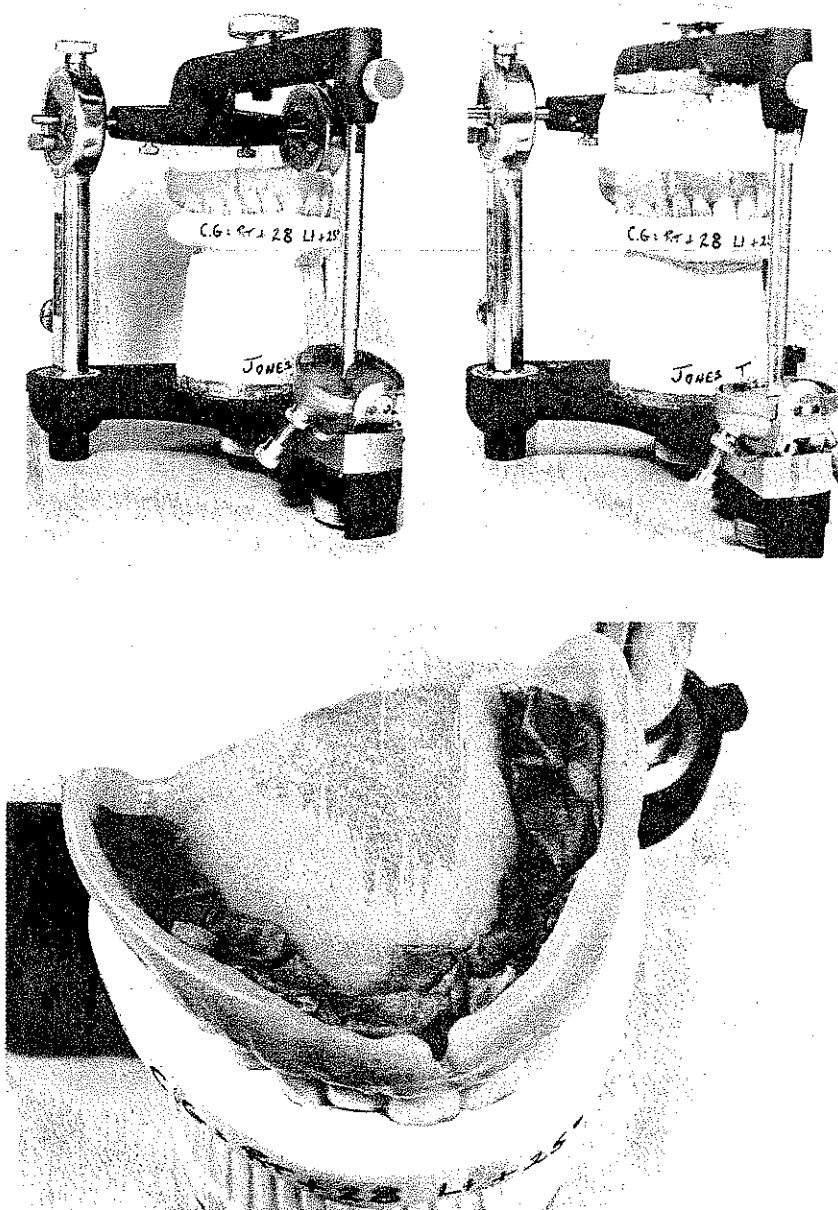


Figure 6:22. The Maxillary Denture is Remounted on the Articulator.

2. Orient the maxillary denture on the articulator using the occlusal index. Use some wet paper toweling to block out the undercuts (Figure 6:22).
3. Mount the maxillary denture on the articulator using impression plaster. After the plaster is set remove and cleanse the maxillary denture.

4. Carefully position the maxillary denture over the residual ridge. Place four small areas of Aluwax on the occlusal surfaces of the mandibular denture in the second molar and first bicuspid areas bilaterally. Heat the wax with a #7 spatula to create uniform softness. Instruct the patient to wet the occlusal surfaces of the maxillary teeth with saliva.
5. Insert the mandibular denture and place the patient's mandible in centric relation. Hold the mandibular denture in place with your index fingers and thumbs bilaterally. Allow the patient to close until contact is made with the soft Aluwax. Remove the mandibular denture and thoroughly chill it in cold water. Inspect the registration to ensure that there is no tooth to tooth contact through the wax which can create inaccuracy (Figure 6:23).

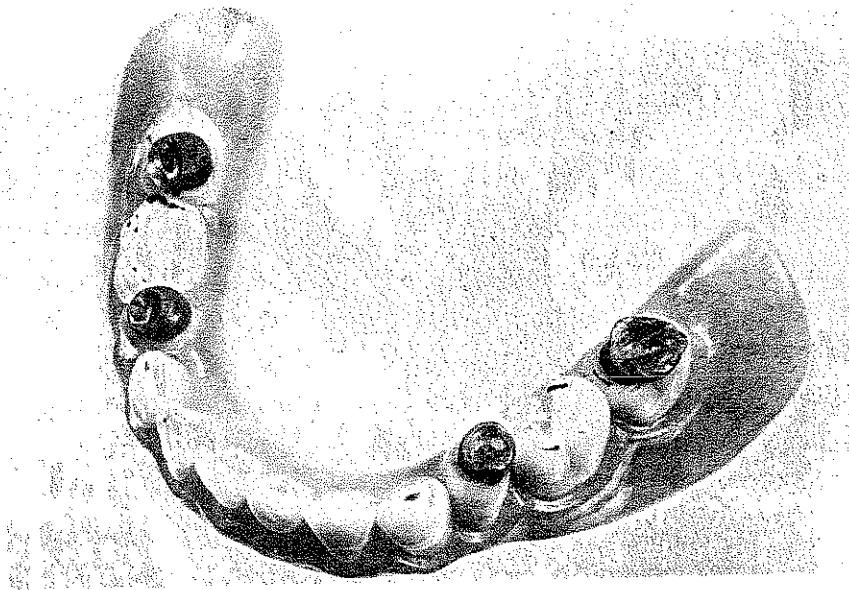

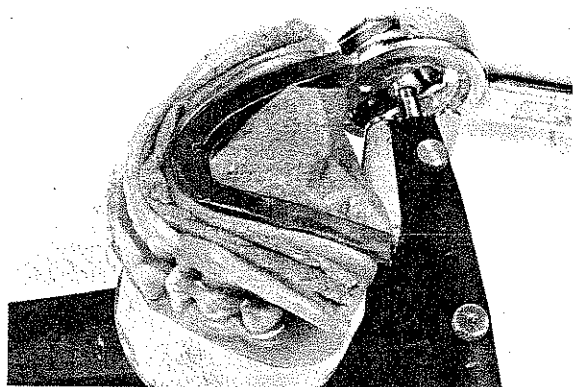


Figure 6:23. The Centric Jaw Relation Registration is Made using Four Small Areas of Wax to Record the Cusp Tip of the Opposing Maxillary Denture Teeth. No Tooth to Tooth Contact Through the Wax Should be Observed.

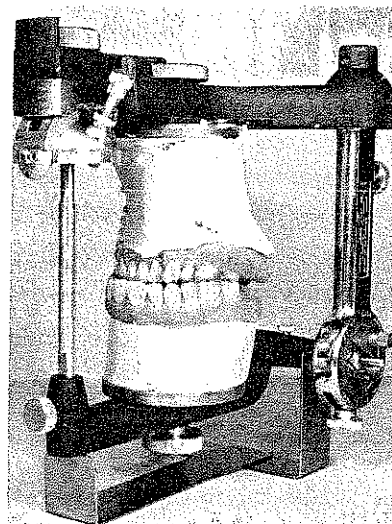
6. Interdigitate the centric jaw relation registration with the maxillary posterior teeth and join the two dentures with sticky wax. Block out the tongue space of the mandibular denture with wet paper towel and wax rope. Also block out any areas of undercut in the denture base. Either paper toweling or some wet pumice may be used for blockout material.
7. Mount the mandibular denture to the articulator using impression plaster (Figure 6:24).



A



B



C

Figure 6:24. A) The Interocclusal Record is Interdigitated and the Dentures are Luted Together with Sticky Wax. B) The Tongue Space is Blocked Out with Wet Toweling and Wax and the Mandibular Denture is Joined to the Articulator. Note: Be Sure to Block Out Any Undercuts in the Denture Base.

8. It is extremely important to verify the centric relation record and the mounting of the dentures. After the impression plaster sets, remove the dentures from the articulator and cleanse them of wax, toweling, and debris. Replace the Aluwax with new Aluwax and repeat the centric relation registration with the patient.
9. Remove the dentures from the mouth, chill them in water and carefully seat the denture on its respective impression plaster mounting.
10. With the condylar elements free to move, interdigitate the Aluwax interocclusal registration. If the condylar balls remain flush with their anterior metal stops when the maxillary teeth interdigitated with the Aluwax registration, then the mounting and centric relation record can be accepted (Figure 6:25). If a discrepancy is present, the centric relation record and/or the mounting must be repeated.

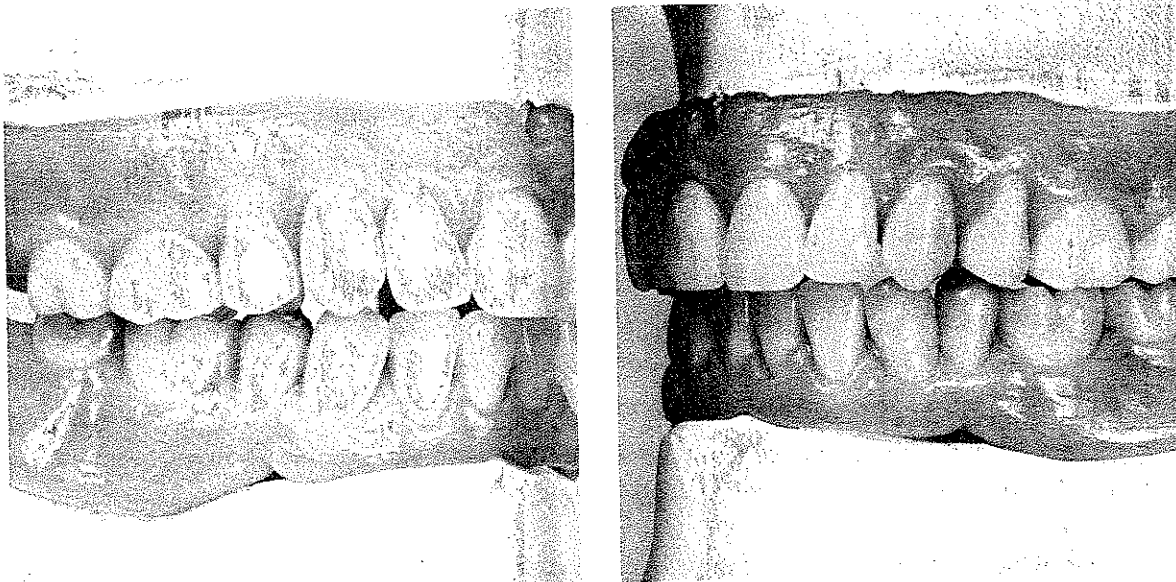


Figure 6:25. The Centric Relation Interocclusal Record is Repeated to Verify Centric Relation and the Mounting of the Dentures on the Articulator.

7. A further check of the accuracy of the mounting of the dentures is to compare the occlusal marking of the first prematurity in the patient's mouth with that seen on the articulator (Figure 6:26).

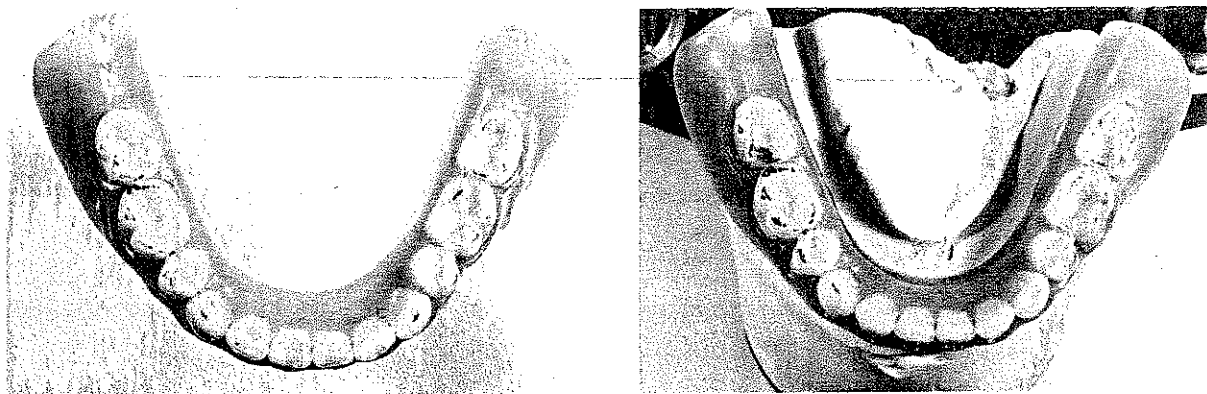


Figure 6:26. The Initial Occlusal Marking with Articulating Paper on the Articulator and in the Mouth Must be the Same.

STEPS IN REFINING THE OCCLUSION (OCCLUSAL EQUILIBRATION)

1. Dentures must never be delivered without remounting the articulator and performing an occlusal equilibration. Two methods of occlusal adjustment are used:
 - a. Selective grinding.
 - b. Equilibration by stripping.

Both of these methods can result in bilateral balanced occlusion.

Stripping Method. This is the method of choice when the posterior occlusal scheme involves rational or zero degree teeth in both arches. Number 340 grit Carborundum paper cut into narrow strips is pulled between the occlusal surfaces of the opposing teeth. The paper being abrasive on one side only, removes the premature contacts until an evenness is present. The maxillary teeth are the ones that are reduced by the stripping method.

Selective Grinding. This method is the one most commonly used when the occlusal scheme involves: a) anatomic, b) semianatomic, or c) combinations of molds such as 20° maxillary teeth opposing 0° mandibular teeth.

For the patient illustrated, a combination of maxillary 20° teeth and mandibular 0° or rational posteriors were used. The selective grinding sequence for this combination involves creating the various gothic arch tracings on the occlusal surfaces of the mandibular posterior teeth that correspond to the pathways of movement of the articulator. The instruments to grind the teeth are the same as those described in Procedure 15 with the addition of the #8 round bur to be used with acrylic resin teeth.

SELECTIVE OCCLUSAL GRINDING TO ESTABLISH CENTRIC OCCLUSION

1. Grind all occlusal prematurities except the lingual cusps of the maxillary posterior teeth (Figure 6:27).

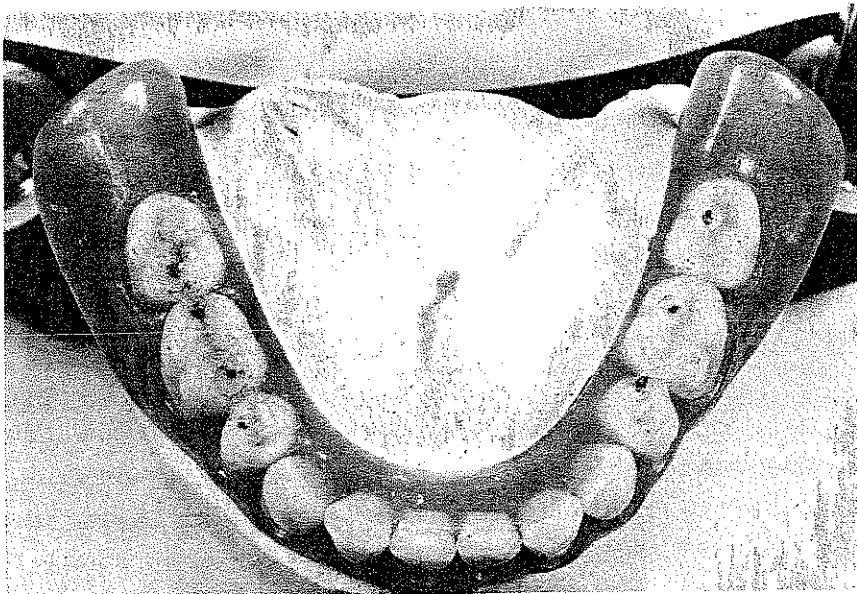


Figure 6:27. The Maxillary Lingual Cusps are the Main Supporting Cusps and Must Occlude Evenly on Both Sides with the Mandibular Teeth in Centric Occlusion

SELECTIVE OCCLUSAL GRINDING TO ACHIEVE BALANCED LATERAL MOVEMENTS

1. Set the articulator to the settings used when the dentures were constructed.
2. Working contacts - grind according to the BULL RULE.
3. Cross-arch balancing contacts - grind the buccal cusp inclines on the mandibular posterior teeth. (Figure 6:28).

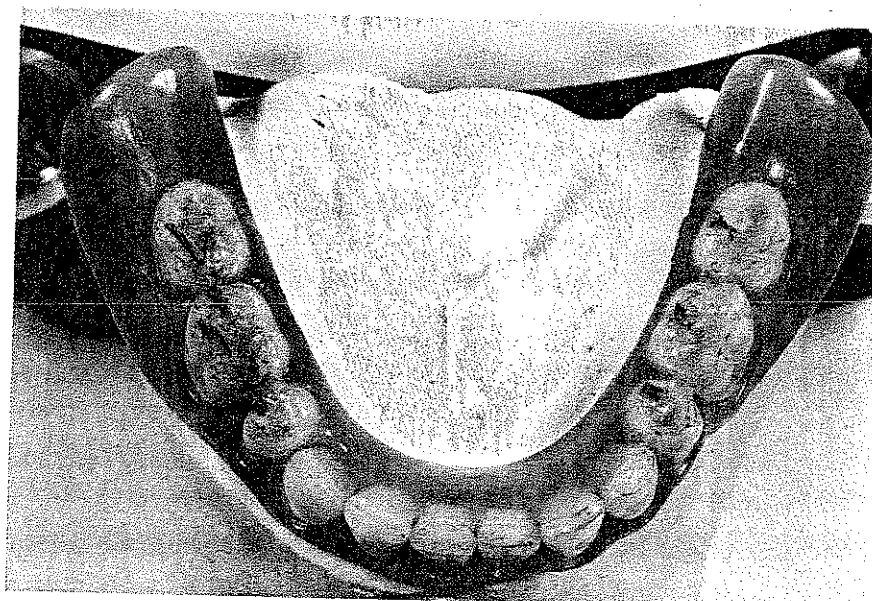
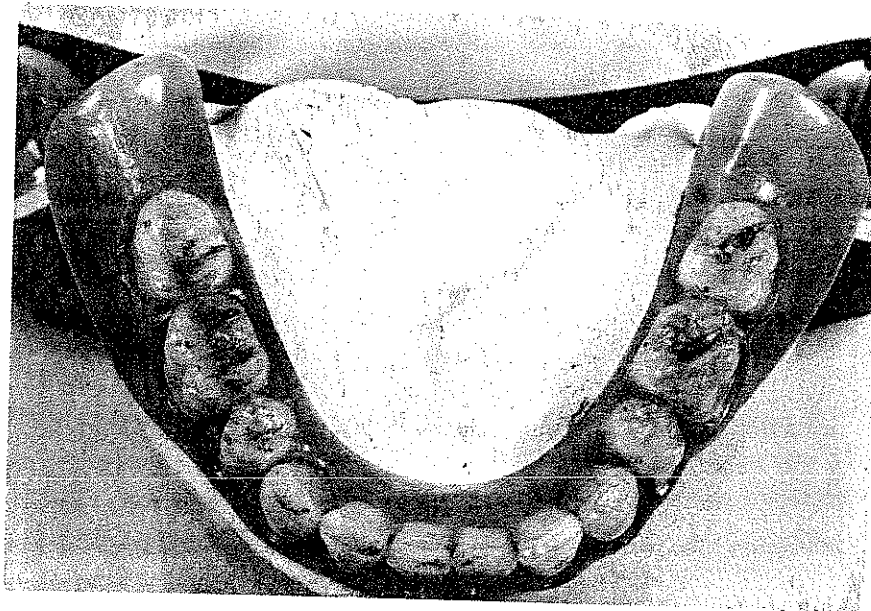


Figure 6:28. (Top) Right Lateral Movement and (Bottom) Left Lateral Movement.

SELECTIVE GRINDING TO ACHIEVE BALANCED PROTRUSIVE MOVEMENT

1. Protrusive movement - grind the buccal cusp inclines of the maxillary posterior teeth. Eliminate deflective occlusal contacts in the areas of the marginal ridges of the mandibular posterior teeth (Figure 6:29).

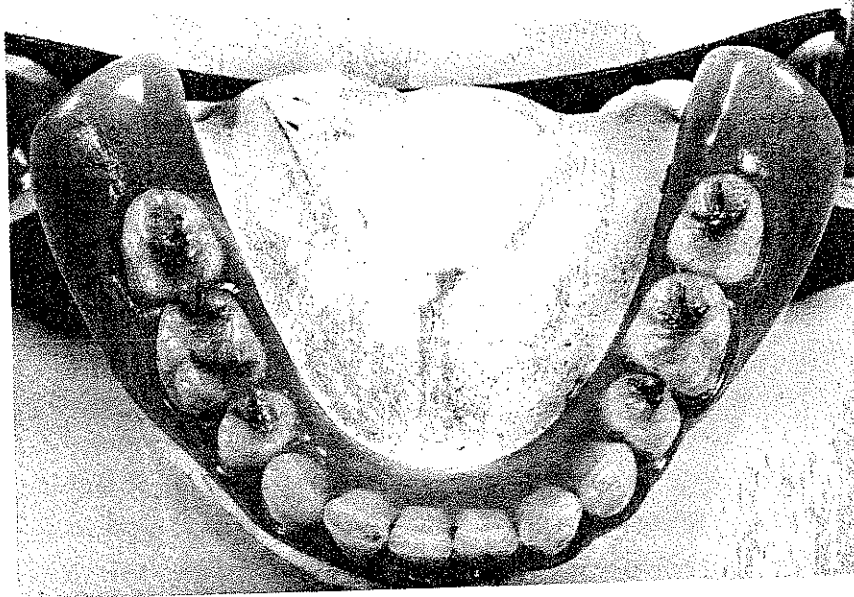
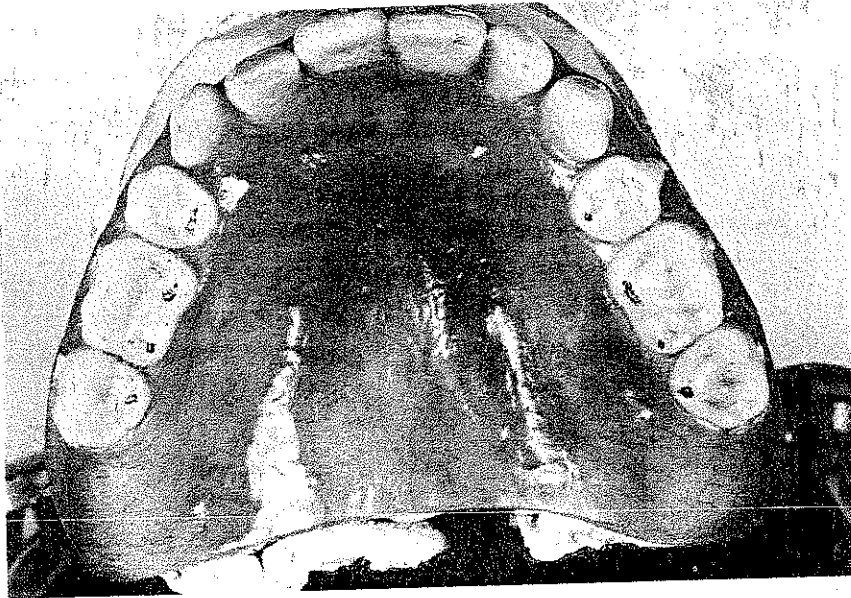


Figure 6:29. The Maxillary Lingual Cusp is Maintained as the Primary Supporting Cusp and the Working, Balancing, and Protrusive Guidance Pathways are Ground on the Occlusal Surfaces of the Mandibular Posterior Teeth.

BALANCED OCCLUSION - THE PATIENT

Selective grinding was completed on the articulator in sequence following specified rules to establish centric occlusion and working, balancing, and protrusive guidance pathways for the lateral and protrusive movements. It must be emphasized that a balanced occlusion in harmony with the articulator can be created. However, it must not be assumed that the developed occlusion is always transferrable to the patient.

1. Following the selective grinding sequence, the dentures are removed from the articulator, cleansed of all occlusal markings and debris with the denture brush, warm water, and a detergent.
2. The dentures are carefully inserted over the residual ridge and the esthetics and occlusion inspected (Figures 6:30 and 6:31).



Figure 6:30. The Esthetics and Lip Support are Evaluated.

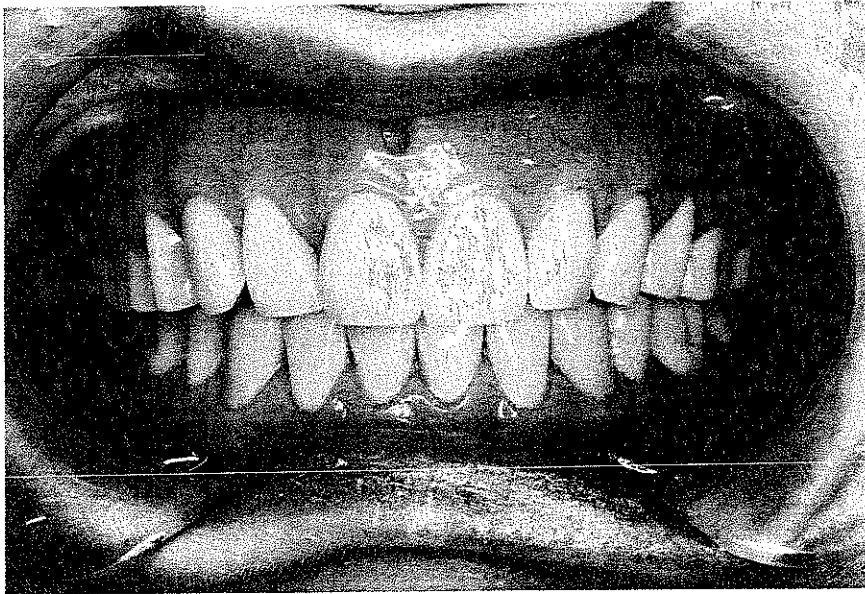


Figure 6:31. The Denture in Centric Occlusion at Centric Jaw Relation.

3. Before the patient is dismissed, further written or verbal instructions are given in:
 - a. How to clean the dentures.
 - b. What to eat during the week to ten days following the delivery appointment.
 - c. The need for recall and maintenance and the date and time for the next appointment.
4. Final evaluation of the dentures is made using the criteria sheets.

CRITERIA - CORRECTING THE OCCLUSION
 AFTER PATIENT REMOUNT ON THE ARTICULATOR

		<u>Meets</u> <u>Criteria</u>	<u>Does not</u> <u>meet Criteria</u>	<u>Comments</u>
1.	There are no heel interferences at the established occlusal vertical dimension or during excursive movements.	<input type="checkbox"/>	<input type="checkbox"/>	
2.	Maximum posterior tooth contacts bilaterally, simultaneously, and anteroposteriorly in centric occlusion.	<input type="checkbox"/>	<input type="checkbox"/>	
3.	The anterior teeth are <u>not</u> in contact in centric occlusion.	<input type="checkbox"/>	<input type="checkbox"/>	
4.	Light contact for the maxillary and mandibular anterior teeth is observed in a protrusive movement.	<input type="checkbox"/>	<input type="checkbox"/>	
5.	The occlusion exhibits a maximum degree of balance when the articulator is moved in lateral and protrusive excursions.			
	Working Right	<input type="checkbox"/>	<input type="checkbox"/>	
	Working Left	<input type="checkbox"/>	<input type="checkbox"/>	
	Balancing Right	<input type="checkbox"/>	<input type="checkbox"/>	
	Balancing Left	<input type="checkbox"/>	<input type="checkbox"/>	
	Protrusive Right	<input type="checkbox"/>	<input type="checkbox"/>	
	Protrusive Left	<input type="checkbox"/>	<input type="checkbox"/>	

CRITERIA - MAXILLARY AND MANDIBULAR
COMPLETE DENTURES AT THE DELIVERY APPOINTMENT

<u>Maxillary Denture Base Outline Form</u>	<u>Meets Criteria</u>	<u>Does not meet Criteria</u>	<u>Comments</u>
1. The posterior border of the buccal flanges extends into the retrozygomatic space.			
Right	<input type="checkbox"/>	<input type="checkbox"/>	
Left	<input type="checkbox"/>	<input type="checkbox"/>	
2. The hamular notches are included in the posterior borders.			
Right	<input type="checkbox"/>	<input type="checkbox"/>	
Left	<input type="checkbox"/>	<input type="checkbox"/>	
3. The posterior border does not extend onto moveable tissue. [Evaluation of the posterior border is made by drying the denture base and posterior palate and using the indelible pencil on the posterior border of the dentures to transfer its length to the tissues.]			
	<input type="checkbox"/>	<input type="checkbox"/>	
4. The buccal flanges fill as much as possible the buccal sulcus.			
Right	<input type="checkbox"/>	<input type="checkbox"/>	
Left	<input type="checkbox"/>	<input type="checkbox"/>	
5. The labial flanges fill the labial sulcus.			
Right	<input type="checkbox"/>	<input type="checkbox"/>	
Left	<input type="checkbox"/>	<input type="checkbox"/>	

		<u>Meets</u> <u>Criteria</u>	<u>Does not</u> <u>meet Criteria</u>	<u>Comments</u>
6.	<u>All flanges are rolled.</u>			
	Labial			
	Right	<input type="checkbox"/>	<input type="checkbox"/>	
	Left	<input type="checkbox"/>	<input type="checkbox"/>	
	Buccal			
	Right	<input type="checkbox"/>	<input type="checkbox"/>	
	Left	<input type="checkbox"/>	<input type="checkbox"/>	
7.	The flanges are not sharp.			
	Labial			
	Right	<input type="checkbox"/>	<input type="checkbox"/>	
	Left	<input type="checkbox"/>	<input type="checkbox"/>	
	Buccal			
	Right	<input type="checkbox"/>	<input type="checkbox"/>	
	Left	<input type="checkbox"/>	<input type="checkbox"/>	
8.	The denture flanges do not impinge on the frenula.			
	Labial	<input type="checkbox"/>	<input type="checkbox"/>	
	Buccal			
	Right	<input type="checkbox"/>	<input type="checkbox"/>	
	Left	<input type="checkbox"/>	<input type="checkbox"/>	
9.	The notches are not excessively relieved.			
	Labial	<input type="checkbox"/>	<input type="checkbox"/>	
	Buccal			
	Right	<input type="checkbox"/>	<input type="checkbox"/>	
	Left	<input type="checkbox"/>	<input type="checkbox"/>	
10.	The denture flanges are symmetrical.			
	Labial	<input type="checkbox"/>	<input type="checkbox"/>	
	Buccal	<input type="checkbox"/>	<input type="checkbox"/>	

<u>Mandibular Denture Base Outline Form</u>	<u>Meets Criteria</u>	<u>Does not meet Criteria</u>	<u>Comments</u>
---	---------------------------	-----------------------------------	-----------------

1. The denture base covers,
but does not extend
beyond the retromolar
pads.

Right	<input type="checkbox"/>	<input type="checkbox"/>
Left	<input type="checkbox"/>	<input type="checkbox"/>

2. The buccal flanges
extend onto the buccal
shelf.

Right	<input type="checkbox"/>	<input type="checkbox"/>
Left	<input type="checkbox"/>	<input type="checkbox"/>

3. The labial flanges extend
into the labial sulcus.

Right	<input type="checkbox"/>	<input type="checkbox"/>
Left	<input type="checkbox"/>	<input type="checkbox"/>

4. The denture flanges do
not impinge on the frenula.

Labial	<input type="checkbox"/>	<input type="checkbox"/>
Lingual	<input type="checkbox"/>	<input type="checkbox"/>
Right	<input type="checkbox"/>	<input type="checkbox"/>
Buccal	<input type="checkbox"/>	<input type="checkbox"/>
Left	<input type="checkbox"/>	<input type="checkbox"/>

5. Notches are not excessively
relieved.

Labial	<input type="checkbox"/>	<input type="checkbox"/>
Lingual	<input type="checkbox"/>	<input type="checkbox"/>
Right	<input type="checkbox"/>	<input type="checkbox"/>
Buccal	<input type="checkbox"/>	<input type="checkbox"/>
Left	<input type="checkbox"/>	<input type="checkbox"/>

		<u>Meets</u> <u>Criteria</u>	<u>Does not</u> <u>meet Criteria</u>	<u>Comments</u>
6.	The lingual flanges are at or slightly below the mylohyoid ridges.			
	Right	<input type="checkbox"/>	<input type="checkbox"/>	
	Left	<input type="checkbox"/>	<input type="checkbox"/>	
7.	The most posterior extensions of the lingual flanges extend into the retromylohyoid spaces.	<input type="checkbox"/>	<input type="checkbox"/>	
8.	<u>All</u> flanges are rolled.			
	Labial Right	<input type="checkbox"/>	<input type="checkbox"/>	
	Left	<input type="checkbox"/>	<input type="checkbox"/>	
	Buccal Right	<input type="checkbox"/>	<input type="checkbox"/>	
	Left	<input type="checkbox"/>	<input type="checkbox"/>	
9.	The flanges are not sharp.			
	Labial Right	<input type="checkbox"/>	<input type="checkbox"/>	
	Left	<input type="checkbox"/>	<input type="checkbox"/>	
	Buccal Right	<input type="checkbox"/>	<input type="checkbox"/>	
	Left	<input type="checkbox"/>	<input type="checkbox"/>	
10.	The denture flanges are symmetrical.			
	Labial	<input type="checkbox"/>	<input type="checkbox"/>	
	Lingual	<input type="checkbox"/>	<input type="checkbox"/>	
	Buccal Right	<input type="checkbox"/>	<input type="checkbox"/>	
	Left	<input type="checkbox"/>	<input type="checkbox"/>	

<u>Retention</u>	<u>Meets Criteria</u>	<u>Does not meet Criteria</u>	<u>Comments</u>
1. The maxillary denture is retentive. [Evaluation of retention is made when a moderate pressure with a lateral component is applied to the maxillary cuspid unilaterally.]	<input type="checkbox"/>	<input type="checkbox"/>	

Occlusal Vertical Dimension

1. The patient demonstrates an acceptable inter-occlusal distance upon closing from physiologic rest position to vertical dimension of occlusion.	<input type="checkbox"/>	<input type="checkbox"/>	
---	--------------------------	--------------------------	--

[Evaluation of physiologic rest position and the vertical dimension is made with the patient in an upright position. After instructing the patient to open the mouth widely and then close to light lip contact, the facial tissues should appear relaxed as an observation that the patient's mandible is at physiologic rest position. The patient is then instructed to close until the teeth contact. Speech is another test for the inter-occlusal distance.]

Occlusion

1. The posterior teeth should contact bilaterally and simultaneously without causing either denture to shift when closing in centric occlusion.	<input type="checkbox"/>	<input type="checkbox"/>	
---	--------------------------	--------------------------	--

Meets Criteria Does not meet Criteria Comments

[Evaluation is made with the operator stabilizing the mandibular denture against the residual ridge, with the index fingers against the buccal flanges and the thumbs supporting against the inferior border of the mandible in the first molar areas. The mandible is guided to the retruded position until it hinges. The contact relationship can be evaluated visually or with articulating paper.]

- | | | | |
|----|--|--------------------------|--------------------------|
| 2. | The anterior teeth are not in contact in centric occlusion. | <input type="checkbox"/> | <input type="checkbox"/> |
| 3. | Light contact for the maxillary and mandibular anterior teeth is observed in a protrusive movement. | <input type="checkbox"/> | <input type="checkbox"/> |
| 4. | The occlusion exhibits a degree of balance when the patient is guided forward or laterally from centric occlusion. | | |
| | Working Right | <input type="checkbox"/> | <input type="checkbox"/> |
| | Left | <input type="checkbox"/> | <input type="checkbox"/> |
| | Balancing Right | <input type="checkbox"/> | <input type="checkbox"/> |
| | Left | <input type="checkbox"/> | <input type="checkbox"/> |
| | Protrusive Right | <input type="checkbox"/> | <input type="checkbox"/> |
| | Left | <input type="checkbox"/> | <input type="checkbox"/> |

	<u>Meets</u> <u>Criteria</u>	<u>Does not</u> <u>meet Criteria</u>	<u>Comments</u>
5. The arch arrangement is symmetrical with the central fossae of the mandibular teeth positioned in the center of the residual ridge and projecting posteriorly in a straight line.			
Right	<input type="checkbox"/>	<input type="checkbox"/>	
Left	<input type="checkbox"/>	<input type="checkbox"/>	
6. The long axes of the mandibular anterior teeth are directed toward the anterior portion of the residual ridge with the cervicals of the teeth slightly depressed.	<input type="checkbox"/>	<input type="checkbox"/>	
7. The denture provides an acceptable plane of occlusion. [In general, the plane of occlusion should be at or slightly below the corner of the mouth at minimal opening and project posteriorly below the top of the retromolar pad.]	<input type="checkbox"/>	<input type="checkbox"/>	
<u>The Polished Surfaces</u>			
1. The free gingival margins are well defined.	<input type="checkbox"/>	<input type="checkbox"/>	
2. A slight concavity is observed between the gingival margin and the periphery.	<input type="checkbox"/>	<input type="checkbox"/>	
3. <u>All</u> areas of the acrylic are smooth.	<input type="checkbox"/>	<input type="checkbox"/>	

<u>The Polished Surfaces</u>	<u>Meets Criteria</u>	<u>Does not meet Criteria</u>	<u>Comments</u>
4. The interproximal papillae are well formed.	<input type="checkbox"/>	<input type="checkbox"/>	
5. <u>No</u> landing areas are present at the peripheries.	<input type="checkbox"/>	<input type="checkbox"/>	
6. The palate is a uniform 2-3 mms. thick.	<input type="checkbox"/>	<input type="checkbox"/>	
7. The posterior border tapers to a thickness of approximately 1.5 mms.	<input type="checkbox"/>	<input type="checkbox"/>	
8. The lingual flanges are of adequate thickness to allow for adjustment.	<input type="checkbox"/>	<input type="checkbox"/>	

SELF TEST 6
CORRECTING OCCLUSION AFTER PROCESSING,
FINISHING, POLISHING, DELIVERING THE COMPLETE DENTURE

(Circle correct response(s) or write brief answers. For correct answers, consult the Answer Key.)

1. When selective grinding the teeth to reestablish centric occlusion after processing, you grind:
 - a. The central fossae and marginal ridges.
 - b. The inclines and embrasures.
 - c. The cusp tips of the supporting cusps.
 - d. All areas of contact until evenness is achieved.

2. Identify the articulating paper marks shown in A and B Figure T6:1 as:
 - a. Protrusive movement.
 - b. Right lateral movement.
 - c. Left lateral movement.

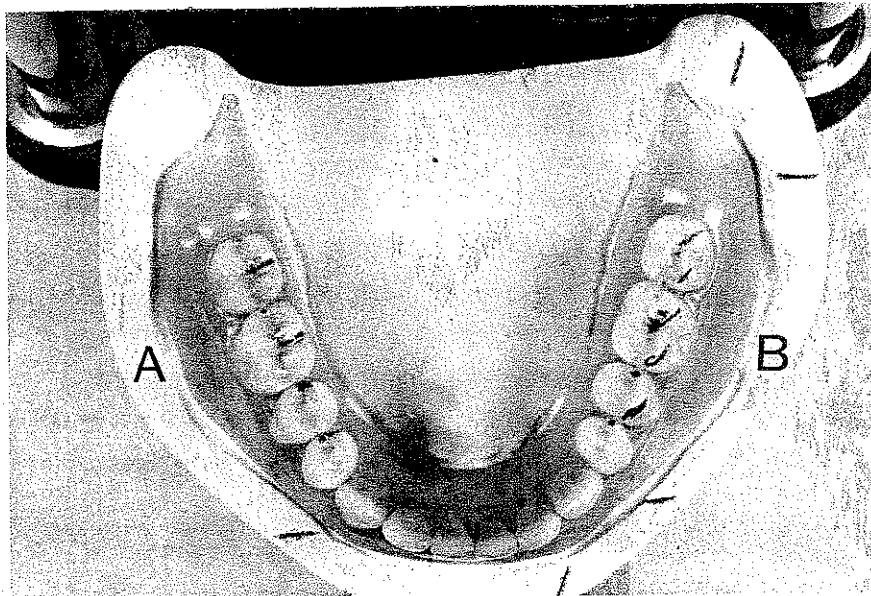


Figure T6:1

- 3. After processing the denture, we use the _____ rule to establish the working movement occlusion.
 - T F 4. When grinding the denture teeth to achieve even working and balancing contacts we always grind on the supporting cusps.
 - 5. Identify the articulating paper marks shown in Figure T6:2 areas A and B.
- Contacts at A are _____.
- Contacts at B are _____.

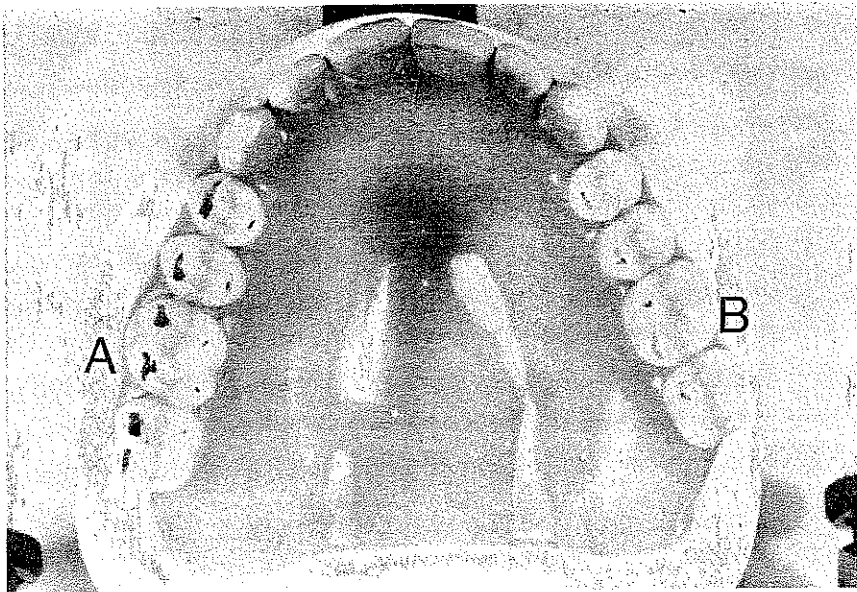


Figure T6:2

6. Identify the articulating paper marks shown in Figure T6:3 areas A and B.

Contacts at A are _____.

Contacts at B are _____.

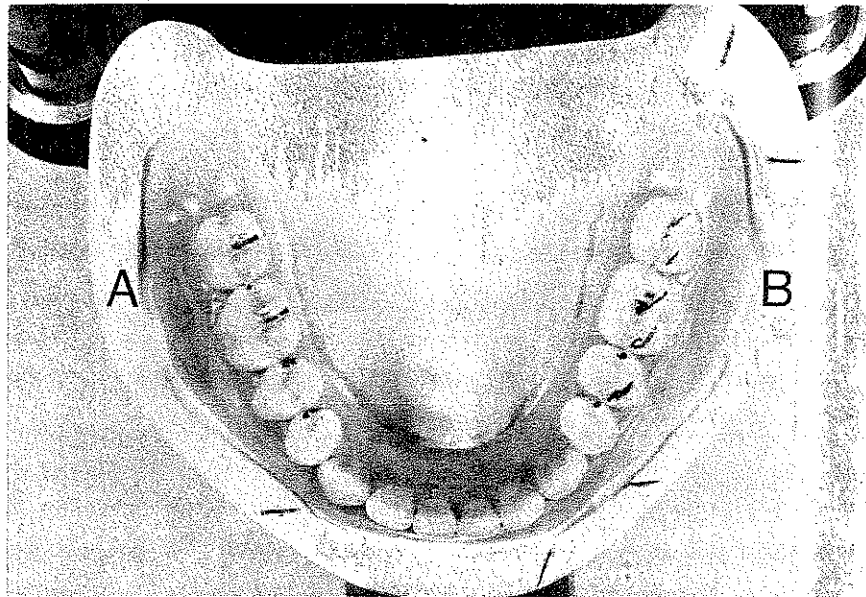


Figure T6:3

- T F 7. When delivering the completed dentures to the patient, the labial frenum should be opened to a "vee" with acrylic burs.

- T F 8. Using milling paste to correct the occlusion is a form of selective grinding.
9. The error(s) in Figure T6:4 was (were) created during the construction of the denture and observed after processing. The operator:
- Failed to add sufficient wax to the lingual flange during the wax-up procedure.
 - Failed to establish sufficient thickness during the border molding procedure.
 - Polished the tissue surface of the denture.
 - Placed the mandibular teeth too far lingually thus encroaching on the tongue space of the patient.

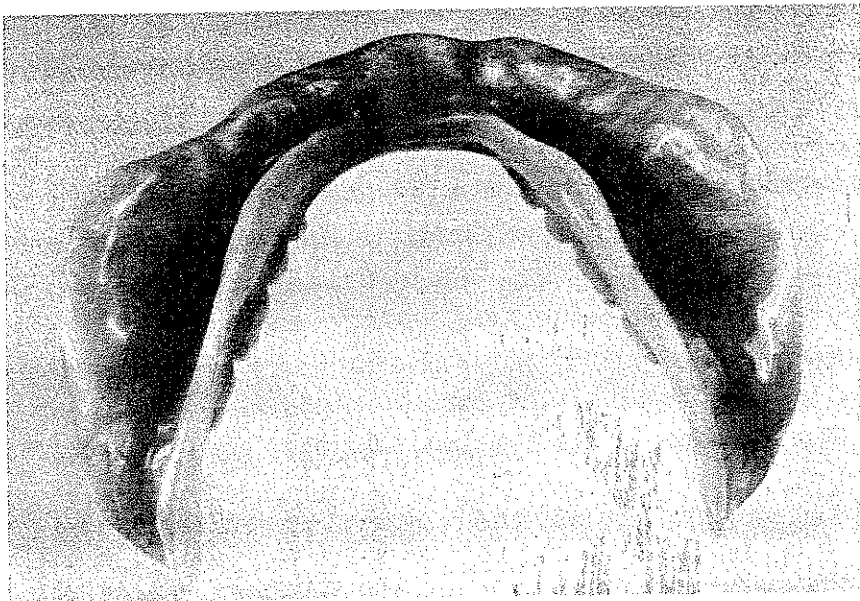


Figure T6:4

- T F 10. When delivering the completed dentures to the patient, the maxillary labial notch should be opened to a "vee" with the large acrylic burs to prevent tissue encroachment.
11. The error(s) in Figure T6:5 was (were) created during the construction of the denture and observed after processing. The operator:
- Failed to add sufficient wax to the lingual necks of the posterior teeth.
 - Failed to provide sufficient gingival roll during the waxing procedure.
 - Failed to develop adequate buccal contour to the mandibular denture.
 - Failed to fill the interproximal areas.

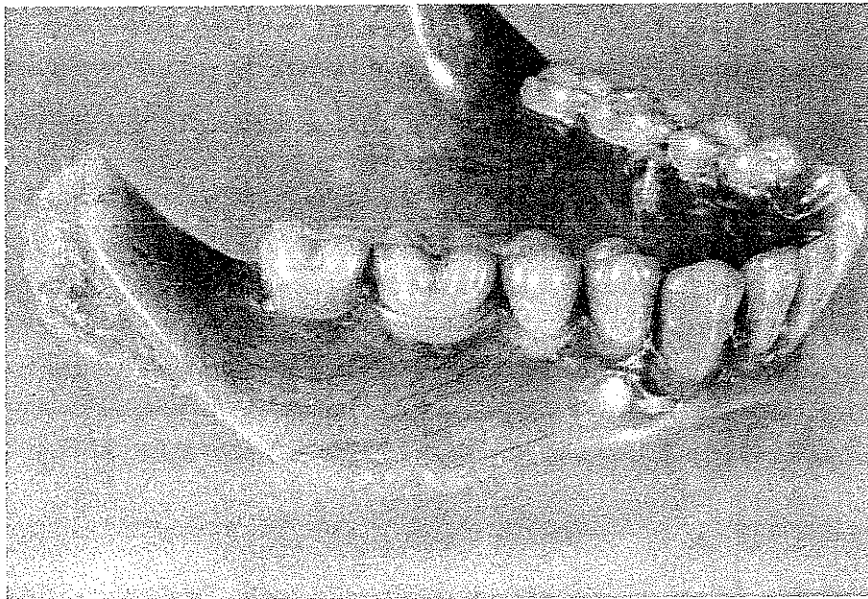


Figure T6:5

12. The major mistake(s) in Figure T6:6 is (are):
-

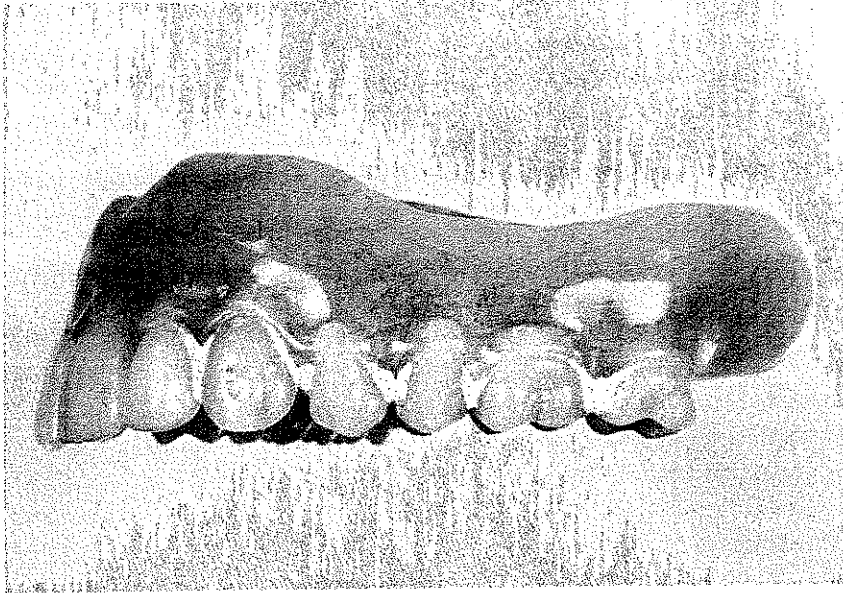


Figure T6:6

13. The major mistake(s) in Figure T6:7 is (are):
-

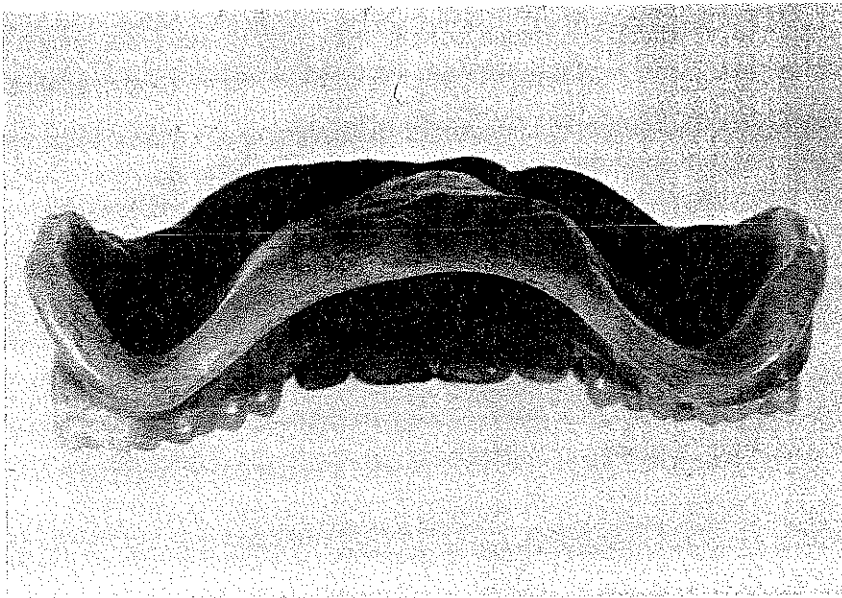


Figure T6:7


COMPUTER-GENERATED SECTION TEST 6

You are now ready to take Computer-Generated Section Test 6, which will cover:

1. Correcting the occlusion of the complete dentures after processing.
2. Finishing and polishing the complete dentures.
3. Delivering the complete dentures to the patient.

When you have completed the laboratory procedures which this Section Test covers and are ready to take this test, go to the Caident Center. All Section Tests are on the computer. The proctor in the Caident Center will instruct you on how to take the test. As you take the test, the computer will inform you of your incorrect answers and tell you the correct answer. As soon as you have completed the test, the computer will display your score. Call the proctor to record your score on the Clinic Progress Card.

There are 6 items in this test. The criterion level (the required correct score) is 67%.



REPAIRING A BROKEN DENTURE,
REPLACING A DENTURE TOOTH, AND
GLOSSARY OF PROSTHODONTIC TERMS

SECTION

7

OBJECTIVES

Knowledge. Upon completion of this Section, you will be able to:

1. State the conditions under which repair of a denture or replacement of a denture tooth may be performed by the dentist.
2. Name the steps in repairing a denture and in replacing a denture tooth, using a chemically activated acrylic resin.
3. Name the criteria for a denture repair and for a tooth replacement.
4. Define and identify the terminology and nomenclature used in Complete Denture Prosthodontics.

Skills. You will develop the skills necessary to complete Procedure #18.

ABOUT REPAIRS

Patients usually fracture their dentures at the most inopportune time. This usually results in some panic on their part, and being perhaps unable to get to their dentist for treatment immediately, they will attempt to repair the dentures themselves. Most household glues or adhesives when applied to acrylic resin will chemically destroy the denture base. As a result of the alterations in the base materials, the margin integrity at the fracture site is destroyed.

When the patient finally arrives for treatment and repair of the denture, the parts of the denture can no longer be realigned. The dentist can make repairs for any acrylic resin prosthesis as long as the parts can accurately be repositioned.

Fractured dentures may be the result of dropping the dentures or a malfunction. If the dentures were not dropped, the patient should be told that following the repair of the fracture, the dentures will need to be evaluated to determine why the fracture occurred. It may be that the denture occlusion will need to be adjusted, the dentures relined or rebased, or new dentures constructed.

FRACTURED TEETH

The fracturing of a denture tooth is also of great concern to the patient. Esthetically, the fractured tooth will many times "Spell" denture. The patient should be reassured that this is not a major repair and can be done, as can the fracture repair in the dental office in a relatively short time.

THE GLOSSARY OF PROSTHODONTIC TERMS

In order to be competent in Complete Denture Prosthodontics, the student must be able to use correctly all the professionally accepted terminology in addition to having mastered all of the clinical and technical procedures in the treating of edentulous¹ patients. Therefore, you should study and consult the Glossary¹ and the Reference materials in this Study and Procedure Guide throughout your dental education in Complete Denture Prosthodontics.

REFERENCE

1. The Glossary of Prosthodontic Terms, 3rd Edition, J. Prosth. Dent., 1968, 20:444-480.

OBJECTIVES

Knowledge. Upon completion of this Procedure you will be able to:

1. State in sequential order, the steps in repairing a broken denture using a chemically activated acrylic resin.
2. State in sequential order, the steps in replacing a denture tooth, using chemically activated acrylic resin.
3. Name the criteria for an acceptable denture repair.
4. Name the criteria for the acceptable replacement of a denture tooth.

Skill. Upon completion of this Procedure, you will be able to:

1. Repair a broken mandibular complete denture.
2. Replace a maxillary anterior denture tooth.

VIDEOTAPE

There are no videotapes on repairs.

MATERIALS NEEDED FOR PROCEDURE #18

1. Acrylic resin repair kit - Monomer and polymer.
2. #7 spatula.
3. Sticky wax.
4. Tongue blade.
5. Rubber bowl.
6. Kerr laboratory spatula.
7. Impression plaster.
8. Glass slab.
9. Laboratory knife.
10. (2) small paint brushes.
11. Tinfoil substitute.
12. Vaseline.
13. (2) small dappen dishes.
14. Pear-shaped vulcanite bur.
15. Rag wheel and felt cones.
16. Pumice.
17. #558 cross cut fissure bur.

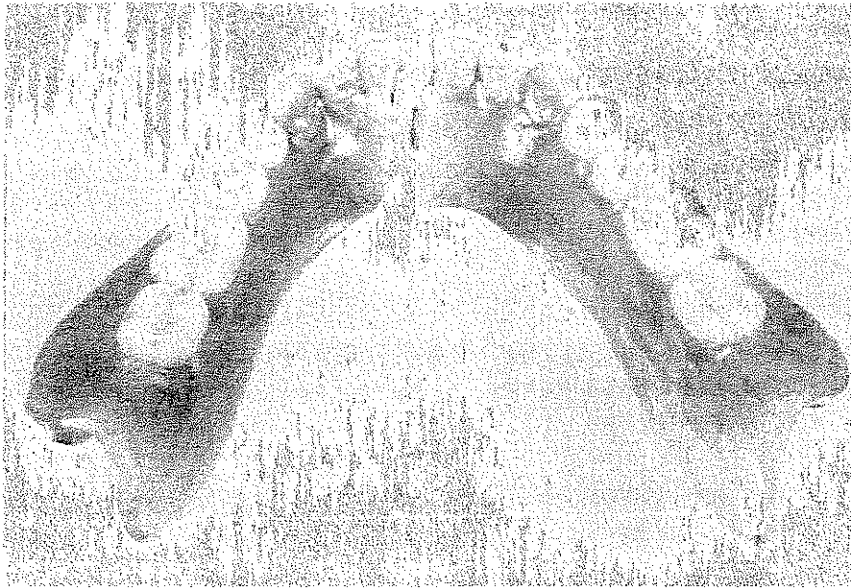STEPS IN REPAIRING THE BROKEN MANDIBULAR COMPLETE DENTURE

Figure 7:1. The Finished Mandibular Denture is Fractured. It Will be Repaired as an Exercise in this Procedure. Exercise Great Care in Breaking the Denture so as not to Cut Your Hands. Seek the Assistance of an Instructor if Needed.

1. Place the finished mandibular denture (from Procedure 16) in a paper towel and break the denture by squeezing it. The paper towel will protect your hands from being cut (Figure 7:1).
2. Realign the broken pieces of the denture together as accurately as possible.
3. Hold the denture together by applying sticky wax along the fracture lines on both the lingual and the labial surfaces (Figure 7:2).
4. Cut a tongue blade in two pieces to make two wooden splints. Attach the splints across the occlusal surfaces of the denture using sticky wax (Figure 7:2). The splints help to hold the broken pieces of the mandibular denture in a fixed position.

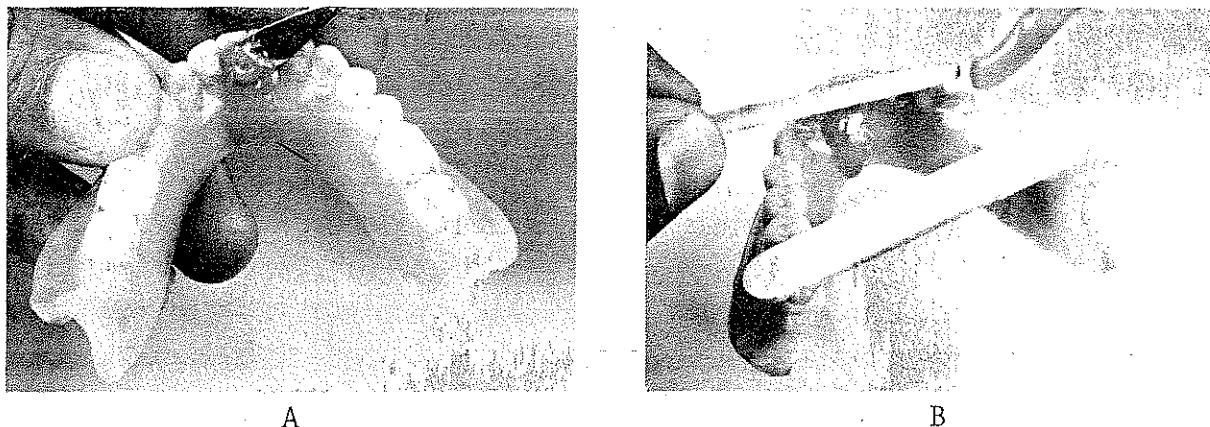


Figure 7:2. A) The Parts of the Denture are Repositioned and Fixed with Sticky Wax. B) The Wooden Splints Help Reinforce the Denture Parts in a Fixed Position.

5. Mix a small amount of impression plaster and vibrate it into the residual ridge area of the fracture site. Place the remaining impression plaster on a glass slab and carefully settle the denture into the plaster (Figure 7:3).
6. After the impression plaster has set (approximately 10 minutes) remove the splints and the sticky wax from the occlusal surfaces and the fracture site of the denture (Figure 7:3).

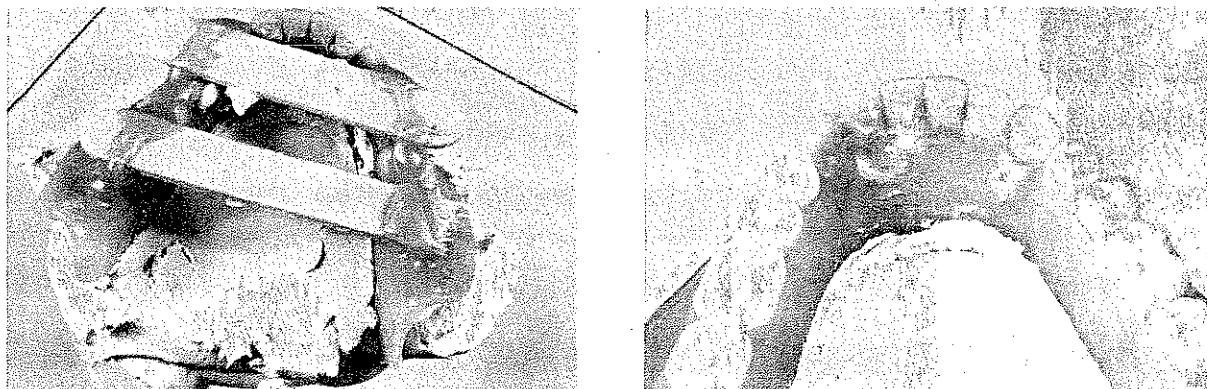


Figure 7:3. The Impression Plaster Model is Poured and After the Plaster Sets the Denture is Cleansed of Wax and Debris.

7. With your laboratory knife, carefully tease the sections of the broken denture from the impression plaster cast. Should the cast fracture in the area of the fracture site, the pouring of the cast must be repeated.
8. Trim the impression plaster cast with the model trimmer and laboratory knife. The denture pieces must be easily reassembled on the cast (Figure 7:4).

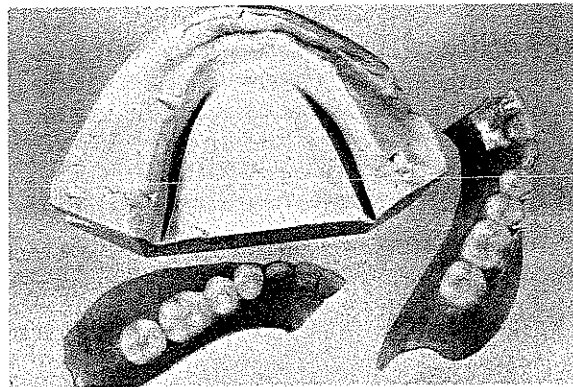
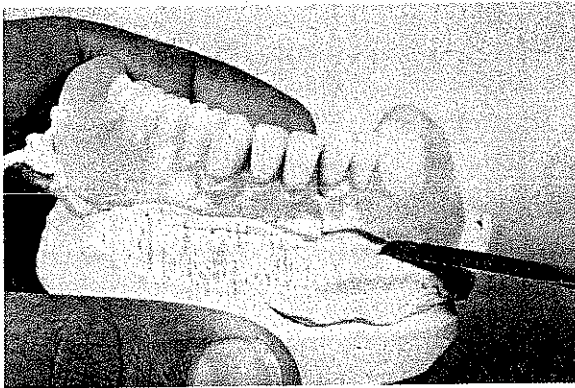


Figure 7:4. The Denture Pieces are Removed from the Impression Plaster Cast and the Cast is Trimmed Appropriately to Permit Ease in Reassembling.

9. With an acrylic bur, remove the acrylic resin along the fracture line both labially and lingually until you have a space of 1-2 mms.
10. Paint the liquid foil substitute over the entire surface of the impression plaster cast.
11. Cleanse the denture sections of all grinding and debris, dry and reposition them on the impression plaster cast (Figure 7:5).
12. With a small brush, wet the prepared margins of the mandibular denture with some of the liquid monomer. Then dip the wet brush into the powder (polymer) and paint some of the acrylic resin into the fracture site (Figure 7:6).

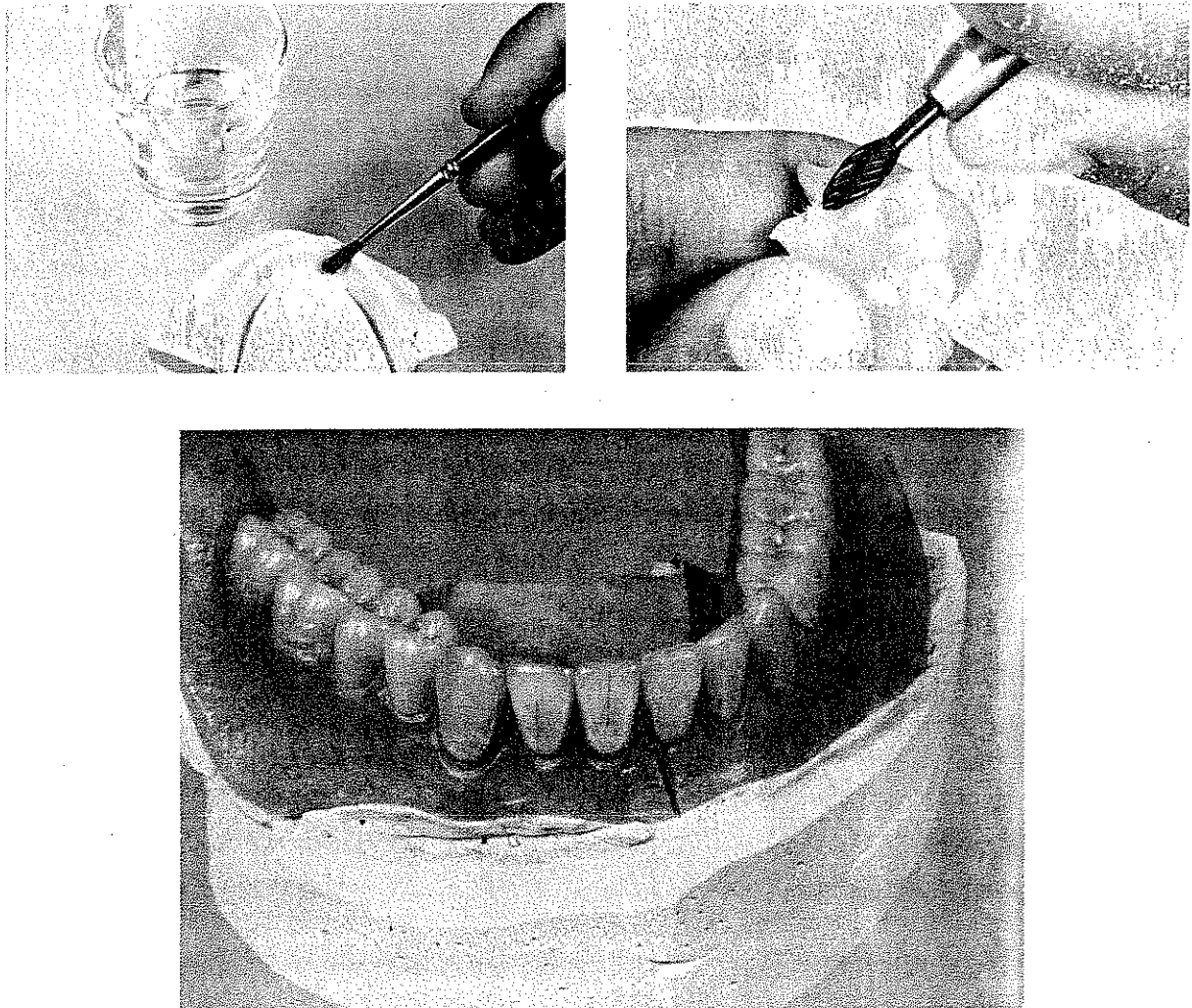


Figure 7:5. The Denture Sections are Prepared for Repair by Carefully Removing Some Acrylic Resin Along the Fracture Line. The Cast is Painted with the Liquid Foil Substitute and the Parts Reassembled.

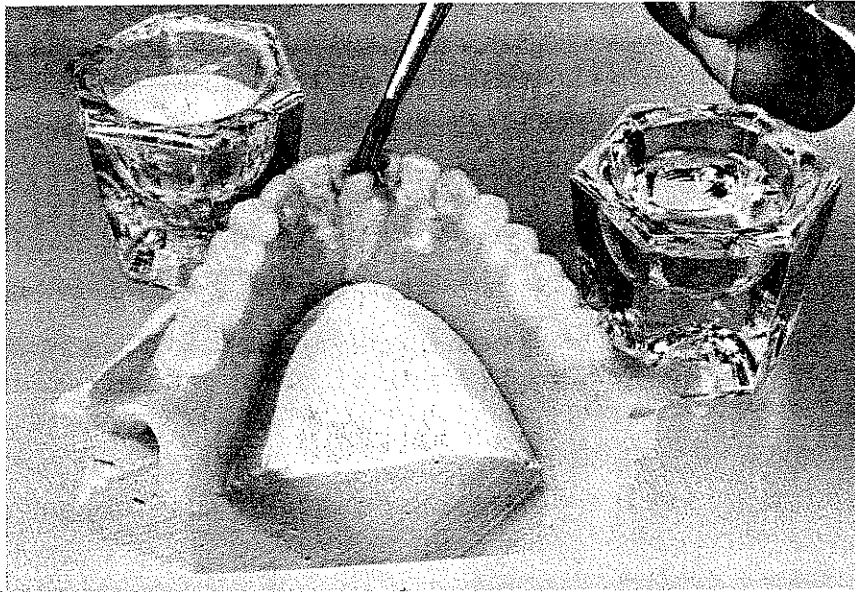
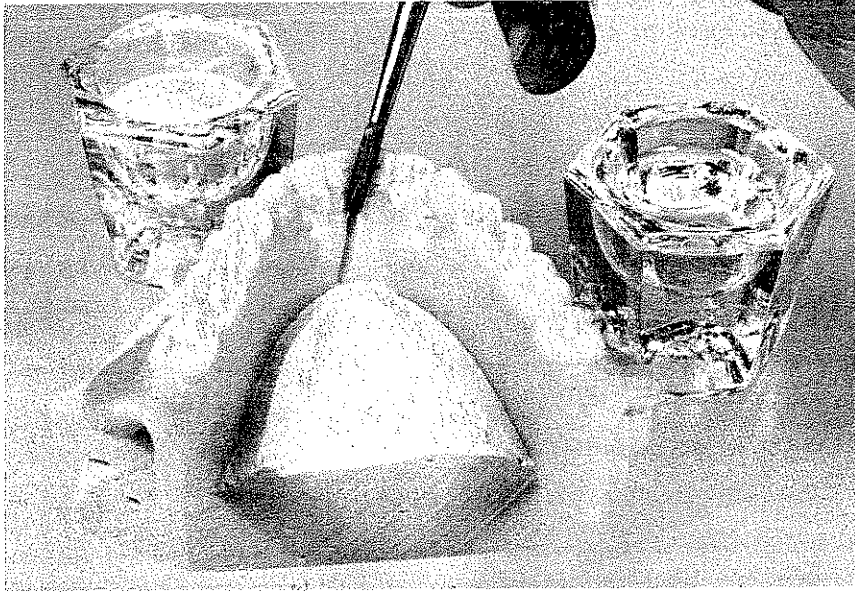


Figure 7:6. Apply the Acrylic Resin to the Fracture Site.

13. Repeat this procedure several times building up the acrylic resin until the fracture line is slightly overfilled. Do this on both the lingual and labial sides of the fracture (Figure 7:6).

14. When the fracture site is slightly overfilled with the repair acrylic resin, apply a thin layer of vaseline over the chemically-activated acrylic resin. Set the cast and denture aside for approximately five minutes, or until it reaches the doughy stage.
15. After the acrylic resin reaches the doughy stage, place the denture and the impression plaster cast in a rubber bowl with lukewarm water.
16. After the acrylic resin has hardened (10-15 minutes), remove the denture from the cast with the laboratory knife.
17. The various vulcanite burs can be used to smooth and contour the repaired areas (Figure 7:7).

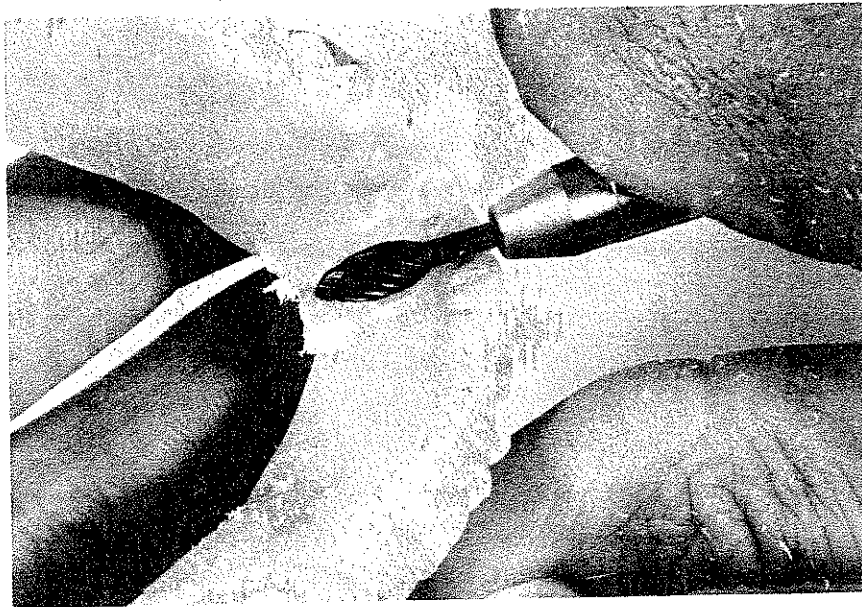


Figure 7:7. The Repaired Denture is Removed from the Impression Plaster Cast and the Vulcanite Bur is Used to Contour the Repaired Areas.

18. The repaired areas are smoothed with the rag wheel and wet pumice. The areas are polished with Bendix (Figure 7:8).
19. Evaluate the repair to determine if it meets the criteria.

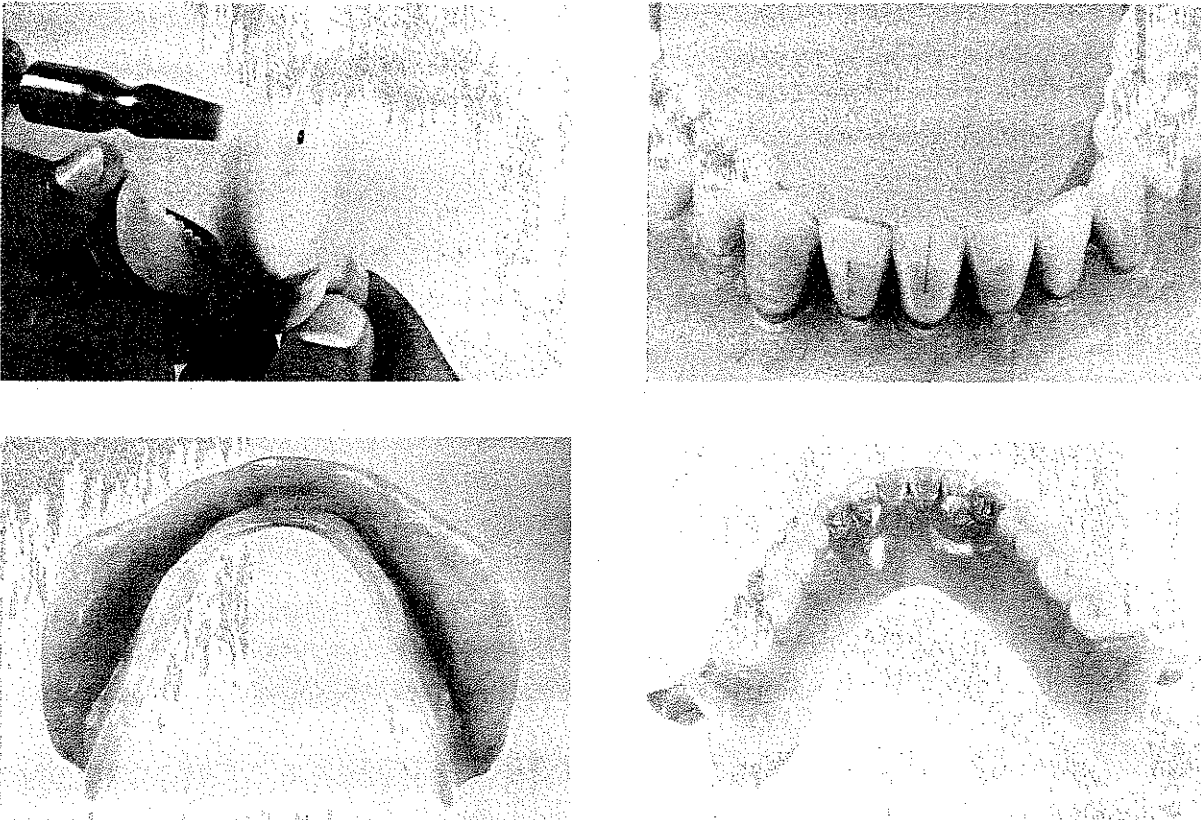


Figure 7:8. The Repaired Areas are Polished.

CRITERIA - REPAIRS

Evaluate your product using the criteria listed and check the appropriate boxes. After filling in the boxes, take your products and this Study Guide to an instructor for evaluation.

<u>Broken Mandibular Denture Repair</u>	<u>Meets Criteria</u>	<u>Does Not meet Criteria</u>	<u>Comments</u>
1. The repaired denture is properly aligned.	<input type="checkbox"/>	<input type="checkbox"/>	
2. The acrylic resin is free of porosity.	<input type="checkbox"/>	<input type="checkbox"/>	
3. The denture base contour across the fracture site is smooth.	<input type="checkbox"/>	<input type="checkbox"/>	
4. There are no sharp edges of acrylic resin on the tissue side.	<input type="checkbox"/>	<input type="checkbox"/>	

STEPS IN REPLACING THE BROKEN MAXILLARY COMPLETE DENTURE TOOTH

1. For this procedure, you will remove the right maxillary central incisor from the complete denture you finished in Procedure #16 and replace it back in the denture base as an exercise in tooth repair and replacement (Figure 7:4).
2. Remove the acrylic resin from the lingual surface supporting the right central incisor with the cross-cut fissure bur (Figure 7:9).

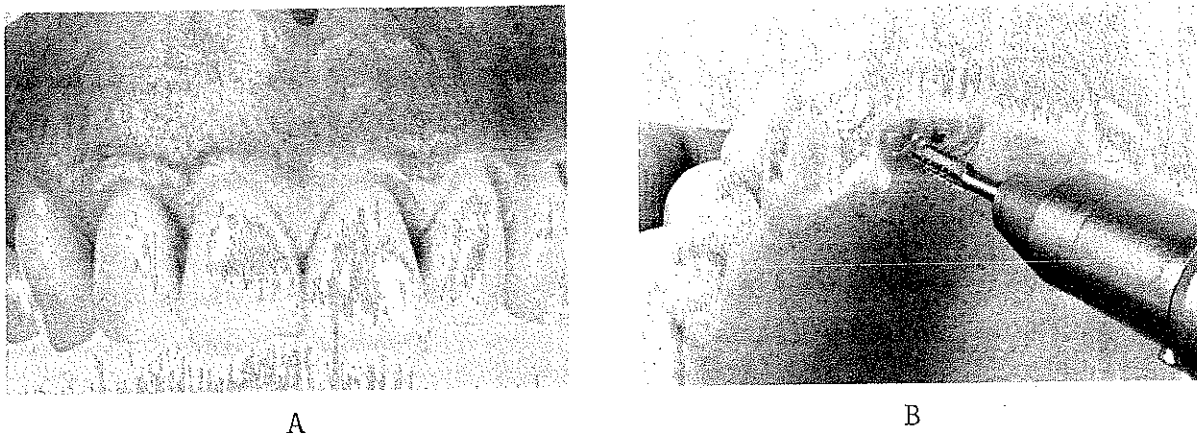


Figure 7:9. A) The Fractured Edge of the Denture Tooth Destroys the Esthetics Provided and Requires Replacement. B) The Acrylic Resin is Removed from the Lingual Surface with the Fissure Bur Exposing the Metal Retention Pins.

3. Expose the metal retention pins, however, do not cut through the acrylic resin into the tissue side of the denture. Also do not remove any of the acrylic resin around the gingival margin on the labial surface of the denture flange and tooth.
4. Gently pry the tooth free from the denture base using the #7 spatula or the blade of the laboratory knife.
5. Do not use excessive force to remove the tooth. If the tooth is reluctant to come loose, heat the porcelain tooth with the alcohol torch. Note: If the tooth is acrylic resin, you cannot heat it with the torch. The heat will burn and soften the acrylic resin tooth and the denture base material. Also, do not apply the flame directly to the acrylic resin base (Figure 7:10).




Figure 7:10. A) After Exposing the Retention Pins, Gently Pry the Tooth Loose from the Denture Base. B) Some Additional Acrylic Resin is Removed to Permit Easy Placement of the New Tooth.

6. Once the tooth is removed, additional acrylic resin should be removed with the vulcanite or fissure bur to permit easy placement of the new tooth.
7. Select and fit a new tooth of the same mold and shade into the denture base. For this technic procedure, you will simply reset the tooth you have just removed (Figure 7:11).

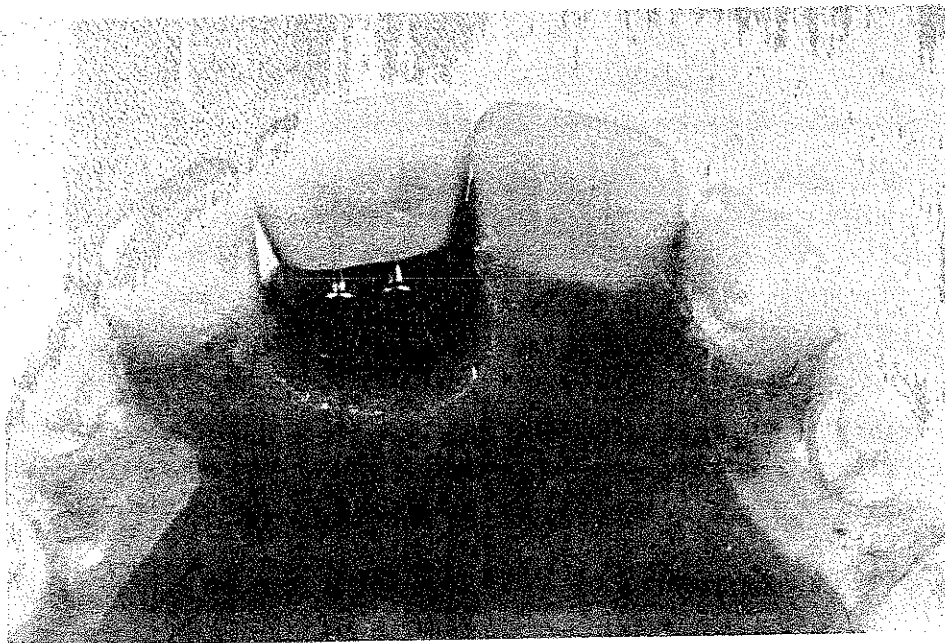


Figure 7:11. The New Tooth is Positioned and Aligned with the Other Central and the Lateral Incisors.

8. Some grinding of the new tooth often times is necessary to properly fit the tooth into the available space. Check the labial to be sure the tooth fits the gingival margin. Carefully align the incisal edges. A small drop of pink baseplate wax can be used to attach the new tooth to the other central incisor and the lateral incisor to hold the tooth in position. If the wax is required, keep it away from any area where the acrylic resin will be added.
9. Wet the lingual surface of the tooth and the adjacent acrylic resin with the liquid monomer. Dip the wet brush into the powder (polymer) and paint some of the acrylic resin into the prepared area.
10. Continue applying the acrylic resin until the area is slightly overfilled (Figure 7:12).

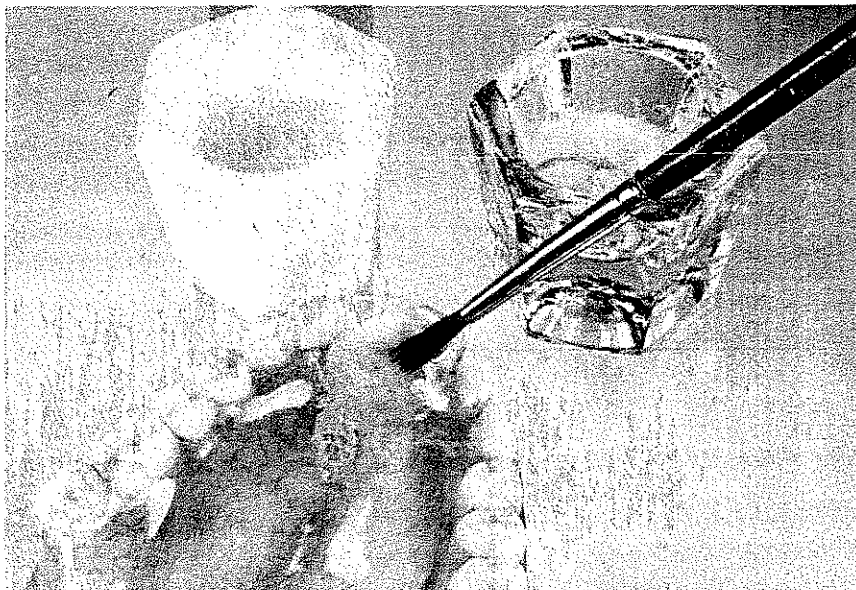


Figure 7:12. The Acrylic Resin is Applied until the Area is Slightly Overfilled.

11. Apply a thin layer of vaseline over the chemically-activated acrylic resin and set it aside until the acrylic resin reaches the doughy stage.
12. Next place the denture in a rubber bowl of lukewarm water for approximately 10-15 minutes.
13. After the acrylic resin hardens, contour the acrylic resin with the vulcanite bur until it blends with the denture base (Figure 7:13).

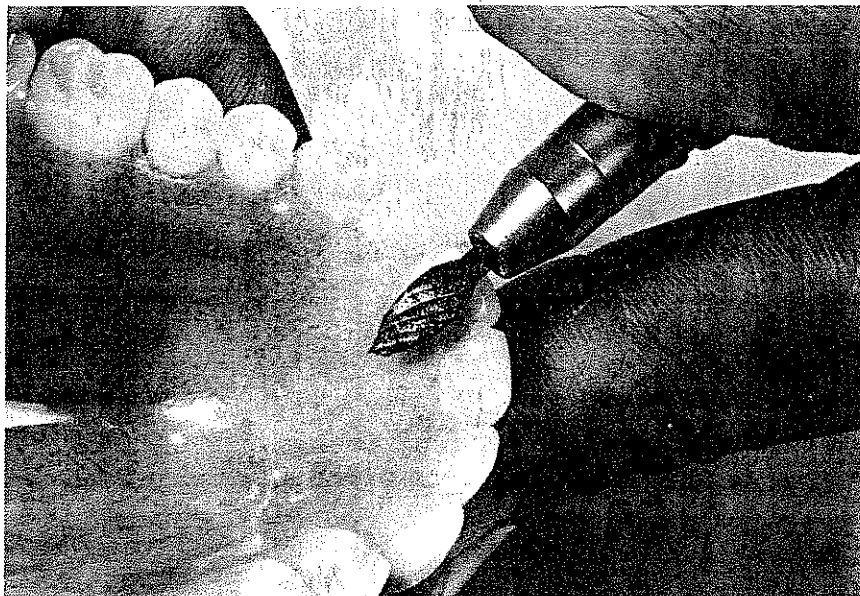


Figure 7:13. Use the Vulcanite Bur to Contour the Acrylic Resin.

14. Smooth the acrylic resin with wet pumice and the rag wheel or felt cone (Figure 7:14).

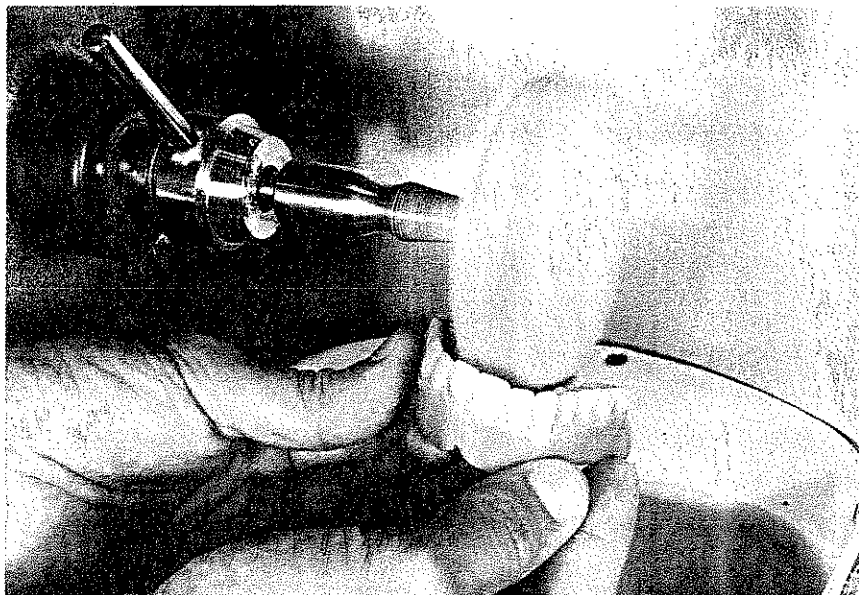


Figure 7:14. Use the Rag Wheel and Wet Pumice to Smooth the Acrylic Resin.

15. Polish the entire denture again with the rag wheel and Bendix.
16. Evaluate the finished tooth replacement using the criteria listed (Figure 7:15).

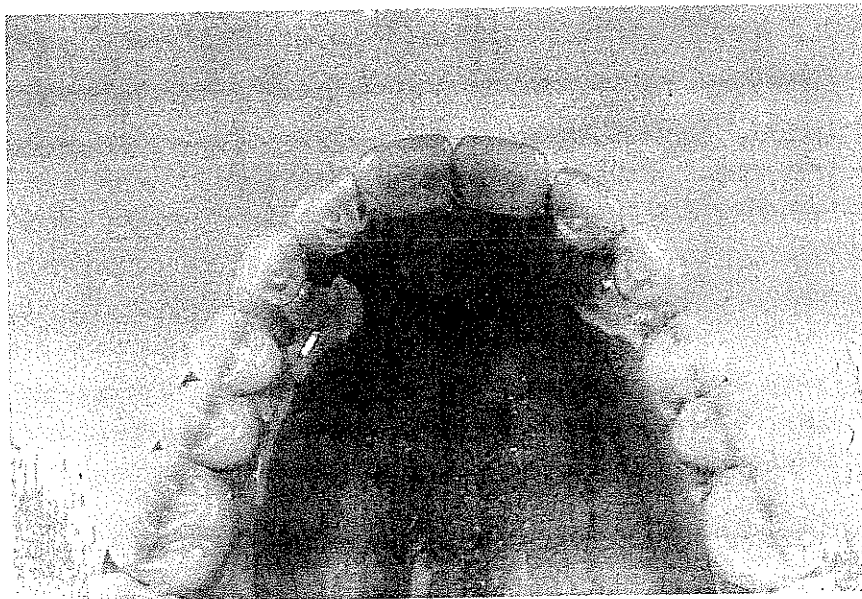
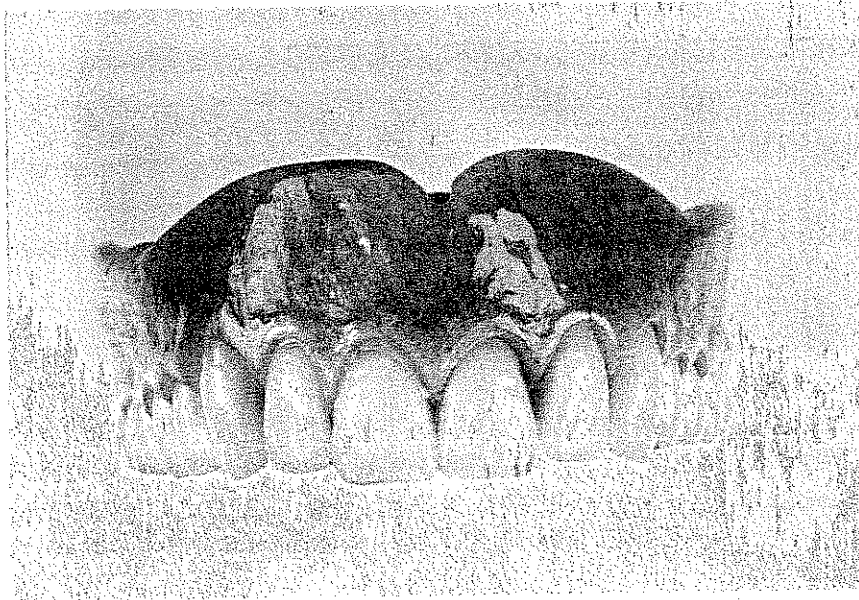


Figure 7:15. The Tooth Replacement Completed.

CRITERIA - REPAIRS

Evaluate your product using the criteria listed and check the appropriate boxes. After filling in the boxes, take your products and this Study Guide to an instructor for evaluation.

<u>Broken Maxillary Tooth Repair</u>	<u>Meets Criteria</u>	<u>Does not meet Criteria</u>	<u>Comments</u>
1. The replaced tooth is properly positioned.	<input type="checkbox"/>	<input type="checkbox"/>	
2. The acrylic repair is free of porosities.	<input type="checkbox"/>	<input type="checkbox"/>	
3. The acrylic resin blends with the denture base and is smooth.	<input type="checkbox"/>	<input type="checkbox"/>	
4. The labial gingival margin is not obliterated with repair acrylic resin additions.	<input type="checkbox"/>	<input type="checkbox"/>	

SELF TEST 7

REPAIRS AND TOOTH REPLACEMENT

(Circle correct response(s) or write brief answers. For correct answers, consult the Answer Key.)

- T F 1. When making an acrylic resin repair to a broken maxillary denture, the repair is made on the tissue side so it cannot be seen.
2. The major flaw(s) in the replaced maxillary central incisor that is illustrated in Figure T7:1 is (are):

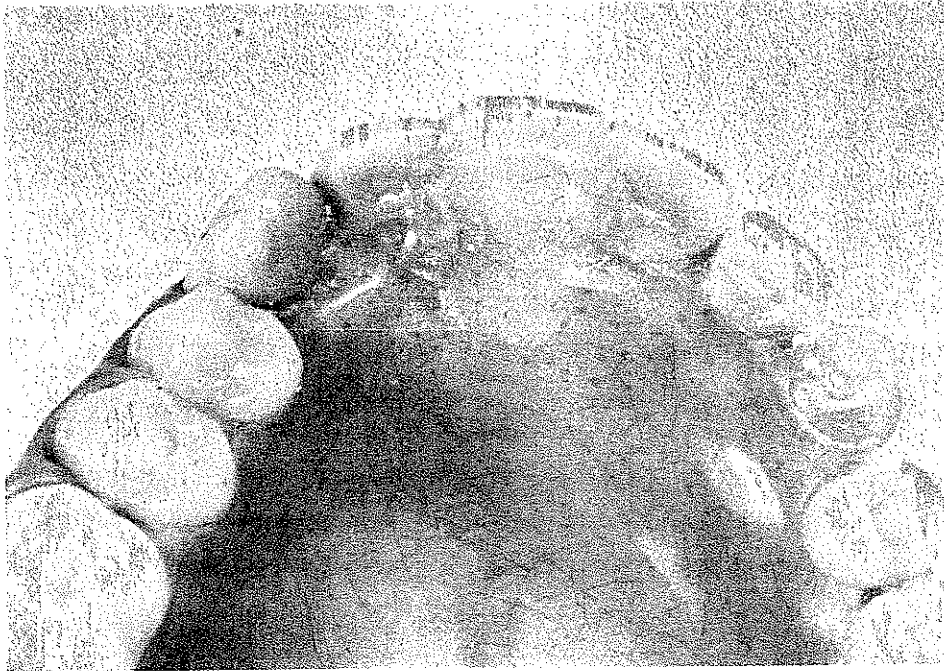


Figure T7:1

- T F 3. When making an acrylic resin repair to a broken mandibular denture the repair material is added in small increments rather than all at once.
4. When placing the acrylic resin repair material in the area to be repaired, the acrylic resin is allowed to reach the _____ stage before placing the denture in _____ water.
5. The major flaw(s) in the replaced maxillary central incisor that is illustrated in Figure T7:2 is (are):
-
-

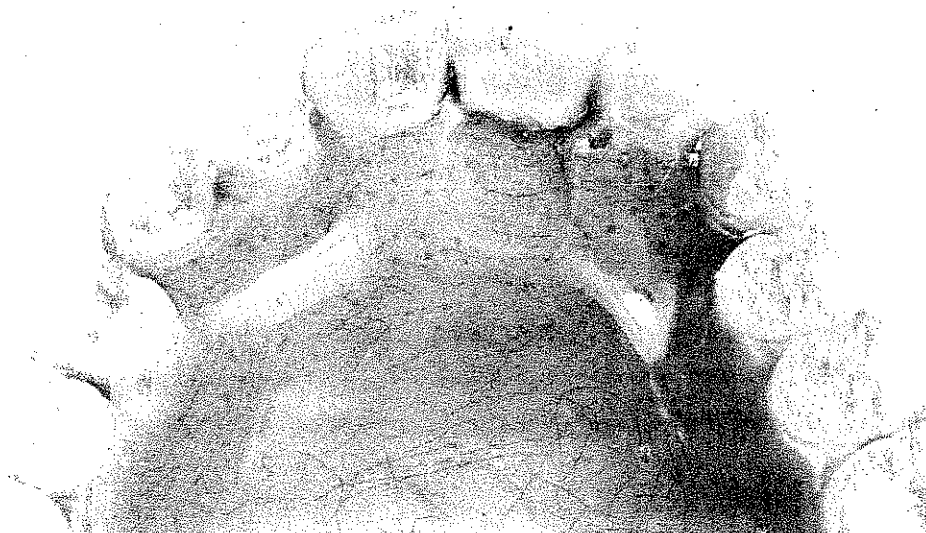

Figure T7:2

- T F 6. When making an acrylic resin repair to a broken mandibular denture, the broken segments should be luted together in the patient's mouth to ensure the correct relationships.
7. A fractured denture may be the sign of greater problems with the appliance. A fractured denture may point to a need for:
1. _____
 2. _____
 3. _____
8. The major flaw(s) in the repair procedure for the fractured mandibular denture that is illustrated in Figure T7:3 is (are):
- _____
- _____

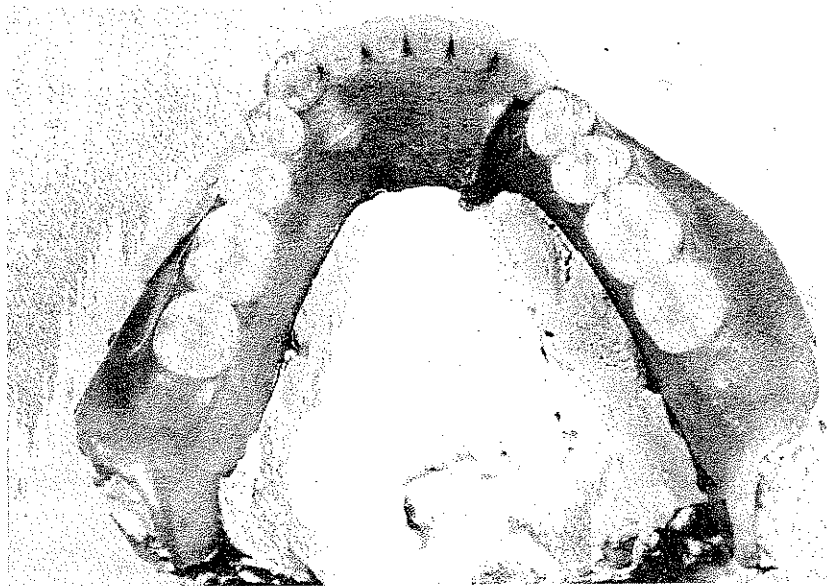


Figure T7:3

- T F 9. The broken mandibular denture flanges should be imbedded in the impression plaster model used to repair the fracture site.
10. The major flaw(s) in the procedure to replace the maxillary central incisor that is illustrated in Figure T7:4 is (are):
-
-

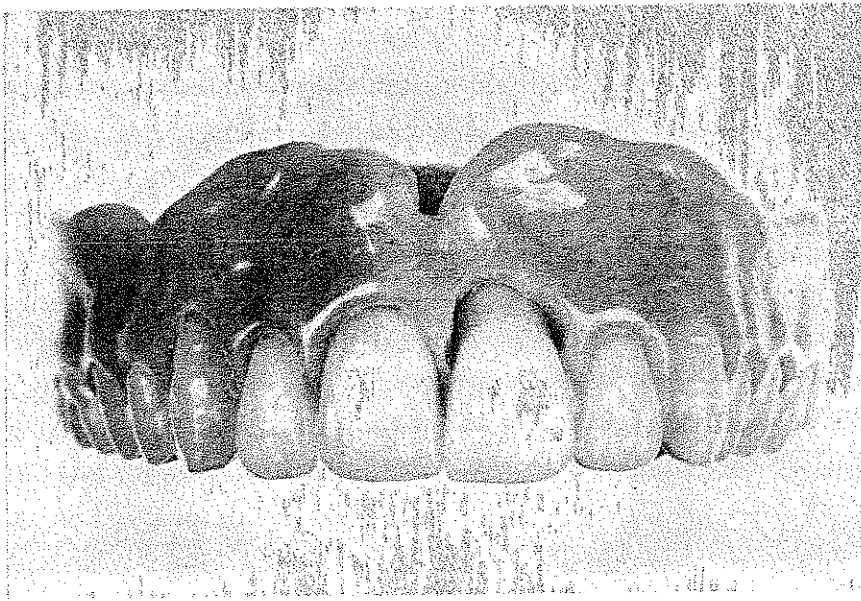


Figure T7:4


COMPUTER-GENERATED SECTION TEST 7

You are now ready to take Computer-Generated Section Test 7, which will cover:

1. Repairing a Broken Denture.
2. Repairing a Denture Tooth.
3. Glossary of Prosthodontic Terms.

When you have completed the laboratory procedures which this Section Test covers and are ready to take this test, go to the Caident Center. All Section Tests are on the computer. The proctor in the Caident Center will instruct you on how to take the test. As you take the test, the computer will inform you of your incorrect answers and tell you the correct answer. As soon as you have completed the test, the computer will display your score. Call the proctor to record your score on the Clinic Progress Card.

There are 14 items in this test. The criterion level (the required correct score is 79%).



ANSWER KEYS

SELF TEST #1

1. b
2. b,d
3. b
4. a
5. a
6. b
7. a,c
8. c,d
9. a,b,c
10. b
11. a,b,c
12. a,b
13. a,c
14. a,b

SELF TEST #2

1. a. Temporary
b. Permanent
2. a,b,d
3. a,b,d
4. d,e
5. 3 mms.
6. a
7. c,d,e
8. e
9. Pink baseplate wax
10. 2. 2 mms.

SELF TEST #3

1. a. Arbitrary face-bow
b. Kinematic face-bow
2. c
3. False
4. True
5. True
6. b,c
7. False
8. The incisal pin was not set flush with the upper member of the articulator.
9. a,b,c,d
10. Too deep; a,c
11. Contact exists between the maxillary stabilized base-plate and the landing area of the mandibular master cast.

SELF-TEST #4

1. False
2. b,d
3. True
4. False
5. b
6. False
7. False
8. b,d
9. b. 2 mms.
10. b
11. Positioned too far to the buccal.
12. The maxillary central incisors are lingually oriented and the necks too prominent.

SELF TEST #5


1. False
2. a,d
3. a
4. False
5. a,b
6. a. sandy
b. sticky
c. doughy
d. stiff
7. a,b
8. False
9. b
10. True

SELF TEST #6

1. a,b
2. b
3. "BULL"
4. False
5. Contacts at A are lingual supporting cusps and buccal working contacts. Contacts at B are lingual supporting cusps and lingual balancing contacts.
6. Contacts at A are centric stops and working contacts. Contacts at B are centric stops and balancing contacts.
7. False
8. False
9. a,b
10. False
11. a,b,c
12. Failure to develop sufficient gingival roll and remove the stone from the interproximal.
13. The dimension of the palate exceeds the recommended thickness.

SELF TEST #7

1. False
2. The repair site is improperly contoured and porous.
3. True
4. Doughy; lukewarm
5. The repair site is not sufficiently filled with acrylic resin.
6. False
7. 1) occlusal adjustment
2) relines or rebase
3) new dentures
8. Fractured denture segments were improperly realigned.
9. False
10. The removal of the labial gingival margin.



The University of Michigan
School of Dentistry

Individualized Instruction Series
In Dental Education